



LJMU Research Online

Wilkinson, CM, Saleem, S, Liu, CYJ and Roughley, M

Revealing the face of Ramesses II through computed tomography, digital 3D facial reconstruction and computer-generated Imagery

<http://researchonline.ljmu.ac.uk/id/eprint/21723/>

Article

Citation (please note it is advisable to refer to the publisher's version if you intend to cite from this work)

Wilkinson, CM, Saleem, S, Liu, CYJ and Roughley, M (2023) Revealing the face of Ramesses II through computed tomography, digital 3D facial reconstruction and computer-generated Imagery. *Journal of Archaeological Science*. 160. ISSN 0305-4403

LJMU has developed [LJMU Research Online](#) for users to access the research output of the University more effectively. Copyright © and Moral Rights for the papers on this site are retained by the individual authors and/or other copyright owners. Users may download and/or print one copy of any article(s) in LJMU Research Online to facilitate their private study or for non-commercial research. You may not engage in further distribution of the material or use it for any profit-making activities or any commercial gain.

The version presented here may differ from the published version or from the version of the record. Please see the repository URL above for details on accessing the published version and note that access may require a subscription.

For more information please contact researchonline@ljmu.ac.uk

<http://researchonline.ljmu.ac.uk/>



Revealing the face of Ramesses II through computed tomography, digital 3D facial reconstruction and computer-generated Imagery

Caroline M. Wilkinson^{a,*}, Sahar N. Saleem^b, Ching Yiu Jessica Liu^a, Mark Roughley^a

^a Face Lab, Liverpool John Moores University, UK

^b Radiology Department, Kasr Al Ainy Faculty of Medicine-Cairo University, Egypt

ARTICLE INFO

Keywords:

Ramesses II
Pharaoh
Facial depiction
Ancient Egypt
Craniofacial
Anthropology

ABSTRACT

King Ramesses II (c. 1279 BCE – 1213 BCE), also known as Ramesses the Great, was the third ruler of the 19th Dynasty of the New Kingdom of ancient Egypt. He lived to around 90 years of age and is considered as one of the most powerful rulers of ancient Egypt. From scientific analysis of the mummified remains of the pharaoh using Computed Tomography (CT) scan data and scrutiny of available historical records, 3D facial depictions of the Pharaoh at two different ages were produced: one at 90 years old (age of death) and one at age 45 years when he was at the peak of his military activities. This article discusses the methods and decisions involved in the creation of these facial depictions.

1. Introduction

Mummies are the preserved bodies of people who died thousands of years ago. Ancient Egyptians were eager to preserve the remains of their deceased, as they believed in resurrection into other life after death. The royal mummies of the New Kingdom's kings and queens, which span the wealthiest period in ancient Egypt (1550–1069 BCE), are among the most accurately preserved ancient human remains still in existence.

The faces of mummified ancient Egyptians have always been a subject of interest, and the faces of Pharaohs have a special hold on the imagination of the observer. Winifred Brunton, an artist from the University of Manchester, was the first person to consider the living appearance of the kings and queens of Egypt through portraiture in the 1920s (Day, 2013). Brunton produced a series of royal portraits in two volumes, *Kings and Queens of Ancient Egypt* (1926) and *Great Ones of Ancient Egypt* (1929), each accompanied by commentaries by leading Egyptologists of the era. Fig. 1 is an example portrait of Queen Ty from the first volume.

The modern manifestation of mummy studies as a scientific endeavour, began in the 1970s and stemmed from a biomedical interest in soft tissue pathology (Nystrom, 2019). The first recorded facial depictions of ancient Egyptian mummies were for the Two Brothers housed in Manchester Museum in the UK; Khnum-Nakht and Nakht-Ankh were unwrapped in 1908 by the Manchester Mummy Team lead by Dr Margaret Murray and then further studied in the 1973 by an academic team

lead by Professor Rosalie David. The 1970s analysis included the production of a 2D sketch and 3D clay facial depiction of the brothers by medical artist, Richard Neave from the University of Manchester (Neave, 1979).

There followed other notable facial depictions of mummified ancient Egyptian Pharaohs by numerous practitioners, including of Tutankhamun (Cascone, 2014; Wilson, 2016), Nefertiti (Evison et al., 2016; Egypt Independent, 2018) and Akhenaten (Davis-Marks, 2021), as well as many facial depictions of non-royal ancient Egyptians from mummified remains (Wilkinson, 2008; Friedman et al., 2012; Lindsay et al., 2015; Loynes et al., 2017; Habicht et al., 2018; Smith et al., 2020; Lee and Shin, 2020). Some of these depictions have been controversial, receiving criticism for demonstrating pale skin (Balaji, 2018), having scientific distortion (Antiquity Now, 2014) and following Western ideals of beauty and femininity (Balaji, 2018). It is worth noting that all these facial depictions were produced in European, Asian or US labs with little influence from Egyptian researchers. This appears to be a repeated pattern, where the visual appearance of ancient Egyptians is dominated by Western post-colonial theory.

However, there has been a good deal of controversy around the facial depiction of ancient Egyptians, which primarily stems from a lack of definitive evidence and historical record describing their physical characteristics. This has led to differing opinions and sometimes multiple interpretations and depictions of the same individual. For example, there are approximately eight published facial depictions of

* Corresponding author. Liverpool John Moores University, Aquinas Building, Maryland Street, Liverpool, L1 9DE, UK.

E-mail address: c.m.wilkinson@ljmu.ac.uk (C.M. Wilkinson).



Fig. 1. Portrait of Queen Ty by Winifred Brunton in *Kings and Queens of Egypt*. Credit: Wellcome Library, London images@wellcome.ac.uk. Copyrighted work available under Creative Commons Attribution only licence CC BY 4.0 <http://creativecommons.org/licenses/by/4.0/>.

Tutankhamun produced by a range of practitioners using different materials and methods, including three depictions produced simultaneously by teams from Egypt, USA and France (Hawass, 2005a), a BBC documentary version depicting pathological conditions (*Tutankhamun: The Truth Uncovered*, 2014), a 3D clay model based on the CT scan by a team from Egypt and Canada featured in PBS documentary (*Allies and Enemies*, 2022), and a recent digital 3D facial depiction (Morales et al., 2023). The differences between these facial depictions may be a result of variation in methodology, clinical imaging, diagnostic interpretation and potential confirmation bias (Wilkinson, 2020). The three facial depictions of Tutankhamun in 2005 were described by an Egyptian scholar (Hawass, 2005a) as showing differences related to the nationality of the reconstruction teams (French and American models had a receding chin and prominent upper lip, while Egyptian model had a more prominent nose and a stronger jaw and chin). Although a facial depiction may be rooted in an established body of scientific knowledge, subjective material may be added when the facts prove insufficient, and subjective opinion cannot escape assumption. Through their wide use in museums, the media and popular literature, facial depictions can affect the course of scientific research by, often unintentionally, contributing to and perpetuating confirmation bias (Wilkinson, 2020). Researchers (Schramm, 2020) suggest that though practitioners “argue that they will adequately care for human remains and their narratives, they also claim a right to knowledge and ownership that pays little attention to the complex entanglement of power and history in colonial, as well as contemporary, science”. Advocates of facial reconstruction/depiction promote utilisation around the power of the face for recognition and affective identification, whilst promoting community narratives and social responsibility (Schramm, 2020). However, in order to do this effectively, the cultural context of the human remains must be considered through the inclusion of cultural representatives in the research team. In addition, where researchers work alongside media production teams, the timing and agenda to provide audience entertainment may influence the way ancient faces are presented (Wilkinson, 2020). Working with the media often does not allow for peer review in advance of broadcast, suggesting scientific rigour may not be the highest priority.

Historical records and descriptions of ancient Egyptians were often

written by foreigners (such as Classical Romans or Greeks) based on biased perspectives, making it challenging to determine their accuracy. Furthermore, modern scholars and researchers may bring their own preconceived notions and biases to their interpretations, which can influence the conclusions they draw about the physical appearance of ancient Egyptians (Wilkinson, 2020). This has resulted in debates and discussions around the appearance of ancient Egyptians (Sedra, 2004). One of the main points of contention revolves around the ancestry of ancient Egyptians. Depictions often rely upon artistic representations found in ancient Egyptian tomb paintings, statues, and reliefs (Snowden, 1970), and these tomb artworks demonstrate that ancient Egyptians were aware of the physical differences between different populations. Typically, ancient Egyptian men are depicted with red-brown complexions whilst women are shown with lighter skin due to their reduced sun exposure (Fig. 2). Pictorial sources assert clear differences between ancient Egyptians and peoples from other lands, included those living in the south (Nubians, Africans), those living in the west (Libyans) and North (south of Mediterranean), and those living in the East (Asiatic). The murals depict the physical traits of ancient Egyptians, such as their skin colour, facial features, hairstyle, clothes, and material culture (weapons, and tools), and appear to differentiate them from their neighbours (Fig. 3). Libyans and Asiatic peoples are depicted with light skin (white and yellow paint) wearing clothes with bright colours, whilst Nubians and Africans are shown with curly hair, and depicted with dark skin (black paint). By contrast, ancient Egyptians were pictured with brown complexions (reddish-brown paint), and these characteristics were also depicted in the many statues and reliefs (Eaverly, 2013). Studies indicate variability in ancient Egyptian facial features, skin tone and hairstyle, suggesting a cosmopolitan population (Batrawi, 1946; Brace et al., 1993).

Genetic studies of ancient Egyptian mummies are rare, due to methodological and contamination issues, and scientists have raised doubts as to whether genetic data from mummies, especially nuclear DNA, which encodes for the majority of the genome, would be reliable, and whether it could be recovered at all. However, recent preliminary DNA analysis provided some insights; a 2017 study (Schuenemann et al., 2017) of 166 macerated samples from 155 mummified individuals at Abusir el-Meleq spanning 1300 years of ancient Egyptian history from the New Kingdom to the Roman Period, revealed that ancient Egyptians shared more ancestry with the Near East (Levant region) than present-day Egyptians ($n = 100$), who received additional limited (8%) sub-Saharan admixture in more recent times (within the last 1500 years). Despite this later limited sub-Saharan influx, the study cannot rule out genetic continuity between ancient and present Egyptians, but it does not support continuity between ancient Egyptians and contemporary Ethiopians.

A further study (Urban et al., 2021) analysing mitochondrial genomes from 17 mummies and 14 skeletal remains from six excavation sites along the Nile valley spanning 4000 years of Egyptian history, found a similar result. A genomic study of Tutankhamun’s 18th Dynasty family members (Gad, 2020) analysed mitochondrial and Y-chromosomal haplogroups and found a genetic profile that originated in the Near East (K) and Europe (R1b) respectively. The profiles for Tutankhamun and Amenhotep III were incomplete.

Recently, researchers at Parabon NanoLabs, a DNA technology company in the USA, used the genetic data from the Abusir el-Meleq site to create 3D face models of three male ancient Egyptians through a process called forensic DNA phenotyping, which uses genetic analysis to predict the shape of facial features and other aspects of a person’s physical appearance (Weisberger, 2021). Scientists used a phenotyping method called Snapshot to predict ancestry, skin colour and facial features, finding that the three men had light brown skin with dark eyes and hair. The team then searched the company’s database for people whose DNA closely aligned with the ancient Egyptians and used these individuals as templates. Other characteristics were determined through examination of the physical remains, such as the width, height and



Fig. 2. Statues of Prince Rahotep and wife Nofret (2575-2551 BCE) found in Meidum and housed at the Cairo Egyptian Museum Image courtesy of Sahar Saleem.



Fig. 3. Scene from the Kheruf TT192 18th Dynasty tomb in Assasif-Luxor.

depth of the heads and facial features. Finally, a forensic artist combined all these results to produce the three facial depictions.

Yet, there is scepticism about the capabilities of DNA-to-face phenotyping (Curtis and Hereward, 2018); it is difficult to assess many such systems as the computer code is not transparent, and the methodology has not been published with peer-review scrutiny. The databases utilised for phenotype prediction may be relatively small, and these methods have been criticized because the way that DNA codes physical features might be different in people from different populations. Most scientists believe that it is too early for DNA technologies to be fully employed in face prediction and a persistent European bias has been reported (Popejoy and Fullerton, 2016) in tDNA databases. One recent study (Alshehhi et al., 2023) analysed population backgrounds in tDNA-to-face research and established that European ancestry was the most common population (80%), with only 2% from an African population and 1% with mixed ancestry, leading to a better ability to predict European faces than other groups. In addition, the accuracy of phenotype predictions (eye, hair, and skin) differs across populations (Alshehhi et al., 2023) and novel populations (such as ancient Egyptians) introduce multiple variables, leading to incomplete or inaccurate phenotype profiles. DNA phenotyping, so the proponents of these technologies argue, is aimed at the identity of the individual. However, in practice it is a clustering technology, and current research focuses on phenotype class without the ability to individualize one face from another (Hopman, 2020). Indeed, M'charek (2020) states that this novel

technology does not so much produce the face of an individual candidate but that of a candidate population. Many researchers agree that although genetics and genomic research claim to be colourblind or post-racial, such research is contributing to the “reinscription of race at the molecular level” (Duster 2006, 428; Abu El-Haj 2007; Fullwiley 2007; Skinner 2006). In this way, DNA phenotyping becomes entwined with specific sociocultural practices of ‘doing race’ (Fullwiley 2011). Schramm (2020) further states that “the relationship between race and face delineates a troubled terrain where multiple material and interpretative registers come together, producing a thick web of historical, political, and onto-epistemological relations”. M'charek (2020) concludes by wondering whether it would be possible to present the face in ways that do not necessarily enact race.

1.1. History of facial depiction of Ramesses II

The Egyptian Pharaoh, Ramesses II (c. 1279 BCE – 1213 BCE), commonly known as Ramesses the Great, is often regarded as the greatest and most celebrated Pharaoh of the New Kingdom. He lived to be approximately 90 years of age and he was buried in a tomb (KV7) in the Valley of the Kings and then later moved to the Deir el Bahari Royal Cache. His mummified remains were discovered by archaeologists in 1881 and identification was established by the fact that the mummy was entirely wrapped in linen bandages bearing the King's name. The mummified body of Ramesses II is like a time capsule that preserved his

facial features and hair, that allows us to study his finer facial characteristics in depth.

There have been a number of published facial depictions of Ramesses II; in 2004 a digital reconstruction of the face of Ramesses II was created, as part of a Discovery Channel documentary into the tomb (KV5) of the sons of Ramesses II (*Ramesses; Wrath of God or Man?*, 2004). The 2004 digital 3D facial depiction was based primarily on his mummified soft tissues, as there were only two cephalogram views of the mummy available (postero-anterior and lateral). A 3D digital model of the mummified head of Ramesses II was constructed using aligned cephalograms and photographs (Fig. 4), and living soft tissues were then estimated using anatomic standards (Wilkinson, 2004).

The Discovery Channel further depicted this 3D facial reconstruction by adding skin, hair and eye colours using Computer-Generated Imaging (CGI) techniques (Boyle, 2004). The resulting depiction did not adequately reflect Ramesses II's elderly status and demonstrated a western bias, with white hair, pale brown eyes and pale skin. The researcher tried to counter this with a second 2D depiction of the same 3D reconstruction (Wilkinson, 2008) showing darker skin and dark brown eyes. In 2007, researchers from Japan produced a further 3D computer graphics facial model of Ramesses II from x-rays (Danjou et al., 2007).

In 2022, the authors of this paper produced two new 3D digital facial depictions of the King from Computed Tomography (CT) data: one at 90 years old (age of death) and one at age 45 years when he was at the peak of his military activity. This was the first time that CT scans were utilised to visualise his skull in three dimensions and the facial depictions were commissioned by and published in a French documentary film (Desjars et al., 2022) for a public audience. The motivation behind these depictions was the cultural enhancement of global public understanding, debate and awareness of the achievements of a Pharaoh who ruled Egypt for 66 years. Visualising the face of a great leader from history can create a sense of personal connection and empathy, whilst encouraging academic exchange, tourism and support initiatives for cultural heritage. The CT scan data created an opportunity for comprehensive research without physically disrupting the mummified remains. In 2014, this method was exhibited in detail at the British Museum in order to demonstrate the lives and deaths of eight ancient Egyptians in their collection (British Museum, 2014). The stated goal of this exhibition was

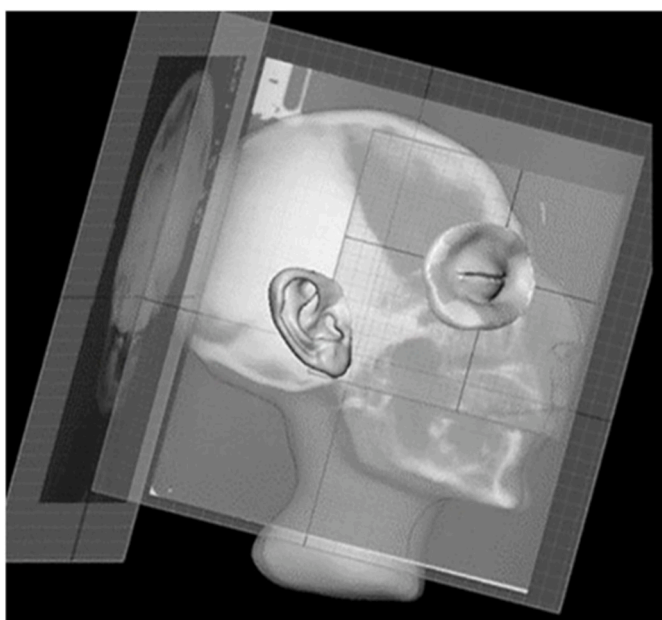


Fig. 4. 3D model of the mummified head of Ramesses II based on 2D cephalograms Image courtesy of Caroline Wilkinson.

to achieve scientific accuracy and approach the mummies in a rigorous, appropriately academic way, whilst at the same time not allowing the science to dominate the narrative (Wagner, 2016). This research was criticised as digital trespassing, demonstrating “the tyrannical tendency in western culture to try to know everything” (Pilger, 2014) using the ‘medical gaze’ (Wagner, 2016). However, the authors did note that these mummies were explored with scientific rigour and respect, so that “instead of revulsion, we are encouraged to feel a sense of shared humanity” (Pilger, 2014). In 2016, using CT scans of the royal mummies from the New Kingdom of ancient Egypt, Egyptian researchers published their findings (Hawass & Saleem, 2016), giving insight on the lifestyles, diseases, and causes of death.

Therefore, these current facial depictions of Ramesses II followed the Egyptian scientific precedent of imaging royal mummies and aimed to humanise and understand individual identity. In addition, the leadership of an Egyptian investigator ensured the cultural mission of this research to enhance the historical understanding of this warrior-king. The methods and decisions involved in the creation of these facial depictions are discussed in the following sections.

2. Method

The use of advanced Computed Tomography (CT) provides the basis for a safe, physically non-invasive and comprehensive study of the mummified remains. As part of the Egyptian Mummy Project, the mummified body of Ramesses II was scanned using a modified CT protocol suitable for ancient, desiccated bodies. CT parameters were used that provided the isotropic voxels required for an accurate, artifact-free 3D reconstruction of the head of the Ramesses II (kV 120, effective mAs 23–63, helical pitch 41 (pitch factor 0.8), with rotation time 0.5 s, slice thickness 0.625 mm and field of view (FOV) 320 mm, and the CT images were reconstructed using different convolution kernels. For the head of Ramesses II's mummy, axial images were produced followed by two- and three-dimensional CT in MIP (Maximum Intensity Projection), MPR (Multi-Planar Reconstruction), SSD (Surface Shaded Display), and VRT (Volume Rendering Technique). The 3D face and skull models produced from the CT data were used to create the digital 3D facial reconstruction of Ramesses II.

Age estimation from the CT images of Ramesses II's mummified remains matched the archaeological knowledge at around 90 years old. The King's mummified head displayed the bony craniofacial features, soft tissues on the surface, and related embalming material. CT images showed that he had poor dental health with multiple tooth loss and a large abscess cavity at the root of the left second molar. Sagittal CT images showed that an attempt was made to preserve the King's very prominent nose by stuffing several embalming materials within the nasal cavity: a small animal bone (measures 21 mm × 87 mm), small dense seeds (black pepper, 4 mm in diameter) and resin (Fig. 5). The embalmers inserted packs in the mummy's eyes, to give it a more life-like appearance (Hawass & Saleem, 2016).

The preserved soft tissues of the mummy provide useful information for the facial depiction. The morphometric features of the face of Ramesses II were assessed from direct inspection of the mummy housed at The National Museum of Egyptian Civilization in Cairo-Egypt, close up photographic records of the mummy's head, and the archaeological literature. In addition, the skull determines the essential shape of the face, while face muscles and tissue thickness determine the face's contours. Therefore, a facial reconstruction could provide additional information relating to the likely facial appearance of the King.

On inspection of the mummy, Ramesses II shows male-pattern baldness with loss of hair at the top of the head and preserved at the temples. The hair is wavy and measures between 50 and 60 mm in length. The colour of his hair was orange in tone, and this was created by the application of henna dye on the aging white hair follicles. Many Egyptians dyed their hair with henna; a personal habit that mummification preserved. However, this does not suggest that Ramesses II had

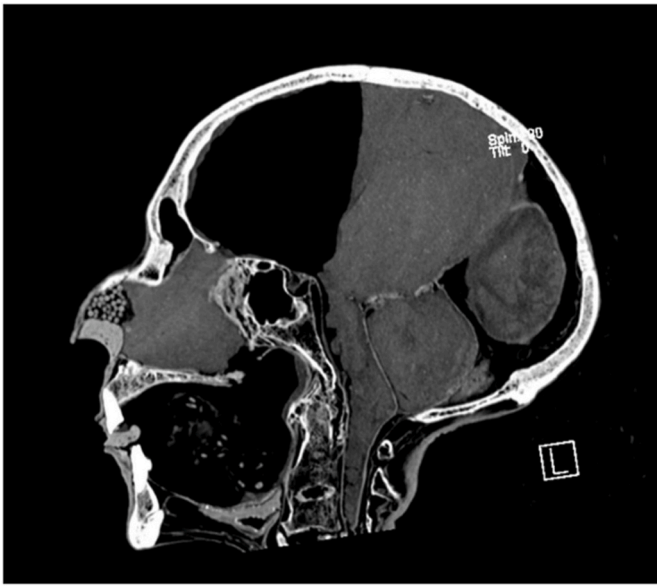


Fig. 5. A sagittal two-dimensional CT image of the head of Ramesses II. Note the prominent nasal bones, with a small animal bone and black pepper seeds placed by the embalmers inside the nasal cavity to preserve the shape of the nose. Image courtesy of Sahar Saleem.

red (ginger) hair when he was younger (Pääbo, 1988), as claimed by some authors (Tyldesley, 2001). This visual inspection matches the microscopic examination of hair from the mummy by Ceccaldi, who determined that the oval shape of the cross section of the hair indicated wavy hair (cymotrichy) and a ‘fair complexion’ (Ceccaldi and Roubet, 1987).

Still, it is important to note that skin colour is a complex and multifactorial trait, which can vary greatly depending on a range of factors, including genetic ancestry, sun exposure, and other environmental factors, and skin colour has a wide range of tones and hues. Whilst there is some evidence (Dutoit et al., 2020) that the use of ‘embalming bitumen’ on the skin caused a dark black skin colour, it has never been established exactly how the embalming materials affected the skin of mummified human remains without destroying the delicate structure. Researchers do not yet have a thorough understanding of the range of original skin tone within an ancient Egyptian population and there is no research on the analysis of the embalming substances applied to the faces of royal mummies from the New Kingdom of ancient Egypt, including Ramesses II. There are some previous studies (Shin et al., 2003; Scott and Dir, 2011; Papageoropoulou et al., 2015) where human remains have been mummified using natron, in order to analyse soft tissue preservation and postmortem alterations, and these studies suggest that skin can be well preserved. Upon close physical examination of the royal mummies, it has been noted that skin tone varies, with some, such as Seti I, Thutmose II and Thutmose III, demonstrating dark brown or black skin, while others exhibit lighter skin tones, including Ramesses II and his son, Merenptah. Future research may shed light on how the embalming substances affected the skin tone of the mummified ancient Egyptians. In summary, the current visual inspection of the well-preserved soft tissues of Ramesses II’s mummified head suggested pierced ear lobes and a honey-brown skin tone.

Both male and female royal mummies from the New Kingdom, including Ramesses II, demonstrate pierced ears. However, pictures or sculptures never show kings wearing earrings, in contrast to queens. Boys from this period are shown wearing earrings, but it appears that once the young prince reached adulthood, earrings were abandoned, perhaps as undignified for a king (Mudry and Pirsig, 2007). Therefore, both new 3D digital facial depictions show Ramesses II without earrings.

Three-dimensional models (OBJs) of the cranium, mandible and soft

tissues were generated from the DICOM data using the open-source medical imaging viewing software InVesalius© (<https://www.cti.gov.br/invesalius>) and these models were imported into 3D modelling software Geomagic Freeform Modelling Plus © (<https://uk.3dsystems.com/software/geomagic-freeform>), operated by a 3Dsystems Touch X© haptic interface device (<https://www.3dsystems.com/haptics-devices/touch-x>). This haptic interface mimicks the touch sensations of traditional sculpting (Roughley and Wilkinson, 2019) and the cranio-facial reconstruction system utilises a database of pre-modelled muscles and anatomical structures created for use in forensic and archaeological depiction (Mahoney and Wilkinson, 2012). This system has been evaluated using the skulls of living subjects (Lee et al., 2012; Wilkinson et al., 2006) and at least 67% of the surface of the face showed less than 2 mm of error. The facial reconstruction process followed the Manchester Method (Mahoney and Wilkinson, 2012) utilising anatomical and anthropometrical standards (Rynn et al., 2009; Gerasimov, 1955; Fedosyutkin and Nainys, 1993) for the facial features.

The three-dimensional shape of the skull provided additional information on the relationship between the soft and hard tissues and facilitated a more accurate representation of the King than the previous reconstructions. The three-dimensional nasal bones suggested a large nose with a slightly convex dorsal ridge, laterally visible nostrils and horizontal columella. Whilst attempts were clearly made to conserve his characteristic nose during the embalming process, this appears not to have been entirely successful, as the mummified nose is significantly more convex than his predicted nose in vivo. Since male-pattern balding was observed on the mummified remains of Ramesses II, this was included in the depiction of Ramesses II at 90 years old.

An elderly face is affected by many age-related changes that alter lower face proportions, feature morphology, skin detail and the angle of the head on the shoulders. These age-related changes can obscure some details of facial identity, and many elderly men can appear similar to each other. Therefore, a decision was made to depict the king around the age of 45 years, based on this new 3D digital face model, in order to visualise his distinct facial identity. Most facial growth and development is complete by the end of the third decade of life and this age reflects the period of life before age-related changes become noticeable. Geomagic Freeform Modelling Plus © and 3Dsystems Touch X© haptic interface device were further utilised to remodel some of his features to take into account the reduction of age-related changes. Age-related changes occur at the bony facial anatomy, muscles, ligaments, fats and the skin, particularly around the eyelids, nose, ear cartilage and lips in older individuals (Ilankovan, 2014); the cartilaginous ear and nose continue to lengthen, the nose will appear longer with drooping at the nasal tip, and the ears will elongate. Tooth loss can lead to a concave facial profile, with hollow cheeks, a smaller jaw and an increased labiomental fold. General soft tissue changes include a less firm lower jawline, thinner lips, deeper facial folds and creases due to the loss of subcutaneous fat, and increased skin wrinkles (Albert et al., 2007). The younger Ramesses II face model was therefore depicted with a stronger, firmer jawline, shorter nose and ears, fuller cheeks and lips, fewer wrinkles, mild facial folds and creases, and darker, fuller hair (Fig. 6).

The process of the facial depiction of Ramesses II can be found on YouTube <https://youtu.be/pk2tcKBNG8>.

3. Discussion

Ancient Egyptian research has historically been dominated by western colonial academics and this dominance has persisted into contemporary mummy studies. The influence of Egyptian researchers on debates around the appearance of ancient Egyptians has been overlooked and marginalized, until recently when there has been a growing movement for collaborative research involving the leadership of Egyptian investigators (Hawass and Saleem, 2016; Saleem and Hawass, 2021). In addition, there has been a developing interest in promoting national pride and awareness of Egypt’s rich cultural heritage, and




Fig. 6. Facial depictions of Ramesses II (2022) without (top) and with (middle/bottom) the application of colour and texture layers L: Age 90 years. R: Age 45 years. Images courtesy of Face Lab @ Liverpool John Moores University. (For interpretation of the references to colour in this figure legend, the reader is referred to the Web version of this article.)

depictions of Pharaohs can be important tools in this effort.

Showcasing the face of a great warrior who ruled Egypt for 66 years, revives interest in his history, promotes global public interest, debate and awareness of his achievements; the first peace treaty in history was initiated by Ramesses II which can help to foster a sense of connection and pride among Egyptians. In addition, interest in the ancient Egyptian civilization can encourage academic exchange, tourism, promote museum exhibitions around the world, and support initiatives for cultural heritage. Academic research, funding and revenue generation can

support efforts to preserve these important artifacts for future generations.

The methods adopted to present two facial depictions of Ramesses II at different ages hold great potential for application in the depiction of less well-known ancient individuals, and less-commonly, at an earlier stage in their lives. There is proven accuracy in estimating facial appearance based on skeletal remains (Lee et al., 2012), but this is also limiting in the sense that facial depictions of individuals are produced at their age of death. By applying facial approximation and age-regression

techniques to a broader range of individuals, we can contribute to a more comprehensive understanding of the physical characteristics of past populations, with the reconstructed faces of less well-known individuals serving as tangible representations of the diverse people from ancient societies beyond more frequently depicted royalty and influential individuals documented in history, potentially allowing researchers to explore patterns in appearance or population demographics. The facial depiction of a great King, such as Ramesses II, has significant cultural and political meanings and ramifications for Egyptians and for the rest of the world. It provides a concrete connection to the past, promotes awareness and appreciation of ancient Egyptian culture, whilst offering insights into the physical characteristics of ancient Egyptians that challenge the stereotype of uniformity and misconceptions relating to this ancient population. Since facial depiction from human remains provides insights into the physical characteristics of ancient Egyptians, comparison between the face of an ancient leader and the faces of contemporary Egyptians promotes interest and knowledge in relation to ancestry. In addition, the facial depiction of ancient Egyptians has broader implications, including questions about identity, cultural heritage, and representation. It highlights the complexities of reconstructing the physical characteristics of ancient peoples and the challenges of interpreting historical evidence with incomplete information. Ultimately, the debate is ongoing, and the depiction of ancient Egyptians continues to be a subject of scholarly inquiry, interpretation, and discussion.

Typically, Ancient Egyptians used skin tone to distinguish between various populations. The image depicts a group of individuals whose arms are bound behind their backs and who are labelled with the names of their respective regions to signify the lands under Egyptian authority. From right to left, the first man shown with black skin is Nubian (south land Arsy), the second, third and fourth men shown in brown are labelled respectively from west Delta (skhet iAm), Northern land (tAmHw), pD tiw Sw (one of Egypt's nine enemies); Libyan man (tHnw) is shown with fair skin (white-yellow), and the final man with black skin is labelled as Iwn tiw (Nubian holders of arrows). Image courtesy of Sahar Saleem.

Funding source

This work was supported by Tournez S'il Vous Plait Productions in France.

Declaration of competing interest

The work described has not been published previously and is not under consideration for publication elsewhere. The publication is approved by all authors and tacitly or explicitly by the responsible authorities where the work was carried out, and, if accepted, it will not be published elsewhere in the same form, in English or in any other language, including electronically without the written consent of the copyright-holder.

The authors declare no conflicts of interest.

Ethical approval was not needed for this research.

References

- Abu El-Haj, N., 2007. The genetic reinscription of race. *Annu. Rev. Anthropol.* 36, 283–300.
- Albert, A.M., Ricanek, K., Patterson, E., 2007. A review of the literature on the aging adult skull and face: implications for forensic science research and applications. *Forensic Sci. Int.* 172, 1–9.
- Tutankhamun Allies and Enemies, 2022. Directed by Filmmaker and Executive Producer Hossam Aboul-Magd, Soura Films. KPBS.
- Alshehhi, A., Almarzooqi, A., Alhammadi, K., Werghe, N., Tay, G.K., Alsafar, H., 2023. Advancement in human face prediction using DNA. *Genes* 14, 136.
- Antiquity Now, 2014. King Tut controversy: the controversial portrait of a boy king, 11/11/2014. https://antiquitynow.org/2014/11/11/king-tut-controversy-mystery-surrounds-the-boy-king/#_ftnref1.
- Balaji, A., 2018. Bust of Contention: Controversy Erupts as the Younger Lady Is Dubbed Nefertiti—Part I. *Ancient Origins*, 11/02/2018. <https://www.ancient-origins.net/news-history-archaeology/bust-contention-controversy-erupts-younger-lady-dubbed-nefertiti-part-i-021825>.
- Batrabi, A., 1946. The racial history of Egypt and Nubia: Part II; the racial relationships of the ancient and modern populations of Egypt and Nubia. *J. Roy. Anthropol. Inst. G. B. Ireland* 76 (2), 131–156.
- Boyle, A., 2004. A Pharaoh's Firstborn Son Is Resurrected. *NBC News*. 01/12/2004. <https://www.nbcnews.com/id/wbna6614215>.
- Brace, C.L., Tracer, D.P., Yaroch, L.A., Robb, J., Brandt, K., Nelson, A.R., 1993. Clines and clusters versus 'Race': a test in ancient Egypt and the case of a death on the Nile. *Am. J. Phys. Anthropol.* 36 (S17), 1–31.
- British Museum, 2014. Ancient Lives, New Discoveries: Eight Mummies. Eight Stories, London, 22 May 2014 to 12 July 2015.
- Cascone, S., 2014. Autopsy Unmasks King Tut's True Face, and it Isn't Pretty: High-Tech 3D Imagery Reveals a Crippled, Ugly Pharaoh. *ArtNet News*, 22 Oct 2014.
- Ceccaldi, P.F., Roubet, C., 1987. Recherches sur les momies Ramsès II [Research on the Ramses II mummies]. *Bull. Acad. Natl. Med.* 171 (1), 119–127. French. PMID: 3300875.
- Curtis, C., Hereward, J., 2018. DNA facial prediction could make protecting your privacy more difficult. *The Conversation*. May 2, 2018.
- Danjou, M., Masunaga, Y., Tateishi, A., Uchiyama, H., Kasahara, H., Yoshimura, S., Hirata, K., Nagaoka, T., Inakage, M., 2007. Photorealistic facial reconstruction of Ramesses II for virtual sets. In: *ACM SIGGRAPH 2007 Posters (SIGGRAPH '07)*, 115–es. Association for Computing Machinery, New York, NY, USA.
- Davis-Marks, L., 2021. *Is This the Face of King Tut's father, pharaoh akenaten?* Smithsonian magazine. *Smart News*; March 29, 2021.
- Day, J., 2013. Facing the mummy: physiognomy, facial reconstruction and the "delirious biographies" of Egyptian mummies. In: *8th World Congress on Mummy Studies/8 Congresso Mundial de Estudos sobre Múmias: Book of Abstracts/Livro de Resumos. Série Livros*, vol. 51, p. 65.
- Desjars, S., Guarguy-Chartier, B., Rénier, M., Marques, L., Hauville, L., 2022. L'Égypte, une passion française. *Des Racines & Des Ailes*, France 3, 15/10/2022.
- Duster, T., 2006. The molecular reinscription of race: unanticipated issues in biotechnology and forensic science. *Patterns Prejudice* 40 (4/5), 427–441.
- Dutoit, C.E., Binet, L., Fujii, H., Lattuati-Derieux, A., Gourier, D., 2020. Non-destructive analysis of mummification balms in ancient Egypt based on EPR of vanadyl and organic radical markers of bitumen. *Anal. Chem.* 92 (23), 15445–15453.
- Eaverly, M.A., 2013. *Tan Men/Pale Women: Color and Gender in Archaic Greece and Egypt, a Comparative Approach*. University of Michigan Press, Ann Arbor, Michigan, USA.
- Evison, M.P., Iwamura, E.S.M., Guimaraes, M.A., Schofield, D., 2016. Forensic facial reconstruction and its contribution to identification in missing person cases. *Handbook of Missing Persons* 427–441.
- Fedosyutkin, B.A., Nainys, J.V., 1993. The relationship of skull morphology to facial features. In: Iscan, M.Y., Helmer, R.P. (Eds.), *Forensic Analysis of the Skull*. Wiley-Liss Inc., New York, pp. 199–213.
- Friedman, S.N., Nguyen, N., Nelson, A.J., Granton, P.V., MacDonald, D.B., Hibbert, R., Cunningham, I.A., 2012. Computed tomography (CT) bone segmentation of an ancient Egyptian Mummy a comparison of automated and semiautomated threshold and dual-energy techniques. *J. Comput. Assist. Tomogr.* 36 (5), 616–622.
- Fullwiley, D., 2007. The molecularization of race: institutionalizing human difference in pharmacogenetics research. *Sci. Cult.* 16 (1), 1–30.
- Fullwiley, D., 2011. Can DNA 'witness' race? In: Krinsky, S., Sloan, K. (Eds.), *Race and the Genetic Revolution: Science, Myth and Culture*. Columbia University Press, New York, pp. 116–126.
- Gad, Y.Z., 2020. Insights from ancient DNA analysis of Egyptian human mummies: clues to disease and kinship. *Hum. Mol. Genet.* 30 (R1), R24–R28.
- Gerasimov, M.M., 1955. *The Reconstruction of the Face from the Basic Structure of the Skull*. Trans. W. Tshernetzky, Publishers unknown, Russia.
- Habicht, M.E., Eppenberger, P.E., Galassi, F.M., Rühli, F.J., Henneberg, M., 2018. Queen Meresankh III—the oldest case of bilateral silent sinus syndrome (c. 2620/10–2570 BC)? *Anthropologie* 56 (2), 103–114, 1962.
- Hawass, Z., 2005a. Facing Tutankhamun. *ARCE bulletin* 188: 3-5 Hawass, Z. And Saleem, S. 2016. In: *Scanning the Pharaohs: CT Imaging of the New Kingdom Royal Mummies*. American University in Cairo Press, New York, NY.
- Hawass, Z., Saleem, S., 2016. *Scanning the pharaohs: CT imaging of the new kingdom royal mummies*. American University in Cairo Press, New York, NY.
- Hopman, R., 2020. Opening up forensic DNA phenotyping: the logics of accuracy, commonality and valuing. *New Genet. Soc.* 39, 424–440.
- Iankovan, V., 2014. Anatomy of ageing face. *Br. J. Oral Maxillofac. Surg.* 52, 195–202.
- Independent, Egypt, 2018. New 3D reconstruction of Queen Nefertiti stirs controversy. February 11, 2018.
- Lee, W.J., Shin, D.H., 2020. Craniofacial reconstruction in mummy studies. *The Handbook of Mummy Studies: New Frontiers in Scientific and Cultural Perspectives* 1–14.
- Lee, W.J., Wilkinson, C.M., Hwang, H.S., 2012. An accuracy assessment of forensic computerized facial reconstruction employing cone-beam computed tomography from live subjects. *J. Forensic Sci.* 57 (2), 318–327.
- Lindsay, K.E., Rühli, F.J., DeLeon, V.B., 2015. Revealing the face of an ancient egyptian: synthesis of current and traditional approaches to evidence-based facial approximation. *Anat. Rec.* 298 (6), 1144–1161.
- Loynes, R.D., Charlier, P., Froesch, P., Houlton, T.M., Lallo, R., Di Vella, G., Bianucci, R., 2017. Virtopsy shows a high status funerary treatment in an early 18th Dynasty non-royal individual. *Forensic Sci. Med. Pathol.* 13, 302–311.

- Mahoney, G., Wilkinson, C.M., 2012. Computer generated facial depiction. In: Wilkinson, C.M., Rynn, C. (Eds.), *Craniofacial Identification*. Cambridge University Press, Cambridge.
- Moraes, C., Habicht, M., Galassi, F., Varotto, E., Beaini, T., 2023. Pharaoh Tutankhamun: a novel 3D digital facial approximation. *Ital. J. Anat Embryol.* 38 (1–2), 1–14.
- Mudry, A., Pirsig, W., 2007. The ear in the visual arts of ancient Egypt. *The Mediterranean Journal of Otolaryngology* 3, 81–89.
- M'charek, A., 2020. Tentacular faces: race and the return of the phenotype in forensic identification. *American Anthropologist, Special Edition: Face and Race* 122 (2), 369–380.
- Neave, R.A.H., 1979. Reconstruction of the heads of three ancient Egyptian mummies. *J. Audiov. Media Med.* 2 (4), 156–164.
- Nystrom, K.C., 2019. *The Bioarchaeology of Mummies*. Routledge Publishers, NY.
- Pääbo, S., 1988. The mummy of ramses II reconsidered. *Orient. Lit.* 83 (1–6), 195–197.
- Papageoropoulou, C., Shved, N., Wanek, J., Ruhli, F.J., 2015. Modeling ancient Egyptian mummification on fresh human tissue: macroscopic and histological aspects. *Anat. Rec.* 298 (6), 974–987.
- Pilger, Z., 2014. Egyptian mummies: science or sacrilege? *The Independent. Culture*, 19 May 2014. <https://www.independent.co.uk/arts-entertainment/art/features/egyptian-mummies-science-or-sacrilege-9399191.html>.
- Popejoy, A.B., Fullerton, S.M., 2016. Genomics is failing on diversity. *Nature* 538, 161–164.
- Rameses: Wrath of God or Man?, 2004. Directed by Mark Aldridge and Tom Pollock. Atlantic Productions, USA.
- Roughley, M., Wilkinson, C., 2019. The affordances of 3D and 4D digital technologies for computerized facial depiction. In: Rea, P. (Ed.), *Advances in Experimental Medicine and Biology: Biomedical Visualisation*. Springer, p. 2.
- Rynn, C., Wilkinson, C.M., Peters, H., 2009. Prediction of nasal morphology from the skull. *Forensic Sci. Med. Pathol.* 6, 20–34.
- Saleem, S., Hawass, Z., 2021. Unwrapping of the mummy of king Amenhotep I (1525–1504 B.C.) using CT. *Front. Med.* 8, 778498 <https://doi.org/10.3389/fmed.2021.778498>.
- Schramm, K., 2020. Stuck in the Tearoom: facial reconstruction and post-apartheid headache. *Am. Anthropol.* 122 (2), 1–14, 2020.
- Schuenemann, V.J., Peltzer, A., Welte, B., van Pelt, W.P., Molak, M., Wang, C.C., Furtwängler, A., Urban, C., Reiter, E., Nieselt, K., Teßmann, B., Francken, M., Harvati, K., Haak, W., Schiffels, S., Krause, J., 2017. Ancient Egyptian mummy genomes suggest an increase of Sub-Saharan African ancestry in post-Roman periods. *Nat. Commun.* 8, 15694.
- Scott, K., Dir, 2011. *Mummifying Alan: Egypt's Last Secret*. Produced by Blink Films. First aired Channel 4, 24th Oct 2011. <https://www.channel4.com/press/news/mummifying-alan-egypts-last-secret>.
- Sedra, P., 2004. Imagining an imperial race: egyptology in the service of empire. *Comp. Stud. S. Asia Afr. Middle East* 24 (1), 249–259.
- Shin, D.H., Youn, M., Chang, B.S., 2003. Histological analysis on the medieval mummy in Korea. *Forensic Sci. Int.* 137, 172–182.
- Skinner, D., 2006. Racialised futures: biologism and the changing politics of identity. *Soc. Stud. Sci.* 36 (3), 459–488.
- Smith, K., Roughley, M., Harris, S., Wilkinson, C., Palmer, E., 2020. From Ta-Kesh to Ta-Kush: the affordances of digital, haptic visualisation for heritage accessibility. *Digital Applications in Archaeology and Cultural Heritage* 19, e00159.
- Snowden, F., 1970. *Blacks in Antiquity*. The Belknap Press of Harvard University Press, Cambridge, Massachusetts.
- Tutankhamun: the truth uncovered, 2014. Directed by Tom Stubberfield, STV Productions UK. First broadcast BBC1, 26 Oct 2014, 21.00.
- Tyldesley, J., 2001. *Rameses: Egypt's Greatest Pharaoh*. Penguin Books, UK.
- Urban, C., Neukamm, J., Eppenberger, P., Brändle, M., Rühli, F., Schuenemann, V., 2021. Human mitochondrial haplogroups and ancient DNA preservation across Egyptian history. *ISBA9, 9th International Symposium on Biomolecular Archaeology* 126, 2021.
- Wagner, K., 2016. The mummy and the medical gaze: digital visualisations in the British Museum's exhibition 'Ancient lives, new discoveries'. *Museum Management and Curatorship* 32 (2), 160–175.
- Weisberger, M., 2021. 3 Egyptian mummy faces revealed in stunning reconstruction. *Live Science*; September 27, 2021.
- Wilkinson, C.M., 2004. *Forensic Facial Reconstruction*. Cambridge University Press.
- Wilkinson, C.M., 2008. The facial reconstruction of ancient Egyptians. Cpt 11. In: David, R.A. (Ed.), *Egyptian Mummies and Modern Science*. Cambridge University Press, pp. 162–178.
- Wilkinson, C.M., 2020. Cognitive bias and facial depiction from skeletal remains. *Bioarchaeology International* 4 (1), 1.
- Wilkinson, C., Rynn, C., Peters, H., Taister, M., Kau, C.H., Richmond, S., 2006. A blind accuracy assessment of computer-modeled forensic facial reconstruction using computed tomography data from live subjects. *Forensic Sci Med Pathol.* 2 179–187.
- Wilson, J., 2016. King Tut's 'virtual autopsy' reveals surprises. *Inside Africa, CNN*. January 25, 2016.