



LJMU Research Online

Zhang, X, Peng, X, Wang, C, Olatunji, OJ and Famurewa, A

Tiliacora triandra attenuates cisplatin triggered hepatorenal and testicular toxicity in rats by modulating oxidative inflammation, apoptosis and endocrine deficit

<http://researchonline.ljmu.ac.uk/id/eprint/24941/>

Article

Citation (please note it is advisable to refer to the publisher's version if you intend to cite from this work)

Zhang, X, Peng, X, Wang, C, Olatunji, OJ and Famurewa, A (2022) Tiliacora triandra attenuates cisplatin triggered hepatorenal and testicular toxicity in rats by modulating oxidative inflammation, apoptosis and endocrine deficit. Frontiers in Bioscience (Landmark edition). 27 (2). ISSN 2768-6701

LJMU has developed [LJMU Research Online](#) for users to access the research output of the University more effectively. Copyright © and Moral Rights for the papers on this site are retained by the individual authors and/or other copyright owners. Users may download and/or print one copy of any article(s) in LJMU Research Online to facilitate their private study or for non-commercial research. You may not engage in further distribution of the material or use it for any profit-making activities or any commercial gain.

The version presented here may differ from the published version or from the version of the record. Please see the repository URL above for details on accessing the published version and note that access may require a subscription.

For more information please contact researchonline@ljmu.ac.uk

<http://researchonline.ljmu.ac.uk/>

Original Research

Tiliacora triandra attenuates cisplatin triggered hepatorenal and testicular toxicity in rats by modulating oxidative inflammation, apoptosis and endocrine deficit

Xiaomin Zhang¹, Xiaozhuang Peng¹, Chen Wang^{1,*}, Opeyemi Joshua Olatunji^{2,*}, Ademola Famurewa³¹Department of Emergency Intensive Care, Wuhu Second Peoples Hospital, 241001 Wuhu, Anhui, China²Faculty of Thai Traditional Medicine, Prince of Songkla University, 90110 Hat Yai, Thailand³Department of Medical Biochemistry, Faculty of Basic Medical Sciences, Alex Ekwueme Federal University, Ndufu-Alike Ikwo, 23401 Ebonyi State, Nigeria*Correspondence: eywangchen@163.com (Chen Wang); opeyemi.j@psu.ac.th (Opeyemi Joshua Olatunji)

Academic Editor: Marcello Iriti

Submitted: 16 December 2021 Revised: 28 December 2021 Accepted: 30 December 2021 Published: 24 January 2022

Abstract

Purpose: Cisplatin (CIS) is a platinum based anticancer drug that has demonstrated significant efficacy against various types of cancers. Unfortunately, this drug is also famous for its severe side effects on delicate organs. Herein this study examined the hepatorenal and testicular protective effects of TiTE against CIS-induced hepatorenal and testicular insults. **Methods:** Rats were administered with TiTE (250 and 500 mg/kg body weight) for 4 weeks, while a single dose of CIS (2.5 mg/kg body weight) was injected once per week from week 2 to week 4. **Results:** Treatment with TiTE significantly attenuated CIS-induced increases in serum creatinine, blood urea nitrogen (BUN), uric acid, alanine aminotransferase (ALT) and aspartate aminotransferase (AST). Furthermore, TiTE treatment also decreased oxidative stress (MDA) inflammations (TNF- α , IL-1 β , IL-6, NF- κ B) and apoptosis (caspase-3 activity) and restored hepatorenal and testicular antioxidant defense (SOD, CAT and GPx) in CIS treated rats. Additionally, the TiTE improved sperm count, motility and viability, and ameliorated the reduced serum levels of testosterone, follicle stimulating hormone (FSH) and luteinizing hormone (LH) in CIS-injected rats. TiTE also curtailed hepatorenal and testicular histological changes in CIS treated rats. **Conclusion:** The findings from the study indicated that TiTE displayed hepatorenal and testicular protective effects via inhibition of oxidative stress-mediated inflammation and endocrine imbalance in rats.

Keywords: Cisplatin; *Tiliacora triandra*; Hepatorenal toxicity; Testicular toxicity; Oxidative stress; Antioxidant

1. Introduction

Cancer is one of the world's deadliest disease and the global impact of the disease increases on a yearly basis due to several factors including aging, population growth and socioeconomic development [1,2]. The incidence of the disease cuts across all age groups and ethnicity, making it a major health issue [3]. Chemotherapy has significantly increased the life expectancy of cancer patients, especially in cases where the disease is detected early. However, most of the drugs used during chemotherapy have displayed major adverse effects due to the inability of the drugs to discriminate between cancer and normal cells, thus negatively impacting on the quality of life of cancer patients. Cisplatin is a frontline chemotherapeutic drug for treating a wide range of cancers. As a common cytostatic agent, CIS is administered to lungs, breast, testicular, ovarian, head and neck cancer patients [4,5].

The negative effects of CIS on humans have been widely demonstrated in several previous studies. Considering existing literatures, although CIS is successfully used to kill cancer cells, it is a multi-organ toxic agent [4,5]. Cisplatin induces gross nephrotoxicity, ototoxicity, neuro-

toxicity, reproductive and hepatotoxicity [6,7]. CIS also induces the activation of several inflammatory and oxidative stress sensitivity pathways which further aggravates its multi organ toxicity [7,8].

Organ degeneration under cisplatin insult takes place through multiple pathways, mostly linked to oxidative stress, inflammation and apoptosis, DNA damage and mitochondrial dysfunction [5,9]. Experimental studies have shown that CIS can generate highly reactive oxygen species (ROS), which invariably leads to the accumulation of lipid peroxides, impaired respiratory chain in the mitochondria, suppression of antioxidant defence system, leading to oxidative stress [5,10]. Additionally, oxidative stress induced by CIS could instigate the infiltration of inflammatory neutrophils, chemokines and cytokines which in turn aggravates the severity of organ damages [11,12].

At present, there are no effective treatment for mitigating CIS induced toxicity, although several approaches have been proposed including using antioxidants such as vitamin E [13]. Based on the limitations of the available therapy, together with the unavoidable deteriorating effects of CIS therapy, there is an urgent need to find effective



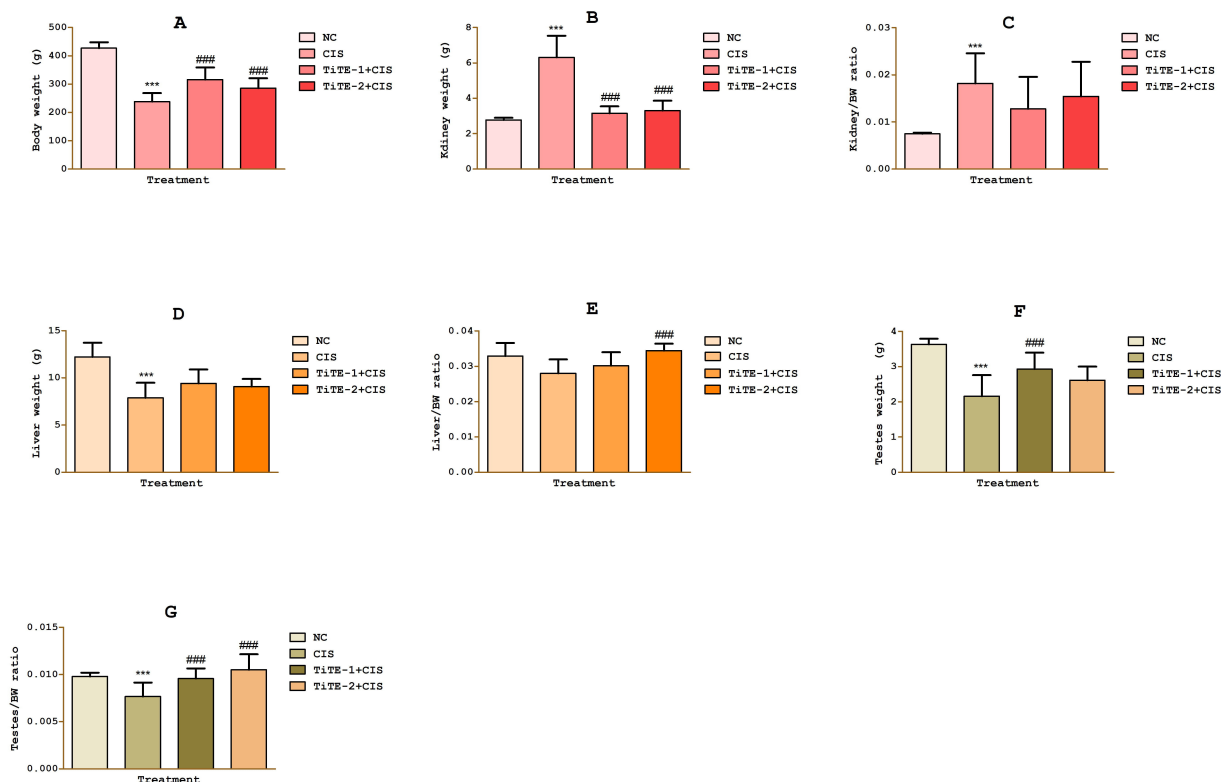


Fig. 1. Effect of TiTE on A, body weight; B, kidney weight; C, kidney/BW ratio; D, liver weight; E, liver/BW ratio; F, testes weight; G, testes/BW ratio in CIS treated rats. *** $p < 0.05$ compared to normal control; ### $p < 0.05$ compared to CIS group.

strategies against CIS-induced toxicity. *Tiliacora triandra* is an ever green medicinal plant of the Menispermaceae family, with several antioxidant compounds reported from the plant. The plant is native to several southeast Asian countries including Thailand, Laos and Vietnam [14–16]. Earlier studies have demonstrated its antioxidant and anti-inflammatory effects [14,17,18]. Studies have shown that *T. triandra* abrogated oxidative stress and inflammation, as well as improve antioxidant activity in the kidney, testes and brain [16,17,19]. Furthermore, our previous studies have illustrated that *T. triandra* alleviated CIS induced neurotoxicity [20,21]. However, the protective effect of *T. triandra* in cisplatin-induced hepatorenal and testicular toxicity is yet to be explored. As such, this study investigated the influence of *T. triandra* on CIS-induced toxicity in the kidney, liver and testes of rats.

2. Materials and methods

2.1 Chemical and drugs

Cisplatin and ELISA kits for IL-6, IL-1 β , TNF- α and caspase-3 were purchased from Abcam (Cambridge, UK). Cisplatin was dissolved in normal saline and preserved in a firmly closed amber bottle. The biochemical assay kits for SOD, MDA, GPx and CAT were procured from Abbkine Inc. (Wuhan, China). All other chemicals and reagents used were of analytical grade.

2.2 Plant collection and extraction

The collection, identification and extraction procedures of *T. triandra* were detailed in our earlier studies [22].

2.3 Animals and experimental groups

Male Wistar rats (specific pathogen free grade) with body weight ranging from 120–140 g used in this study were procured from Qinglongshan Experimental Animal Company (Nanjing, China). The rats were kept in a controlled hygienic laboratory and adapted to the laboratory environment (temperature: 22 ± 2 °C; humidity: $65 \pm 10\%$; photoperiod: 12/12 h light/dark) for 1 week. The rats were randomly allocated into groups in clean stainless steel cages (6 rats per cage) with corn hobs as beddings. During the adaption period, the rats were allowed to freely eat normal rat chow and drink water. All procedures included in this work gained approval from the research ethics committee of the institution (Wuhuey 2021-0832). Additionally, the guidelines of the National Institute of Health for the care and use of laboratory animals was used for the experiment. After the adaption period, the animals were randomised into four groups, with 6 animals in each group as follows:

Group A (normal control group): Rats in this group were orally treated with normal saline for 4 weeks.

Group B (CIS group): The rats in this group were orally treated with normal saline for 4 weeks and were ex-

posed to three intraperitoneal injections of cisplatin (2.5 mg/kg/week) from week 2 to week 4.

Group C (TiTE-1 group): The rats in this group received intragastric administration of TiTE (250 mg/kg) for 4 weeks and intraperitoneally injected with three rounds of cisplatin (2.5 mg/kg/week), starting from the second week of TiTE treatment.

Group D (TiTE-2 group): The rats in this group received intragastric administration of TiTE (500 mg/kg) for 4 weeks and intraperitoneally injected with cisplatin (2.5 mg/kg/week), starting from the second week of TiTE treatment. The doses of cisplatin and TiTE were adopted from previous studies [20,22].

At the end of the experiment, the rats were euthanised with thiopental sodium (150 mg/kg) and blood samples were withdrawn through cardiac puncture and centrifuged to obtain the serum for biochemical analysis relating to hepatorenal and testicular function parameters. Thereafter, the kidney, liver and testes were dissected, washed with ice-cold phosphate buffered saline and weighed. The harvested tissues were homogenized in phosphate buffered saline, centrifuged at 6000 rpm for 20 mins at 4 °C. The supernatant collected was used for the estimation of oxidative stress markers (SOD, GPx, CAT and MDA), inflammatory parameters (TNF- α , IL-6, IL-1 β and NF-kB) and caspase 3 activity.

2.4 Histopathological examination

After rinsing with PBS, a small portion of the harvested liver, kidney and testes tissues were fixed in 10% buffered formalin solution, embedded in paraffin blocks and sectioned at 5 μ m thickness. The slides were then stained with hematoxylin and eosin for routine histopathological examination and observed under light microscope for histopathological alterations.

2.5 Biochemical analysis

The sera obtained after centrifuging as stated above was used for the determination of blood urea nitrogen (BUN), creatinine (SCr), uric acid, alanine aminotransferase (ALT), aspartate aminotransferase (AST), luteinizing hormone (LH), testosterone, follicle stimulating hormone (FSH).

2.6 Sperm parameters evaluation

The epididymal sperm of the rats were immediately obtained after sacrifice by dissecting the epididymis and allowing the sperm to freely flow onto a sterile clean glass. The collected sperms were assayed for sperm count, motility and viability according to previously reported method [21].

2.7 Statistical analysis

The results were reported as means \pm SD ($n = 6$) and data were statistically evaluated using one-way ANOVA followed by Newman–Keuls test. Statistical analysis was done using Graph pad 5.0 (San Diego, California, USA). Differences in values were considered significant at $p < 0.05$.

3. Results

3.1 Effect of TiTE on body weight of CIS treated rats

The effect of TiTE on changes in rats weight after exposure to CIS is shown in Fig. 1A. The body weight of the rats in the normal control group was significantly higher than the corresponding average body weight of the CIS group. Whereas, the rats treated with TiTE showed significantly higher body weight compared to the CIS control rats (Fig. 1A).

3.2 Effect of TiTE on organ weight and coefficient in CIS treated rats

As indicated in Fig. 1B,C, the kidney weight and kidney/BW ratio of the rats in the CIS control group were significantly increased when compared to the normal control group. TiTE significantly reduced the kidney weight compared to CIS group, while the kidney/BW of the TiTE treated rats were decreased albeit not significantly different from the CIS group (Fig. 1B,C). The weight of the liver and the testes of the CIS group were significantly reduced when compared to the corresponding weight of these organs in the normal control rats. Whereas, in the TiTE treated rats there were improvement in the weight of the liver and testes of the treated rats (Fig. 1C,E). Furthermore, the CIS treated group showed significantly reduced testes/BW ratio, while treatment with TiTE significantly increased the testes/BW ratio compared to the CIS group (Fig. 1G).

3.3 Effect of TiTE on serum biochemical parameters in CIS treated rats

As shown in Fig. 2, CIS notably increased the serum levels of BUN, SCr, uric acid, AST and ALT compared to the normal control group, while testosterone, FSH and LH levels were significantly reduced in CIS control group when compared to the normal control group (Fig. 2). Whereas, TiTE treatment significantly suppressed the increased levels of the above markers towards the normal range compared to CIS control group (Fig. 2). In addition, TiTE treated groups displayed increased serum levels of Testosterone, FSH and LH compared to the CIS control group (Fig. 2F–H).

3.4 Effect of TiTE on sperm parameters in CIS treated rats

Regarding sperm functional parameters, the administration of CIS led to significant decreases in sperm count, sperm viability and sperm motility as compared to the corresponding values from the normal control group (Fig. 3A–

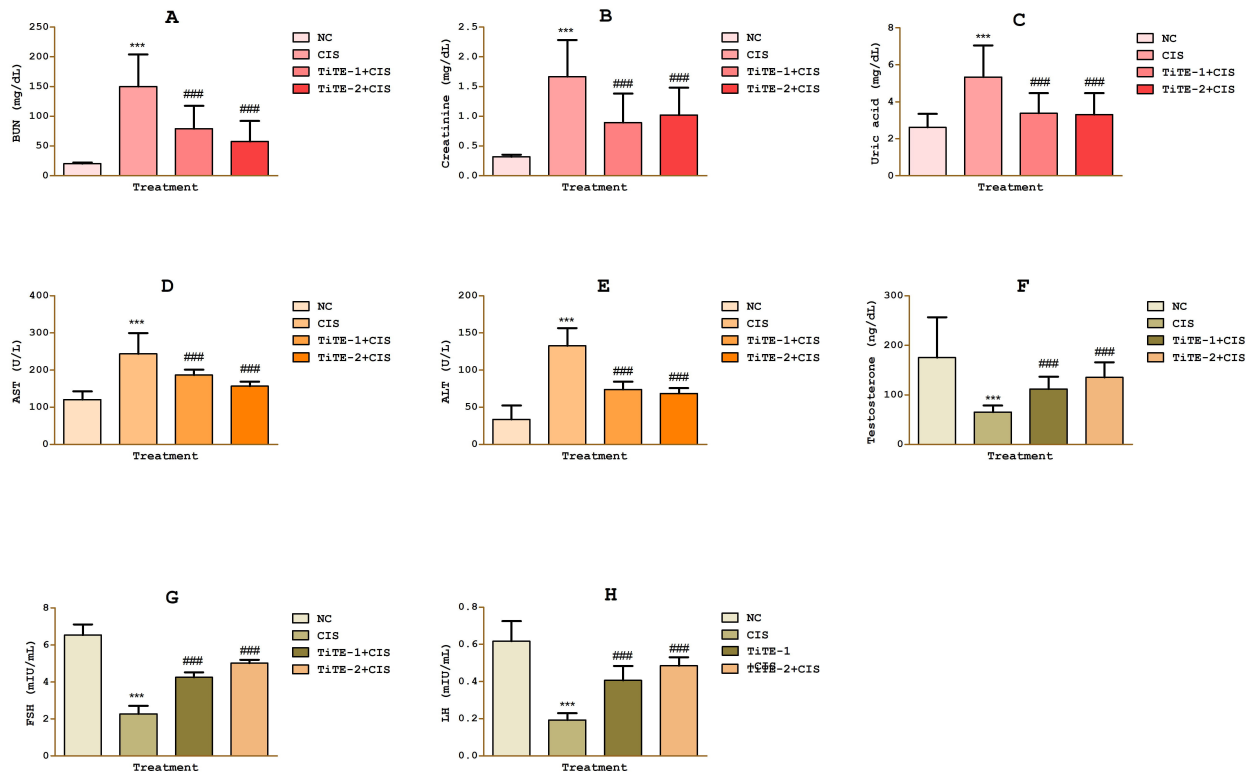


Fig. 2. Effect of TiTE on serum biochemical parameters A, BUN; B, creatinine; C, uric acid; D, AST; E, ALT; F, testosterone; G, FSH; H, LH in CIS treated rats. *** $p < 0.05$ compared to normal control; ### $p < 0.05$ compared to CIS group.

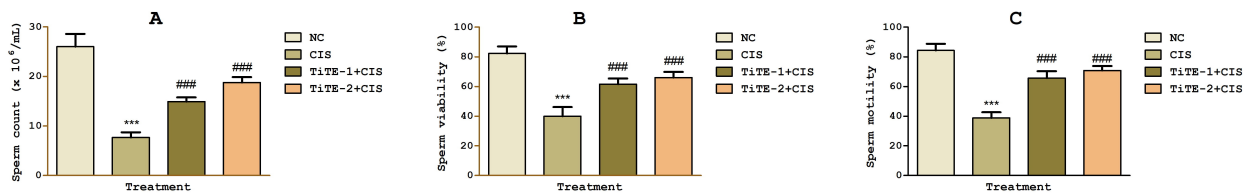


Fig. 3. Effect of TiTE on sperm functional parameters A, sperm count; B, sperm viability; C, sperm motility in CIS treated rats. *** $p < 0.05$ compared to normal control; ### $p < 0.05$ compared to the CIS group.

C). On the other hand, 4 weeks of TiTE treatment (250 and 500 mg/kg b.w.) significantly upregulated sperm count, sperm viability and sperm motility in comparison to CIS control group.

3.5 Effects of TiTE on hepatorenal and testicular oxidative stress in CIS treated rats

Fig. 4A–L shows the effect of TiTE on CIS induced oxidative stress. The activities of GPx, SOD and CAT were significantly depleted in the kidney, liver and testes, with corresponding increase in MDA levels in the liver, kidney and testes of the CIS control group when compared to the normal control group. TiTE treatments resulted in significant improvement in the hepatorenal and testicular activities of these aforementioned antioxidant enzymes. In addition to the increase in antioxidant enzymes activities, treat-

ment with TiTE also caused significant reduction in MDA levels in these tissues compared to CIS group (Fig. 4).

3.6 Effects of TiTE on hepatorenal and testicular proinflammatory cytokine of CIS treated rats

As shown in Fig. 5, the concentrations of proinflammatory cytokines (TNF- α , IL-1 β and IL-6) in the kidney (Fig. 5A–C), liver (Fig. 5D–F) and testes (Fig. 5G–I) of the CIS group were significantly augmented compared to the normal control group. On the other hand, in the groups treated with TiTE there were significant reduction in the levels of these proinflammatory cytokines compared to CIS group (Fig. 5A–I).

Kidney

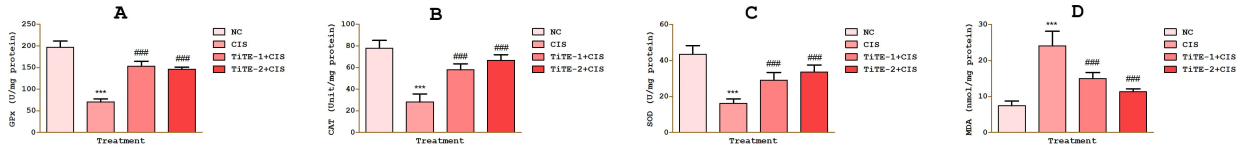


Fig. 4. Effect of TiTE on oxidative stress biomarkers in the kidney: A, GPx; B, CAT; C, SOD; D, MDA; liver: E, GPx; F, CAT; G, SOD; H, MDA; testes: I, GPx; B, CAT; C, SOD; D, MDA; in CIS treated rats. *** $p < 0.05$ compared to normal control; #### $p < 0.05$ compared to CIS group.

Kidney

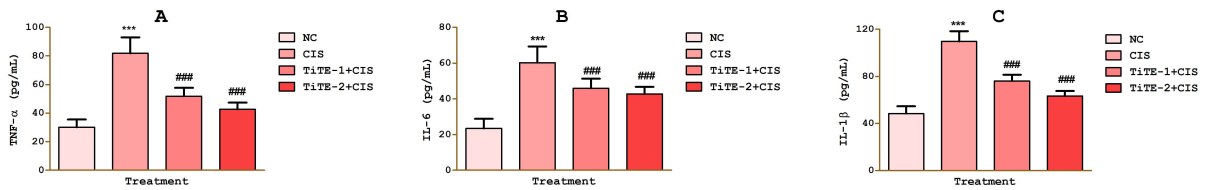


Fig. 5. Effect of TiTE on proinflammatory cytokines in the kidney: A, TNF- α ; B, IL-6; C, IL-1 β ; liver: D, TNF- α ; E, IL-6; F, IL-1 β ; testes: G, TNF- α ; H, IL-6; I, IL-1 β in CIS treated rats. *** $p < 0.05$ compared to normal control; #### $p < 0.05$ compared to CIS group.

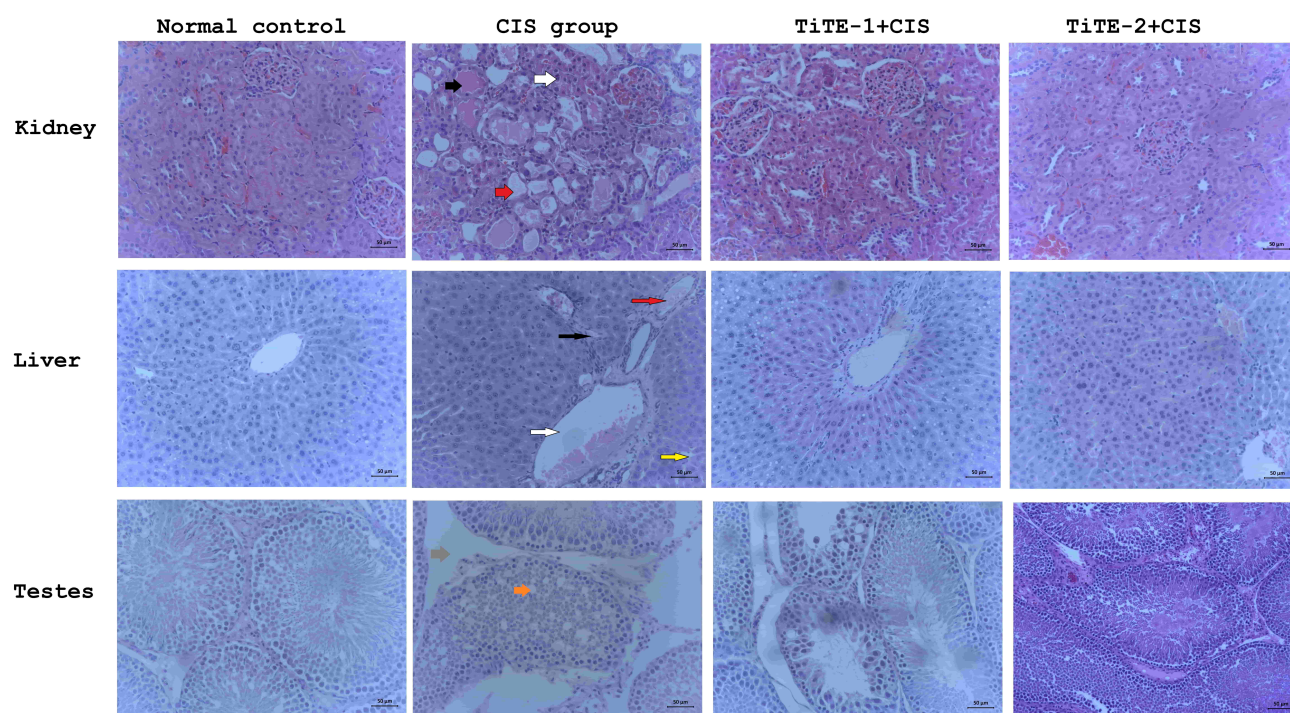


Fig. 6. Hematoxylin-eosin stained light microscopy images of the kidney, liver and testis tissues of rats in all experimental groups. Kidney: tubular and glomerular degeneration (red arrow), glomerular atrophy (white arrow), tubular cell vacuolation (black arrow). **Liver:** cytoplasmic vacuolation (yellow arrow), dilation of central vein (white arrow), inflammatory leucocytic infiltration (red arrow), hyperplasia (black arrow). **Testes:** spermatogenic cells atrophy (orange arrow), loss of Sertoli cells (brown arrow). 20×; Scale bars:50 µm.

3.7 Effects of TiTE histopathological alterations

The preventive effect of TiTE on cellular and morphological integrity of the kidney, liver and testicular tissues were assessed by hematoxylin-eosin staining. The histology photomicrographs of the kidney of all the treated groups is presented in Fig. 6. The renal tissues from CIS group showed glomerular atrophy, extreme tubular and glomerular degeneration as well as vacuolation of tubular cells (Fig. 6). In contrast, administration of TiTE markedly decreased CIS induced pathological lesions in the kidney tissues (Fig. 6). Significantly weaker morphological changes were evident in photomicrographs of the groups treated with TiTE.

The hepatic tissues from the CIS group showed significant hepatic damage including sinusoid dilatation, infiltration of inflammatory leucocytes, dilation of central vein, cytoplasmic vacuolation and bile duct hyperplasia as compared to the micrographs of the normal control group which showed normal hepatic cell architecture (Fig. 6). In contrast, the administration of TiTE significantly mitigated CIS-induced hepatotoxicity and improved these morphological changes as observed by decreased severity of dilatation and haemorrhage (Fig. 6).

Fig. 6C shows the representative photomicrographs of the testicular tissues of treated rats. The normal control group showed normal and matured seminiferous tubules

with adequate spermatogenic series and void of any abnormal alterations. Whereas, in the CIS group marked testicular injury including spermatogenic cells atrophy and loss of Sertoli cells were observed. Whereas, the micrographs of the testes from the groups that received TiTE showed significant improvement compared to the CIS control group (Fig. 6).

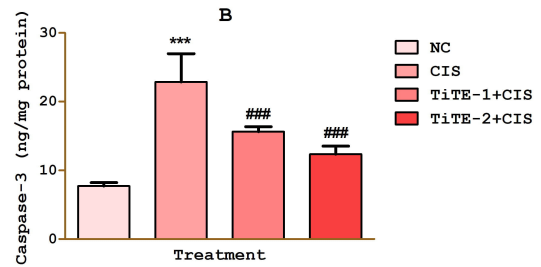
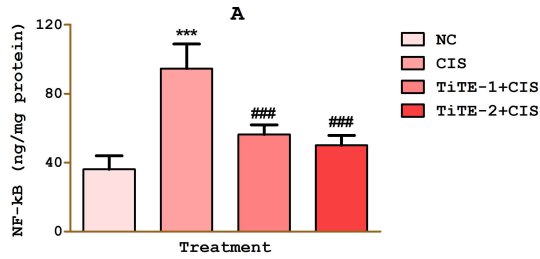
3.8 Effect of TiTE on hepatorenal and testicular caspase 3 and NF-κB levels of CIS treated rats

CIS treated rats displayed significantly elevated hepatorenal and testicular levels of NF-κB and caspase 3 compared to the normal control group, while the increased levels of NF-κB and caspase 3 in TiTE treated groups were significantly abated when compared to CIS group (Fig. 7A–F).

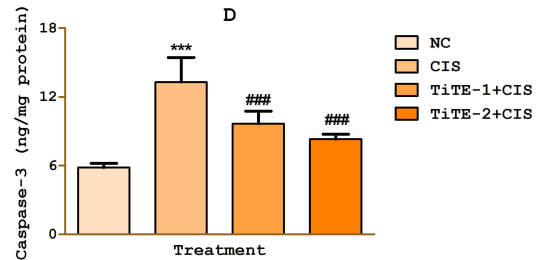
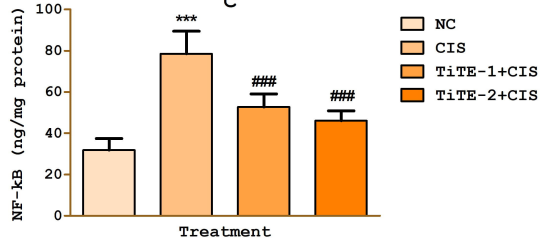
4. Discussion

Although the emergency of platinum based anticancer drugs have provided great relief in the treatment of cancer, the prevalence of secondary side effects associated with these drugs is worrisome. Cisplatin is a frontline choice in anticancer treatment options. However, it has gained considerable attention due to its notable multi-organ toxicity associated with deleterious redox-inflammatory cascades in major body organs. Currently, research efforts aimed

Kidney



Liver



Testes

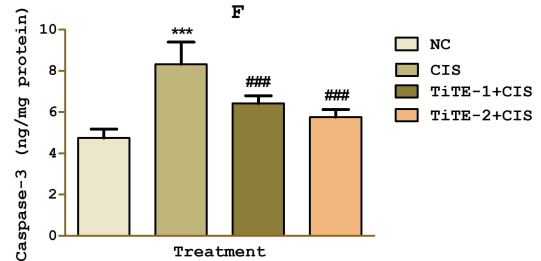
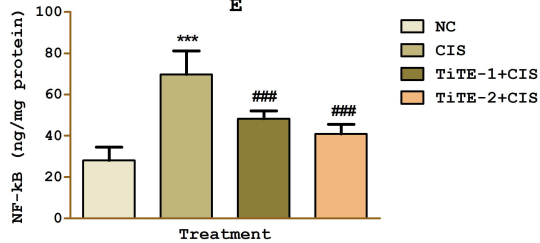


Fig. 7. Effect of TiTE on NF- κ B and caspase 3 in the kidney: A, NF- κ B; B, caspase 3; liver: C, NF- κ B; D, caspase 3; testes: E, NF- κ B; F, caspase 3 in CIS treated rats. * $p < 0.05$ compared to normal control; ### $p < 0.05$ compared to CIS group.**

at mitigating CIS non-targeted organ toxicity are exploring natural products [23]. In our previous study and that of others, *Tiliacora triandra* demonstrated antioxidant and anti-inflammatory activities [17,19], however its hepatorenal and testicular protective effects against CIS toxicity remains unknown. Therefore, we examined its effect on CIS-induced toxicity in the liver, testis and kidney of Wistar rats.

In the current study, the administration of CIS significantly retarded the body weight gain compared to that of normal control rats. Anticancer agents are known to perturb metabolism and cause loss of appetite. According to recent findings [24,25], CIS induced loss of body weight which may be associated with reduced food intake and metabolic dysfunction. This was further corroborated by Fulco *et al.* [26] that CIS depressed metabolic activity of citrate synthase, an enzyme involved in citric acid cycle for energy production. Furthermore, CIS caused marked increases in kidney weight and coefficient, while the liver and testes weights appreciably decreased compared to the weight of organs in control rats. The weight changes could be associated with the CIS-induced degeneration of histological microstructures in the liver, kidney and testes. In contrast,

TiTE obviously improved body weight gain, organ weight and its coefficient. This is consistent with earlier study showing the beneficial effect of TiTE on body and organ weight [17].

Biomarkers are reporters of tissue damage and they are usually considered in the treatment and management of diseases. In this study, serum BUN, creatinine and uric acid were considered as biomarkers of kidney damage; AST and ALT for liver injury, while serum levels of testosterone, LH and FSH were evaluated for testicular injury followed by characteristic histopathological analysis. CIS evidently inflicted damages on the liver and kidney as demonstrated by prominently increased serum levels of AST, ALT, BUN, creatinine and uric acid, respectively. It is well known that hepatic injury due to toxins compromises hepatic transport function and increases membrane permeability leading to leakage of marker enzymes, including ALT and AST from the hepatocytes [27,28]. However, the marked increase in these enzymes in our study indicated the extent of CIS damage on the liver [28]. Renal injury and renal dysfunction are indicated by increased levels of serum BUN, uric acid and creatinine. This study revealed nephrotoxic damage

induced by CIS characterized by considerable increases in serum uric acid, BUN and creatinine levels. Conceivably, CIS exposure might have adversely affected glomerular filtration and ultrafiltration underlying the accumulation of creatinine, BUN, and uric acid in the blood as shown in this study. Our results regarding hepatorenal damage induced by CIS agreed with reported hepatorenal damage induced by CIS in earlier studies [25,26,29,30]. On the contrary, TiTE decreased alterations in serum hepatorenal biomarkers investigated in this study. The liver enzyme activities and serum uric acid, BUN and creatinine levels were prominently reduced compared to the CIS control group.

Furthermore, CIS impaired spermatogenesis with consequent diminution in epididymal sperm quality and endocrine balance in the current study. Emerging evidences have implicated CIS as a strong disruptor of reproductive homeostasis [24,31,32]. In the CIS-injected rats, the sperm count, motility and viability were considerably reduced compared to the normal healthy control. The spermatotoxic effect of CIS could be associated with significantly reduced levels of testosterone, FSH and LH. The role of testosterone in spermatogenesis is well established; it modulates the conversion of round spermatids into elongated spermatids in the spermatogenetic cycle. The reduced level of testosterone found in this study might resulted into too early detachment of round spermatids from Sertoli cells and seminal epithelium [33,34]. The effect of CIS on hypothalamic–pituitary–gonadal axis may induce FSH deficit [35]. However, FSH deficit might adversely affect testicular Leydig cell steroidogenesis resulting in depressed testosterone synthesis. Altogether, the present observations suggested that sperm anomalies might be attributed to alterations in testosterone, FSH and LH in consistent with previous studies [36–38]. Interestingly, TiTE administration abrogated CIS-induced sperm abnormalities and restored levels of serum testosterone, FSH and LH compared to the CIS control group.

The well-reported pathogenesis of CIS toxicity is related to reactive oxygen species (ROS) mediated pathways, including oxidative injury and inflammatory perturbations [39,40]. Redox impairment provokes oxidative stress and aberrant signalling for tissue injury. Previous studies have shown that CIS suppresses antioxidant defence mechanisms and consequently mediates peroxidative attack [5,36,39]. Herein, CIS injection depressed SOD, CAT and GPx activities, while the MDA level increased notably in the testes, kidney and liver. CIS generates ROS capable of deactivating SOD and CAT and increases the cellular utilization of GSH, leading to reduced cellular antioxidant enzyme activities and glutathione homeostasis [41]. The resultant oxidative milieu attacks lipid-laden bio-membranes to initiate lipid peroxidation, hence the increased level of MDA in our study. Thus, oxidative stress status occasioned by CIS attack on antioxidant apparatus damaged histological cytoarchitecture of the organs. We observed spermatogenic at-

rophy and degeneration of Sertoli cells in consistent with earlier reports [24,40]. Interestingly, TiTE administration abrogated CIS-induced oxidative stress via significantly increasing SOD, CAT and GPx activities which consequently yielded prominent depreciation in MDA levels. Increased tissue antioxidant activities preserves enzymatic defence mechanism that mitigates oxidative stress. The histopathological alterations were also alleviated close to normal histology of the liver, kidney and testes. Studies have shown that medicinal plant extracts are reservoirs of antioxidant bioactive compounds that mediate scavenging of ROS and drug-induced toxicity *in vivo* [42]. Like TiTE in our study, extracts of medicinal plants have inhibited CIS-induced oxidative stress by upregulating cellular antioxidant machinery [30,43,44]. Song *et al.* [17] recently showed that TiTE counteracted oxidative stress in diabetic kidney and testicular impairment.

Several signaling pathways are triggered by oxidative stress status. Cisplatin activates ROS generation that provokes activation of transcription factors and apoptosis [45]. CIS activates nuclear factor-kappa B (NF- κ B), a transcription factor that stimulates the expression of proinflammatory cytokines, growth factor-related proliferation, adhesion molecules and survival genes [43]. In response to CIS toxicity in this study, the markedly elevated expression of NF- κ B promoted considerable increases in proinflammatory cytokines levels (IL-6, IL-1 β and TNF- α). The elevated expression of NF- κ B indicates its activation and transcription by CIS-induced oxidative stress [25,46]. Its nuclear translocation unlocks inflammatory gene expression underlying the cause for increased cytokine levels in this study. Furthermore, the integrated network of redox-inflammatory responses impairs mitochondrial integrity leading to the release of cytochrome C and caspases for execution of cytotoxic apoptosis [47]. In consistent with previous studies we found considerably elevated caspase-3 activity in the kidney, liver and testes [46]. This indicated apoptosis induced by CIS via redox imbalance and proinflammation. Among caspases, caspase-3 is the main executor of apoptosis triggering enzyme degradation, protein denaturation and cell death [48,49]. Our findings herein confirmed suggestions in existing literatures that cytotoxic apoptosis and inflammatory responses play a mechanistic role in the pathophysiology of CIS-induced organ toxicity [29,46,50,51]. Strikingly, TiTE significantly diminished NF- κ B and cytokine levels (IL-6, IL-1 β and TNF- α). In agreement with our earlier finding showing the anti-inflammatory and antiapoptotic effect of TiTE [17,20], TiTE inhibited CIS-induced pro-inflammation and apoptosis that chiefly mediate pathologies in several tissue injuries.

5. Conclusions

In conclusion, the results from this study suggested that TiTE exhibited hepatorenal and testicular protective ef-

fects against CIS induced toxicity primarily by preventing oxidative stress, improving antioxidant system, inhibiting inflammation and ameliorating endocrine deficits.

Author contributions

CW and OJO conceived and designed the study. XMZ, XZP and OJO conducted the experiments and analyzed the data. OJO and AF wrote the manuscript. All authors approved the final version of the manuscript.

Ethics approval and consent to participate

The Institutional Ethics Committee approved the protocol for the animal experiment and all animal experimental procedures were performed in strict compliance with National Institute of Health for the care and use of laboratory animals.

Acknowledgment

Not applicable.

Funding

This research received no external funding.

Conflict of interest

The authors declare no conflict of interest.

References

- [1] Sung H, Ferlay J, Siegel RL, Laversanne M, Soerjomataram I, Jemal A, *et al.* Global Cancer Statistics 2020: GLOBOCAN Estimates of Incidence and Mortality Worldwide for 36 Cancers in 185 Countries. *CA: A Cancer Journal for Clinicians.* 2021; 71: 209–249.
- [2] Torre LA, Siegel RL, Ward EM, Jemal A. Global Cancer Incidence and Mortality Rates and Trends—an Update. *Cancer Epidemiology Biomarkers & Prevention.* 2016; 25: 16–27.
- [3] Bahnassy AA, Abdellateif MS, Zekri AN. Cancer in Africa: Is it a genetic or environmental health problem? *Frontiers in Oncology.* 2020; 10: 604214.
- [4] Liu N, Zhou S, Olatunji OJ, Wu Y. Nucleosides rich extract from *Cordyceps cicadae* alleviated cisplatin-induced neurotoxicity in rats: a behavioral, biochemical and histopathological study. *Arabian Journal of Chemistry.* 2022; 15: 103476.
- [5] Wang L, He Y, Li Y, Pei C, Olatunji OJ, Tang J, *et al.* Protective effects of nucleosides-rich extract from *Cordyceps cicadae* against cisplatin induced testicular damage. *Chemistry & Biodiversity.* 2020; 17: e2000671.
- [6] Quintanilha JCF, Saavedra KF, Visacri MB, Moriel P, Salazar LA. Role of epigenetic mechanisms in cisplatin-induced toxicity. *Critical Reviews in Oncology/Hematology.* 2019; 137: 131–142.
- [7] Hakiminia B, Goudarzi A, Moghaddas A. Has vitamin E any shreds of evidence in cisplatin-induced toxicity. *Journal of Biochemical and Molecular Toxicology.* 2019; 33: e22349.
- [8] Rahimi A, Asadi F, Rezghi M, Kazemi S, Soorani F, Memariani Z. Natural products against cisplatin-induced male reproductive toxicity: a comprehensive review. *Journal of Biochemical and Molecular Toxicology.* 2021: e22970. (in press)
- [9] Habib SA, Suddek GM, Abdel Rahim M, Abdelrahman RS. The protective effect of protocatechuic acid on hepatotoxicity induced by cisplatin in mice. *Life Sciences.* 2021; 277: 119485.
- [10] Ozkok A, Edelstein CL. Pathophysiology of Cisplatin-Induced Acute Kidney Injury. *BioMed Research International.* 2014; 2014: 967826.
- [11] Liao W, Wang Z, Fu Z, Ma H, Jiang M, Xu A, *et al.* P62/SQSTM1 protects against cisplatin-induced oxidative stress in kidneys by mediating the cross talk between autophagy and the Keap1-Nrf2 signalling pathway. *Free Radical Research.* 2019; 53: 800–814.
- [12] Zhang J, Wang J, Xu X, Yang J, Wang Z, Jiang S, *et al.* Red ginseng protects against cisplatin-induced intestinal toxicity by inhibiting apoptosis and autophagy via the PI3K/AKT and MAPK signaling pathways. *Food & Function.* 2020; 11: 4236–4248.
- [13] Stankovic JSK, Selakovic D, Mihailovic V, Rosic G. Antioxidant supplementation in the treatment of neurotoxicity induced by platinum-based chemotherapeutics-A review. *International Journal of Molecular Sciences.* 2020; 21: 7753.
- [14] Makinde EA, Ovatlarnporn C, Adekoya AE, Nwabor OF, Olatunji OJ. Antidiabetic, antioxidant and antimicrobial activity of the aerial part of *Tiliacora triandra*. *South African Journal of Botany.* 2019; 125: 337–343.
- [15] Makinde EA, Radenahmad N, Adekoya AE, Olatunji OJ. *Tiliacora triandra* extract possesses antidiabetic effects in high fat diet/streptozotocin-induced diabetes in rats. *Journal of Food Biochemistry.* 2020; 44: e13239.
- [16] Phunchago N, Wattanathorn J, Chaisiwamongkol K. *Tiliacora triandra*, an Anti-Intoxication Plant, Improves Memory Impairment, Neurodegeneration, Cholinergic Function, and Oxidative Stress in Hippocampus of Ethanol Dependence Rats. *Oxidative Medicine and Cellular Longevity.* 2015; 2015: 918426.
- [17] Song P, Sun C, Li J, Long T, Yan Y, Qin H, Makinde EA, Famurewa AC, Jaisi A, Niei Y, and Olatunji OJ. *Tiliacora triandra* extract and its major constituent attenuates diabetic kidney and testicular impairment by modulating redox imbalance and pro-inflammatory responses in rats. *Journal of the Science of Food and Agriculture.* 2021; 101: 1598–1608.
- [18] Singthong J, Oonsivilai R, Oonmetta-Aree J, Ningsanon S. Bioactive compounds and encapsulation of Yanang (*Tiliacora triandra*) leaves. *African Journal of Traditional, Complementary, and Alternative Medicines.* 2014; 11: 76–84.
- [19] Thong-asa W, Bullangpoti V. Neuroprotective effects of *Tiliacora triandra* leaf extract in a mice model of cerebral ischemia reperfusion. *Avicenna Journal of Phytomedicine.* 2020; 10: 202–212.
- [20] Huang Y, Liu C, Song X, An M, Liu M, Yao L, Famurewa AC, Olatunji OJ. Antioxidant and anti-inflammatory properties mediate the neuroprotective effects of hydro-ethanolic extract of *Tiliacora triandra* against cisplatin-induced neurotoxicity. *Journal of Inflammation Research.* 2021; 14: 6735–6748.
- [21] Zhao LL, Makinde EA, Olatunji OJ. Protective effects of ethyl acetate extract from *Shorea roxburghii* against diabetes induced testicular damage in rats. *Environmental Toxicology.* 2021; 36: 374–385.
- [22] Liu C, Ma M, Wen C, Uz Zaman R, Olatunji OJ. Antiallodynic and anti-hyperalgesia effects of *Tiliacora triandra* against cisplatin-induced peripheral neuropathy. *All Life.* 2021; 14: 441–449.
- [23] Azubuiké-Osu SO, Famurewa AC, David JC, Abi I, Ogbu PN, Oparaji CK, *et al.* Virgin Coconut Oil Resists Arsenic-Induced Cerebral Neurotoxicity and Cholesterol Imbalance via Suppression of Oxidative Stress, Adenosine Deaminase and Acetylcholinesterase Activities in Rats. *Natural Product Communications.* 2021; 16: 1–8.
- [24] Famurewa AC, Ekeleme-Egedigwe CA, Onwe CS, Egedigwe UO, Okoro CO, Egedigwe UJ, *et al.* Ginger juice prevents cisplatin-induced oxidative stress, endocrine imbalance and no/iNOS/NF-κB signalling via modulating testicular re-

- dox-inflammatory mechanism in rats. *Andrologia*. 2020; 52: e13786.
- [25] Potočnjak I, Marinić J, Batičić L, Šimić L, Broznić D, Domitrović R. Aucubin administered by either oral or parenteral route protects against cisplatin-induced acute kidney injury in mice. *Food and Chemical Toxicology*. 2020; 142: 111472.
- [26] Fulco BCW, Jung JTK, Brum LOB, Zborowski VA, Goulart TAC, Nogueira CW. Similar hepatoprotective effectiveness of Diphenyl diselenide and Ebselen against cisplatin-induced disruption of metabolic homeostasis and redox balance in juvenile rats. *Chemico-Biological Interactions*. 2020; 330: 109234.
- [27] Famurewa AC, Ekeleme-Egedigwe CA, Nwali SC, Agbo NN, Obi JN, Ezechukwu GC. Dietary Supplementation with Virgin Coconut Oil Improves Lipid Profile and Hepatic Antioxidant Status and has Potential Benefits on Cardiovascular Risk Indices in Normal Rats. *Journal of Dietary Supplements*. 2018; 15: 330–342.
- [28] Mughadam AR, Tutunchi S, Namvaran-Abbas-Abad A, Yazdi M, Bonyadi F, Mohajeri D, *et al.* Pre-administration of turmeric prevents methotrexate-induced liver toxicity and oxidative stress. *BMC Complementary and Alternative Medicine*. 2015; 15: 246.
- [29] Salama SA, Abd-Allah GM, Mohamadin AM, Elshafey MM, Gad HS. Ergothioneine mitigates cisplatin-evoked nephrotoxicity via targeting Nrf2, NF-κB, and apoptotic signaling and inhibiting γ-glutamyl transpeptidase. *Life Sciences*. 2021; 278: 119572.
- [30] Mohamadi Yarijani Z, Godini A, Madani SH, Najafi H. Reduction of cisplatin-induced renal and hepatic side effects in rat through antioxidative and anti-inflammatory properties of *Malva sylvestris* L. extract. *Biomedicine & Pharmacotherapy*. 2018; 106: 1767–1774.
- [31] Mercantepe T, Unal D, Tümkaya L, Yazici ZA. Protective effects of amifostine, curcumin and caffeic acid phenethyl ester against cisplatin-induced testis tissue damage in rats. *Experimental and Therapeutic Medicine*. 2018; 15: 3404–3412.
- [32] Sabanegh ES, Ragheb AM. Male fertility after cancer. *Urology*. 2009; 73: 225–231.
- [33] Said RS, Mohamed HA, Kassem DH. Alpha-lipoic acid effectively attenuates ionizing radiation-mediated testicular dysfunction in rats: Crosstalk of NF-κB, TGF-β, and PPAR-γ pathways. *Toxicology*. 2020; 442: 152536.
- [34] Beardsley A, O'Donnell L. Characterization of normal spermiation and spermiation failure induced by hormone suppression in adult rats. *Biology of Reproduction*. 2003; 68: 1299–1307.
- [35] Aydiner A, Aytekin Y, Topuz E. Effects of cisplatin on testicular tissue and the Leydig cell-pituitary axis. *Oncology*. 1997; 54: 74–78.
- [36] Nna VU, Ujah GA, Suleiman JB, Mohamed M, Nwokocha C, Akpan TJ, *et al.* Tert-butylhydroquinone preserve testicular steroidogenesis and spermatogenesis in cisplatin-intoxicated rats by targeting oxidative stress, inflammation and apoptosis. *Toxicology*. 2020; 441: 152528.
- [37] Saad KM, Abdelrahman RS, Said E. Mechanistic perspective of protective effects of nilotinib against cisplatin-induced testicular injury in rats: Role of JNK/caspase-3 signaling inhibition. *Environmental Toxicology and Pharmacology*. 2020; 76: 103334.
- [38] Shati AA. Resveratrol improves sperm parameter and testicular apoptosis in cisplatin-treated rats: Effects on ERK1/2, JNK, and Akt pathways. *Systems Biology in Reproductive Medicine*. 2019; 65: 236–249.
- [39] Ali FE, Hassanein EH, El-Bahrawy AH, Omar ZM, Rashwan EK, Abdel-Wahab BA, *et al.* Nephroprotective effect of umbelliferone against cisplatin-induced kidney damage is mediated by regulation of NRF2, cytoglobin, SIRT1/FOXO-3, and NF-KB-p65 signaling pathways. *Journal of Biochemical and Molecular Toxicology*. 2021; 35: e22738.
- [40] Eren H, Mercantepe T, Tümkaya L, Mercantepe F, Dil E, Hørsanali MO, *et al.* Evaluation of the protective effects of amifostine and melatonin against cisplatin induced testis injury via oxidative stress and apoptosis in rats. *Experimental and Molecular Pathology*. 2020; 112: 104324.
- [41] Moradi M, Goodarzi N, Faramarzi A, Cheraghi H, Hashemian AH, Jalili C. Melatonin protects rats testes against bleomycin, etoposide, and cisplatin-induced toxicity via mitigating nitro-oxidative stress and apoptosis. *Biomedicine & Pharmacotherapy*. 2021; 138: 111481.
- [42] Heidary Mughaddam R, Samimi Z, Moradi SZ, Little PJ, Xu S, Farzaei MH. Naringenin and naringin in cardiovascular disease prevention: a preclinical review. *European Journal of Pharmacology*. 2020; 887: 173535.
- [43] Hu J, Yang J, Jiang S, Zhang J, Liu Z, Hou J, *et al.* Panax quinquefolium saponins protect against cisplatin evoked intestinal injury via ROS-mediated multiple mechanisms. *Phytomedicine*. 2021; 82: 153446.
- [44] Eltamany EE, Elhady SS, Nafie MS, Ahmed HA, Abo-Elmatty DM, Ahmed SA, *et al.* The antioxidant *Carrichtera annua* DC. ethanolic extract counteracts cisplatin triggered hepatic and renal toxicities. *Antioxidants*. 2021; 10: 825.
- [45] Sohail N, Hira K, Kori JA, Farhat H, Urooj F, Khan W, *et al.* Nephroprotective effect of ethanol extract and fractions of a sea lettuce, *Ulva fasciata* against cisplatin-induced kidney injury in rats. *Environmental Science and Pollution Research*. 2021; 28: 9448–9461.
- [46] kaygusuzoglu E, Caglayan C, Kandemir FM, Yıldırım S, Kucukler S, Kılınç MA, *et al.* Zingerone ameliorates cisplatin-induced ovarian and uterine toxicity via suppression of sex hormone imbalances, oxidative stress, inflammation and apoptosis in female wistar rats. *Biomedicine & Pharmacotherapy*. 2018; 102: 517–530.
- [47] Kannan, Jain. Oxidative stress and apoptosis. *Pathophysiology*. 2000; 7: 153–163.
- [48] Verma VK, Malik S, Mutneja E, Sahu AK, Bhatia J, Arya DS. Attenuation of ROS-mediated myocardial ischemia-reperfusion injury by morin via regulation of RISK/SAPK pathways. *Pharmacological Reports*. 2020; 72: 877–889.
- [49] Eldutar E, Kandemir FM, Kucukler S, Caglayan C. Restorative effects of Chrysin pretreatment on oxidant-antioxidant status, inflammatory cytokine production, and apoptotic and autophagic markers in acute paracetamol-induced hepatotoxicity in rats: an experimental and biochemical study. *Journal of Biochemical and Molecular Toxicology*. 2017; 31: e21960.
- [50] Badawy AM, El-Naga RN, Gad AM, Tadros MG, Fawzy HM. Wogonin pre-treatment attenuates cisplatin-induced nephrotoxicity in rats: Impact on PPAR-γ, inflammation, apoptosis and Wnt/β-catenin pathway. *Chemico-Biological Interactions*. 2019; 308: 137–146.
- [51] Ibrahim MA, Albahlol IA, Wani FA, Abd-Eltawab Tammam A, Kelleni MT, Sayeed MU, *et al.* Resveratrol protects against cisplatin-induced ovarian and uterine toxicity in female rats by attenuating oxidative stress, inflammation and apoptosis. *Chemico-Biological Interactions*. 2021; 338: 109402.