



## LJMU Research Online

Houlton, TMR and Wilkinson, C

**Recently identified features that help to distinguish ceremonial tsantsa from commercial shrunken heads**

<http://researchonline.ljmu.ac.uk/3436/>

### Article

**Citation** (please note it is advisable to refer to the publisher's version if you intend to cite from this work)

**Houlton, TMR and Wilkinson, C (2016) Recently identified features that help to distinguish ceremonial tsantsa from commercial shrunken heads. Journal of Cultural Heritage. ISSN 1296-2074**

LJMU has developed **LJMU Research Online** for users to access the research output of the University more effectively. Copyright © and Moral Rights for the papers on this site are retained by the individual authors and/or other copyright owners. Users may download and/or print one copy of any article(s) in LJMU Research Online to facilitate their private study or for non-commercial research. You may not engage in further distribution of the material or use it for any profit-making activities or any commercial gain.

The version presented here may differ from the published version or from the version of the record. Please see the repository URL above for details on accessing the published version and note that access may require a subscription.

For more information please contact [researchonline@ljmu.ac.uk](mailto:researchonline@ljmu.ac.uk)

<http://researchonline.ljmu.ac.uk/>

## Highlights

- 65 shrunken human heads were examined using IRR, CT and microscopic hair analysis.
- Ten new characteristics for distinguishing ceremonial and commercial heads were identified.
- Commercial heads may be more reliably identified, than ceremonial *tsantsa*.
- Evidence of nits (*Pediculus humanis capitis De Geer*) and black piedra (*Trichomycosis nodularis*) can indicate the environment heads once existed.
- Unstained skins demonstrate a grey-white epidermis and yellow dermis.

Keywords: Tsantsa, Shrunken heads, Authenticity, IR investigation, CT analysis, Hair analysis.

# Recently identified features that help to distinguish ceremonial *tsantsa* from commercial shrunken heads

Tobias M. R. Houlton<sup>1</sup>, Caroline M. Wilkinson<sup>2</sup>

## Abstract

This is an anthropological investigation into a collection of 65 shrunken human heads, to determine if new characteristics can be identified to facilitate the differentiation between ceremonial *tsantsa* and commercial shrunken heads. Ceremonial *tsantsa* refers to shrunken heads mummified as war trophies within the ancient traditions and rituals of the Amazonian Shuar, Achuar, Awajún/Aguaruna, Wampís/Huambisa and Candoshi-Shapra (SAAWC). Commercial shrunken heads are comparatively modern objects constructed specifically for the collector market of the past. Low earning individuals in South and Middle America, outwith the SAAWC culture, who had access to corpses and appropriate medical or taxidermy provisions, produced these for trade purposes. These heads were made in abundance and do not present the same historical value or heritage as ceremonial *tsantsa*. The relevance of an accurate provenance for heads may directly impact museums, with regard to identifying the authenticity of a specimen and how they should handle any potential requests to return such artefacts to their cultural homes.

Complying with current anthropological standards, a total of 6 ceremonial *tsantsa* and 36 commercial heads were identified. Greater confidence is prescribed to the assignment of commercial heads as their morphological appearance is at odds with the highly standardised presentation of ceremonial *tsantsa*. Many indicated that the processor had access to modern resources such as gloves and fine suturing equipment, which were not typically available to the SAAWC. Since traders sometimes closely replicating ceremonial *tsantsa* when shrinking and decorating heads for trade, limited certainty can be prescribed to this category. Minor deviations in ceremonial design resulted in 23 heads being defined as ambiguous in origin.

Each head was examined by manual inspection, infrared reflectography (IRR), CT and microscopic hair analysis, with ten new differentiating characteristics identified.

## 1. Introduction

Head shrinking was originally a renowned war trophy custom, where a full-scale human head was reduced typically to the size of a large orange. The skull was removed and the head trophy formed by manually remoulding the mummified skin while retaining the scalp hair of the decapitated victim. There is physical evidence of this custom once being performed in a ritualistic context by the tribal populous inhabiting the eastern montaña of Ecuador and northern Peru (the Shuar, Achuar, Awajún/Aguaruna, Wampís/Huambisa and Candoshi-Shapra – SAAWC), within the primitive conditions of the Amazonian rainforest. These specimens are referred to as ‘ceremonial *tsantsa*’ – *tsantsa* being the original cultural term for a shrunken head [1, 2, 3].

From the mid 1800s, the European trade for ceremonial *tsantsa* expanded rapidly as the Victorian collectors of curios considered these to be objects of desire. The first documented emergence date of

shrunken heads being produced specifically by outsiders for solely curio trade purposes was in 1872 [1, 4]. Heads were procured from any accessible human subjects, with animal skins often used to produce counterfeits designed to resemble human shrunken heads. These were manufactured in abundance across much of South and Middle America, commonly by third world doctors, mortuary technicians and taxidermists, who had access to contemporary surgical materials and protective gloves. These heads can often be distinguished from ceremonial *tsantsa* and are referred to as ‘commercial shrunken heads’ [1, 2, 3].

Accounts speculate that 80% of existing shrunken heads currently residing in museums and private collections, are commercially produced counterfeits made from human or animal remains [5, 6]. The rarity of ceremonial *tsantsa* makes them a desirable novelty. The origins of ceremonial *tsantsa* as war trophies produced for ritual practices, arguably gives them a conceptual value that surpasses the comparatively contrived commercial heads. Such heads being fraudulently manufactured by a relatively contemporary population, solely to generate a financial income. The provenance of such specimens may also impact how museums wish to undertake requests to return heads to their cultural home. Ceremonial *tsantsa* were likely of SAAWC persons and thus should be returned to one of the SAAWC authorities. Commercial heads could have originated from anywhere across South and Middle America, potentially complicating their repatriation.

Significant indicators, such as ear morphology, skin texture, microscopic hair structure and DNA have been recognised by anthropologists to distinguish human from animal remains with confidence [2, 7, 8, 9, 10]. Findings from anthropological and ethnological investigations has further established morphological features and decorative ornamentation that can be used to distinguish human ceremonial *tsantsa* from human commercial heads, see Table 1 [1, 2, 3, 11, 12, 13]. The aim of this investigation was to identify new preservation or morphological characteristics that may enhance future discrimination between ceremonial *Tsantsa* and commercial heads. This study incorporates manual inspection, infrared reflectography (IRR), computerised tomography (CT) and microscopic hair analysis.

**Table 1.** Established standards for Ceremonial *tsantsa* and Commercial shrunken heads [1, 2, 3, 11, 12, 13].

Ceremonial <i>tsantsa</i>	Commercial shrunken head
1. Size approximately equal to a clenched human fist.	1. Variable scale.
2. Posterior median sutured incision.	2. Variable incision locations.
3. Sutures are often wide and uneven – performed using a thick and inflexible flat bamboo needle with coarse chambira vegetable fibre string.	3. Stitches are usually more precise, discreet and consistent – due to access to finer, sharper, metal needles and thinner suture threads.
4. Loop of flexible vine is sewn into the neck – if absent, traces of suturing are often evident.	4. No supporting vine at the neck structure.
5. Eyelids are tightly drawn into the head and sutured shut.	5. Can be variable, but the eyelids are often sutured with the upper lid positioned over the lower lid.
6. Three mouth perforations from chonta pin application – sometimes retained and lashed together with chambira.	6. No, or a variable number of perforations mark the mouth. If pins are present, they are not always chonta wood.
7. The mouth pins are classically replaced with intricately woven string tassels applied to the mouth at a length equal to the scalp hair. Several horizontal red bands of achiote are painted, but these can fade over time.	7. Tassels are often not attached. If present, atypical colourants, materials and knots for securing them, may be present.
8. Skin browned from carbon staining.	8. Skin remains unstained, presenting as a grey or yellow colour.
9. Facial down removed.	9. Facial down is sometimes maintained.

10. Skin is polished.	10. Skin can sometimes present a dull, rough texture.
11. Narrow heads, often presenting a 'pinched' impression at the temples.	11. Care was often taken to retain more natural proportions. The curio trade was preoccupied with human heads, thus care was taken to preserve its human appearance.
12. Common distortions include the forced extension of the mouth, and the spreading and upturning of the nose.	12. Forced distortions were typically avoided.
13. Typically long scalp hair is present, with no facial hair.	13. Scalp hair can vary in length. Facial hair is often maintained.
14. One or two perforations mark the crown, with one fitting a vegetable fibre string suspension cord (woven into a five-loop braid) that is secured within the head by a small wooden pin. The cords are long enough for adornment about a person's neck.	14. Heads are not always perforated to fit a cord. If cords are fitted, they can be produced from a variety of different materials, woven differently, overly decorated and of an inappropriate length for personal adornment around someone's neck.
15. Piercings that would typically present at the earlobes of SAAWC victims were not always decorated. Toucan feather ear dangles and/or wooden tubes/pins are however common.	15. Headbands, necklaces and any ornamentation consisting of beads, seeds, or portions of seeds, are not documented in SAAWC material culture.
16. Skins tend to be dense and of considerable weight.	16. Skins can sometimes be thin, fragile and lightweight.

## 2. Materials: specimen selection

A total of 65 shrunken human heads were accessed for this investigation – 44 came from the Science Museum (London, UK), 20 from the Smithsonian Institute (Washington DC, USA), and one from the Elgin Museum (Elgin, UK).

## 3. Methods

Each specimen was handled using latex rubber gloves to avoid further surface contamination. Investigative techniques employed:

1. Manual inspection – details regarding the general morphology of the head and facial features were assessed for distortions and differences in their preparation. This included the location of handling compressions and the application of any sutures or other possible foreign materials.

To form the basis for discrimination and identify new patterns in ceremonial and commercial processing, the processing origins of each head were estimated according to the criteria defined in Table 1.

2. Infrared reflectography (IRR) – IR penetrates the skin to highlight deeper structural details, emphasising textural patterns in the tissue structure, including pathologies, scars and hair follicles [14].

To prepare each specimen for IRR image capture, heads were mounted temporarily over a stand, cushioned by white acid-free tissue paper. Hair was pushed back behind the ears carefully and secured with a regular metal hairpin, to enable maximum viewing of the facial details. To minimise perspective distortion during image capture, an optimal distance between a living subject and camera lens is typically recommended at 2m [15]. Shrunken heads are however often reduced to approximately a fifth the size of an average adult head. Subject to camera distance was thus set to 0.5m (quarter of the passport standard) to reduce the working space and strength of lens required, while still allowing for the moderately larger variations in shrunken head size to be photographed.

IRR was performed using a Fujifilm FinePix IS-1 camera, with a 28-300mm zoom lens. An infrared light-

emitting diode (IR LED) illuminated each head in a dark room, void of all natural light. To illuminate each face, the IR LED was positioned inferior to the camera lens and tilted slightly upwards towards the near parallel subject. An even light was cast with minimal shadow. An RG780 long pass transmission filter was applied over the camera lens. This reflected most of the visible spectrum and transmitted much of the IR region that was longer than the  $780\pm 9\text{nm}$  cut-off for image capture.

An ISO camera speed of 200+ is recommended for IRR [16]. IR lighting was intense enough to maintain the ISO at 200, avoiding a grainy image texture. The zoom lens was adjusted to 50-55mm and the aperture set to  $f-11$ , to preserve depth of field. Using a RG780 filter, the camera required a longer shutter speed of 1sec to obtain adequate exposure. To avoid blurred images, the camera was mounted securely onto a tripod.

3. Computerised tomography (CT) – a professional radiographer operated a Siemens SOMATOM Emotion CT scanner. This provided spiral 1mm slices and a 3D reconstruction of all heads, which were scanned in transverse. Image size consisted of  $512 \times 512$  pixels, offering a resolution sufficient for examining the general morphology of each head. Scans were presented as DICOM (Digital Imaging and Communications in Medicine) DCM files and viewed in OsiriX.

Due to limited facilities, CT scans were available for only 11 heads – comprising 2 ceremonial *tsantsa*, 6 commercial heads and 3 heads of ambiguous origin.

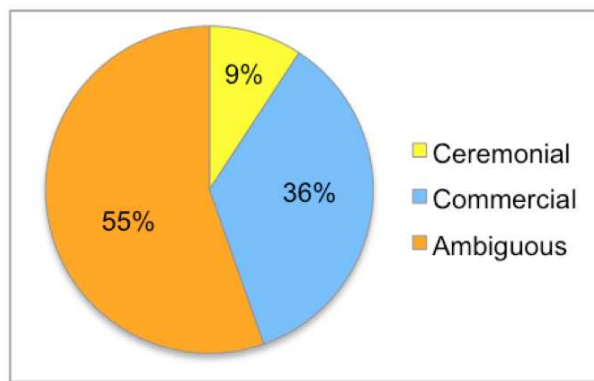
4. Microscopic hair analysis – used to examine the general condition of hair according to the prevalence of any identified diseases, disorders and traumas, hair treatments, sun bleaching, and the presence or damage caused by insects/arachnids or fungus [7, 8, 9, 10, 17].

Permission to obtain a single strand of hair per head was obtained. These were taken directly from the scalp, using sterile tweezers and sharp scissors. Each strand was cut close to the root and placed into individually labeled, transparent resealable bags for safety and to avoid cross contamination. Longitudinal samples were prepared following protocols established by SWGMAT [18]. Where anomalies were identified, a section of hair (an inch minimum), was cut from the samples using sterile scissors. Tweezers positioned the hair on a glass slide. Samples were mounted using Styrolite™ [19]. All hair samples were viewed under a Leitz Wetlar® Orthoplan light microscope. In accordance with SWGMAT [18], the specimen field was illuminated with a low voltage tungsten filament lamp, and a colour correcting blue filter was used – ensuring samples were viewed in real colour. Relevant images were captured with Leica Application Suite software, using a DFC290 camera attached to the microscope.

#### 4. Results and Discussion

Using current standards to identify processing origins, only 9% (6) heads could be comfortably assigned as ceremonial *tsantsa*, with 56% (36) being defined as commercial shrunken heads. A total of 35% (23) heads were otherwise ambiguous in origin (Figure 1).

It was noted that commercial shrunken heads had the origin assigned with greater confidence than ceremonial *tsantsa*. This may be related to the fact that although some traders were faithful in replicating the techniques used by the SAAWC to shrink and finish heads, most were not [1, 20].



**Figure 1:** Distribution of ceremonial, commercial and ambiguous heads.

The nature of the curio market and its influence on tribal behaviour also challenges the conceptual integrity of all heads assigned as ceremonial items. It is understood that SAAWC communities, in response to foreign trading influences and demands, were shrinking heads for reasons other than traditional religious interests. Available reports state that headhunters were also being commissioned by outsiders to shrink heads or even full bodies to bespoke requests, and possibly apply more decorative materials [1, 2, 3]. Therefore 35% (23) heads were defined as ambiguous for two fundamental reasons:

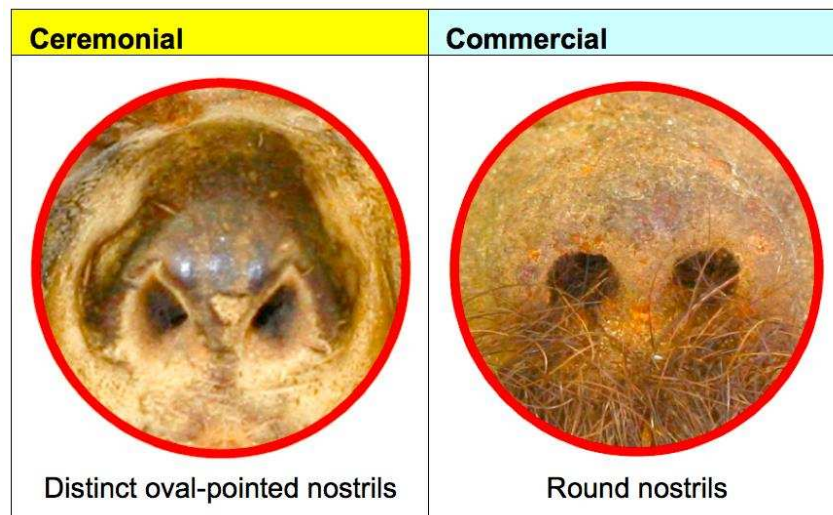
- a) 31% of specimens appear ceremonial, but have atypical or ethnologically unreported materials attached (e.g. glass beads attached to earpieces). This implies that they were either produced commercially by a trader or a commissioned member of the SAAWC community, or were modified later.
- b) 12% of specimens appear ceremonial, but possess minor physical anomalies that would have occurred pre-desiccation (e.g. no evidence of an incision made for skull removal). This implies that a trader or a commissioned member of the SAAWC community most likely produced them for commercial purposes.

#### 4.1. Compression patterns

The original craniofacial structure collapses when the skull is removed from a head to enable shrinkage, thus manual manipulation is necessary to remodel the head shape. Ceremonial *tsantsa* can be characterised as having a long narrow face, sloping brow, an upturned and spread nose, with distended lips creating a receding chin and an elongated profile. Crucially during desiccation a shrunken head is hot, and the SAAWC used palm leaves to protect their hands. This often resulted in a strong depression being made from grasping the head at each temple, producing a laterally compressed and narrow forehead [1, 2, 21]. The analysis found that, consistent with previous findings, temple compressions affected 83% of ceremonial *tsantsa* and 83% ambiguous heads. In addition to previous reports [1, 2, 21], there were regular compressions that affected the lateral borders of the posterior head in 83% of ceremonial *tsantsa*, and 52% ambiguous heads. These type of compressions may have previously gone unidentified due to it being largely disguised by the scalp hair. Minor compressions were also typically identified across the cheeks or gonial regions.

In the ceremonial and ambiguous heads, the noses appeared spread and unnaturally upturned (close to a 90° angle), giving the nostrils more prominence and forcing the nasal bridge into a near horizontal angle. The nostrils exhibited distinct superiorly directed points and often marks resembling fingernail impressions across the alae and tip were detected, presumably from applied manual manipulation (Figure 2, *left*). This is in

contrast to the commercial specimens, where only 43% heads presented only subtle pointing, with the rest maintaining a softer round or sometimes oval shaped nostrils (Figure 2, *right*).



**Figure 2:** Variation in nostril form – classically pointed nostrils of ceremonial *tsantsa* and typically rounded form of commercial heads

Commercial heads were more refined, with a more convincingly proportioned face and an upright profile, due to the use of gloves by the practitioners. The scalp structure varied from a rounded to domed shape. It was rare, but heads sometimes presented a distinct dome with posteriorly placed ears, due to a section of skin being removed from the scalp to further reduce the overall head size. There were often no, or limited, compressions distorting the surface. Compressions unique to this category included:

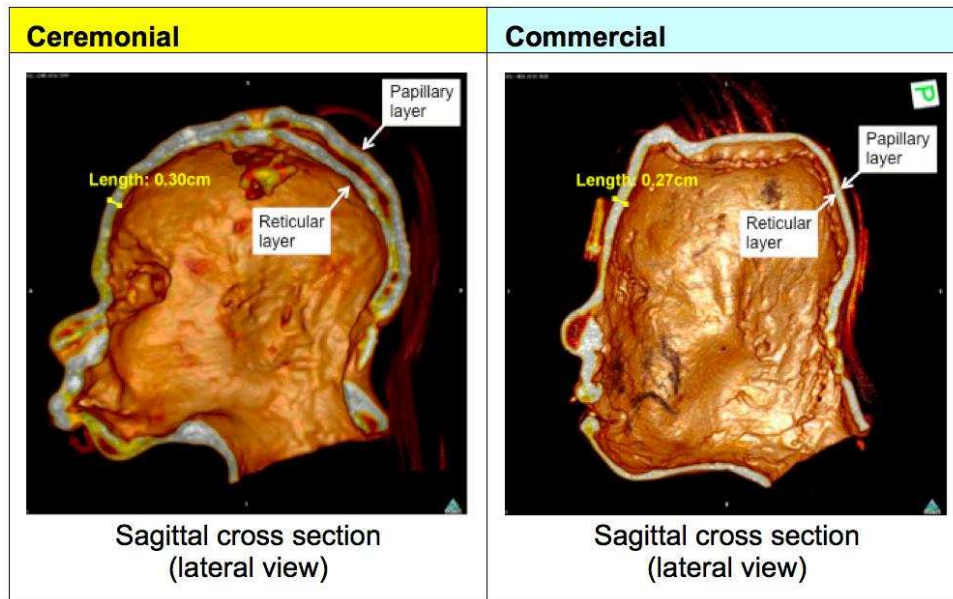
- 22% with a marked pinching of the nose, which forcefully caused it to narrow and project to produce a more prominent profile – possibly from how the head was supported during desiccation or a product of Eurocentric design (nasal shape is purposely modelled to be more akin to Caucasoid type noses, rather than other ancestry groups).
- 6% with a transverse compression lining the forehead, likely from how it was held during desiccation, causing the brow ridge to boss.

#### 4.2. Internal skin structure

An inspection of the deeper dermal tissues, viewed in cross-section, could only be performed via CT – a more detailed examination may however have been yielded by means of histological investigation (invasive) or micro-CT analysis (minimally-invasive). Sample size was limited and ideally all 65 heads would have undergone CT analysis to further substantiate results. Upon viewing the scan, the dermal structure is the outer shell highlighted in white. A detachment in the papillary and reticular layer of the dermis was however evident when the white skin structure is seen to divide, revealing a dark red void. This is a symptom best recognised and researched by the leather industry, and is formerly referred to as ‘double hiding’ [22, 23]. This feature was predominant in ceremonial (100%) and ambiguous (67%, with minor ‘double hiding’ presenting in 33%) specimens, where it is likely that stress had been placed on the skin to compress and distort its features by heavy handling and remodeling (Figure 3, *left*). The commercial heads were generally more refined in their



morphological appearance, thus better conserving the dermal structure (67% had minor signs of 'double hiding', 33% had none) (Figure 3, *right*).



**Figure 3:** CT of a ceremonial *tsantsa* depicting the junctional splitting of the papillary and reticular layer (*left*), CT of a commercial head void of junctional splitting (*right*).

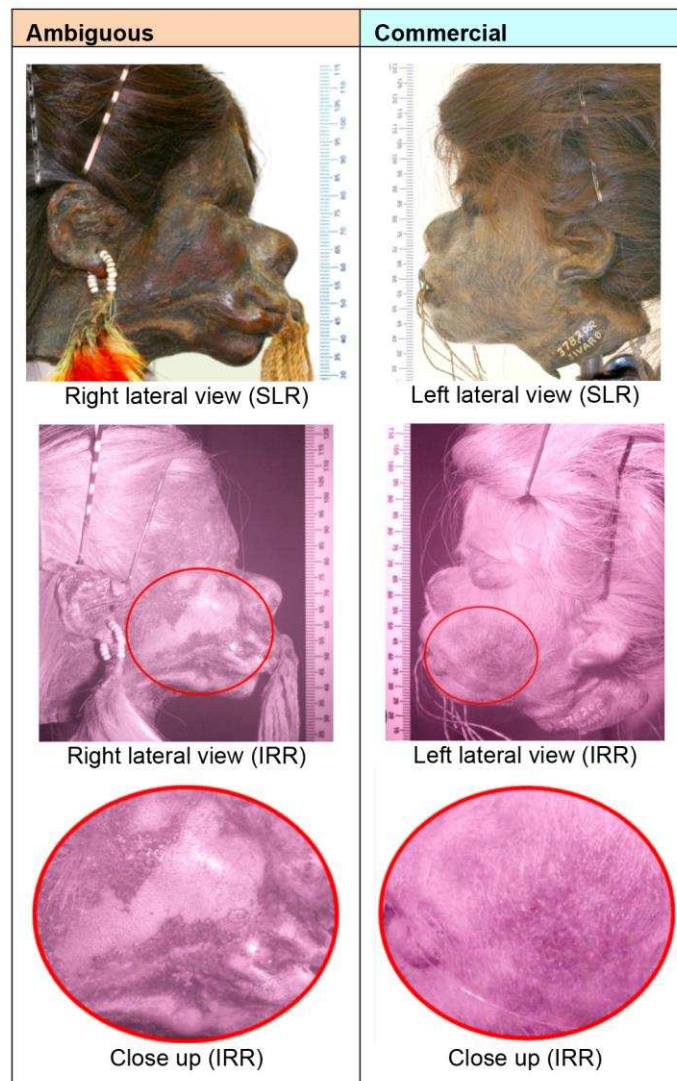
Double hiding can result from an imbalance of chemical and mechanical stress acting upon the dermal tissues [23]. During the desiccation of a shrunken head, heat is applied separately to the exposed superficial surface of the epidermis (or external papillary layer, if and when the epidermis has deteriorated) and internal reticular layer of the dermis. The heat then permeates through to the central dermal junction. An intense and rapid heat application may result in the collagen borders dehydrating and shrinking much faster than at the junction, allowing moisture to become trapped. Hydrolysis may then occur, turning the junctional fibres of the dermis into gelatin [23]. The result is a structural weakness that can cause the papillary layer to detach from the reticular layer, which would be promoted by continual agitation and manipulation of the tissues when handling. Separation is thus emphasized where the skin is forced to distinctly arch out of normal alignment, between the points of compression on the head.

### 4.3. External skin structure

The contraction of facial tissues, results in the compaction and shortening of hair follicles into a smaller surface area, thus causing all hair to appear denser and longer than in life [24]. This includes the fine, peach-white hypopigmented, nonmedullated vellus hairs that ordinarily cover most of the body and constitute facial down. The facial skin presents a remarkably elevated concentration of follicles in the postcranial anatomy, especially across the nose [25, 26, 27]. In living subjects, only 2-3mm of the vellus hair is exposed on the skin surface [28]. Following shrinkage, this hair becomes more obvious if not removed. The longest downy hair identified in this research measured approximately 8mm in length.

Consistent in all ceremonial and ambiguous specimens, and identified in only 31% of the commercial heads, is the removal of facial down to reveal a smooth, refined and more polished skin texture. Any surviving downy hairs often being identified in inaccessible, tightly creased regions of the skin. Using IRR, a fluctuation

in the epidermis was frequently presented across the facial skin, which correlated with the pattern in removal of downy hair (Figure 4, *left*). Flat, less resistant surfaces across more prominent regions of the face appeared to have the epidermis removed. These regions would have been well suited to prolonged heat treatment and friction from the likes of a hot pebble, traditionally used to cure a shrunken head and rid it of facial down. Less significant regions of the head, primarily the neck, and hard to reach areas where the skin folds, alternatively had the remains of a blistered epidermis retained and possible evidence of downy hair. This was with exception to 14% commercial heads and 4% ambiguous heads, where the full epidermis was successfully removed. To achieve this finish, it is possible that a finer heat-bearing implement was used to access tighter regions of the face.



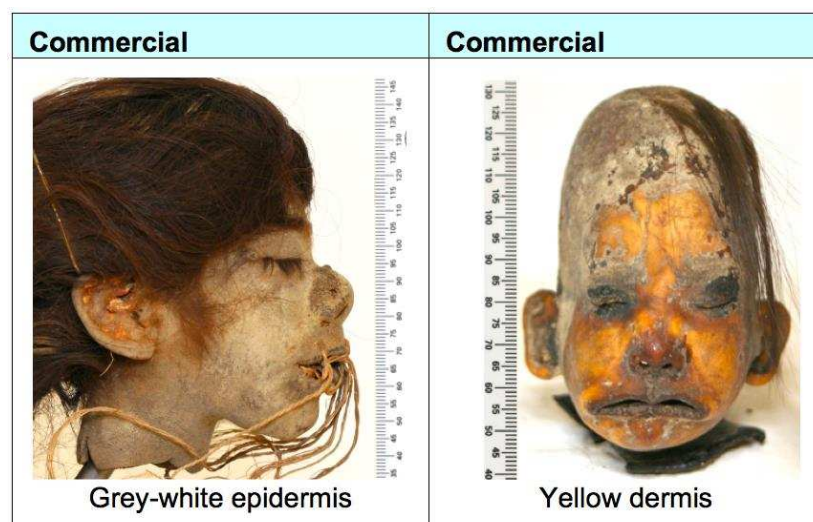
**Figure 4:** Commercial head with retained epidermis and facial down (*left*). Ceremonially styled ambiguous head, with actively removed facial down and alternating regions of epidermal degeneration across the face (*right*).

The cause for epidermal degeneration is estimated to be a result of direct heat application to the superficial skin during desiccation. This would be expected of ceremonial tsantsa, where a hot flat-edged pebble was classically employed to iron the superficial skin and remove facial down. The applied heat would have penetrated the tissue surface, intensifying when it contacts and melts the natural oils that have a low melting capacity, promoting thermal damage to the skin. These oils subsequently ooze from the facial pores to provide a smooth, slippery surface, ideal for gliding a hot implement over to continually iron the facial skin. The temperature and time duration that heat was applied, would introduce a variable for the extent of protein

denaturation, cell damage, and surface contraction that occurred. This appears to have often resulted in not only the removal of hair, but also the blistering and flaking of the thinner and weaker epidermal layer, aggravated by the physical abrasion from the heat-bearing implement used.

Significant to 64% of commercial heads, was the near complete preservation of the epidermis (minor degeneration being evident where fungal activity was present), which correlated with a comparatively dull and unkempt surface finish. This implies that direct heat treatment was either not applied to the face or very weakly applied at a low temperature and/or for only a limited time period, to create minimal or no impact (Figure 4, right). Among these, only 17% of heads appeared to retain full facial down. Most otherwise presented a coarse felt texture, where the downy hair appears to have been trimmed or shaved to reveal the skin. In 8% of the commercial heads, an epidermis was retained, but no evidence of downy hair was presented. This was presumably a consequence of wear and tear, possibly from frequent handling and bacterial activity, or the result of more careful facial down removal techniques using heat.

It is expected that ceremonial *tsantsa* were stained a dark brown to mahogany colour using powdered carbon (e.g. Figure 4, left), while commercial heads sometimes failed to have this performed and so retained their more natural colour (Figure 5).



**Figure 5:** Naturally coloured commercial heads.

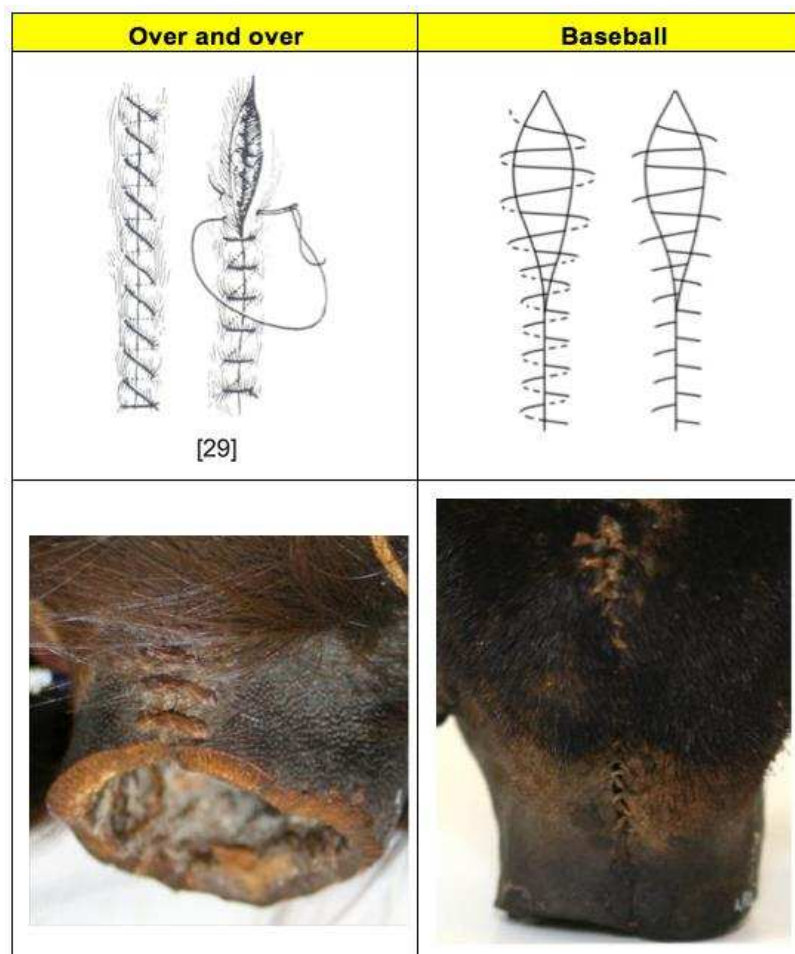
It was evident that areas where the epidermis was present, often displayed a deeper, darker colouring to those where it had been lost. Epidermal degeneration likely occurred in the event of heat treatment at desiccation, not following it. The deeper colouring of the epidermis in contrast to the dermal tissues implies it has had the most prolonged exposure to carbon and also suggests that these tissues were possibly coloured during the desiccation phase when the epidermis was actively worn away, not following – otherwise a more consistent colouring would be expected. Alternatively, the epidermis is a comparatively weaker structure when compared with the dense interwoven collagen fibres of the dermis, possibly making it a more susceptible surface for colour absorption [23]. Negating this theory however are two ambiguous specimens, which have achieved a considerable deep dark brown colouring across both the epidermis and dermis. This would likely be related to a more intensified exposure to carbon possibly during or following desiccation. To understand the influences of carbon staining upon the epidermis and dermis and attempt to overcome the conflicts in

anthropological recordings, regarding when the colourant was applied, the influences of during or post-desiccation staining should be tested. This would ideally be performed on hairless mammalian, preferably human, skins.

Unstained or weakly stained skins, exposing the natural colours of a shrunken head, were evident in only 14% of the commercial heads. It is possible that with time, the quality of stains may also reduce due to the effects of light exposure and general wear and tear from repeated handling [2]. With reference to the IRR findings on epidermal degeneration, it is evident that the epidermis is naturally a grey-white colour (Figure 5, *left*). Its dull colour can be attributed to its removal from a living blood circulation, and possibly to a breakdown in chromophore pigment levels of any retained melanin during heat treatment. Distinct fungal activity was evident and therefore a likely influence on colour. The exposed papillary layer of the dermis was yellow (Figure 5, *right*). Destroying the epidermis consequently resulted in the loss of melanin that coloured the skin in life. This is the first time an explanation has been given with regard to the natural colouring of a shrunken head. Previous reports have only acknowledged that unstained heads can range from grey-white or yellow in colour [2].

#### 4.4. Sutures

Sutures were classically employed to fasten incisions made for assisting skull removal. Documented for the first time is that suturing techniques vary between 'over and over' sutures and 'baseball' sutures (Figure 6).



**Figure 6:** Examples of 'over and over' and 'baseball' sutures [29].

An 'over and over' suture is the simplest to perform. This was evident in all ceremonial *tsantsa*, 74% ambiguous heads and only 22% commercial heads.

The 'baseball' stitch is a more secure method, understood to create a flatter and more discreet suture [30]. This was evident in 72% of commercial heads and only 13% of ambiguous heads.

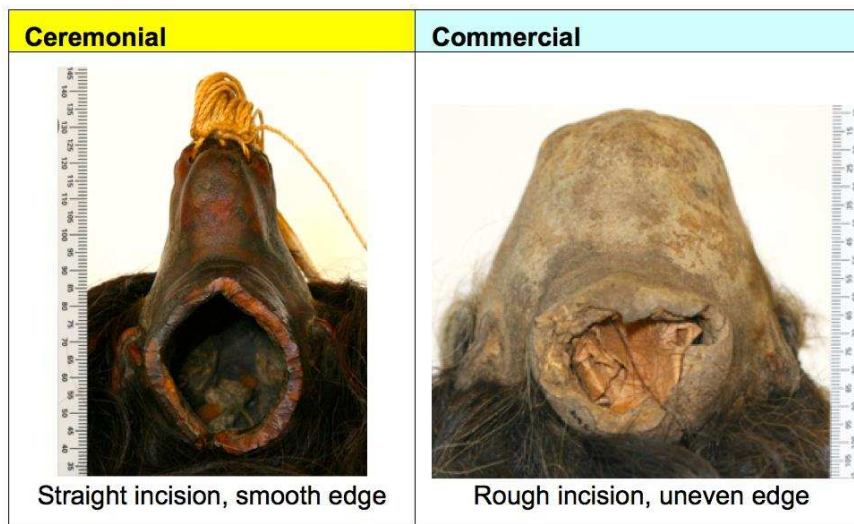
The difference in suture technique is likely related to the contrasting influence of tribal or medical training. The 'over and over' suture, though effective, is a more rudimentary stitch that would have been most amenable for the SAAWC or any other craftsmen. The 'baseball' stitch is a more intricate suture. This suturing method is most frequently used to repair hides in taxidermy, in autopsies to close the chest cavity and scalp following investigation, and for closing the uterus in a classic cesarean section surgical procedure [30]. Taxidermists, third world doctors, and mortuary technicians, were the most common of Euro-colonials to conduct head shrinking for trade purposes [1, 2, 3, 13]. It appears likely that the baseball stitch may act as a hallmark of a commercial head.

#### **4.5. Neck preservation**

Consistent with previous anthropological reports [1, 2, 3, 11], evidence of a supportive neck ring structure applied to the base of the neck was maintained in most ceremonial *tsantsa* (83%) and seldom in commercial heads (8%) – this would have been implemented to support the neck in an open position, allowing the processor access to the internal head to apply hot pebbles and later sand to promote desiccation. Common ceremonial evidence included small pinhole perforations or grooves lining the neck base. More ambiguous evidence were the intermittent pin-sized tears that lined the edge of two commercial necks, implying that a supportive ring was ripped away from the skin before desiccation had been completed. Unique to two ambiguous specimens are that the supportive ring did not circle the neck, but instead the lower jaw region, with no evident incision line for skull removal visible. The unusual nature of this feature may indicate the heads as being commissioned or commercial.

A straight and consistent incision was performed on the neck of all but 31% of commercial specimens. In all ceremonial *tsantsa*, 91% ambiguous heads, and only 36% of commercial heads, the base of the neck was presented flush, with minor buckling evident in those specimens where the incision had been made close to where a neck ring was likely once applied (Figure 7, *left*). These necks were likely cut post-desiccation to remove the then redundant neck ring if applied and produce an aesthetic quality finish.

The remaining 47% of commercial specimens presented an uneven and buckled edge with 14% also showing an irregular and ragged incision (Figure 7, *right*). In 9% of ambiguous specimens, a concertinaed edge was visible, but there was clear evidence of a neck ring fitting that was positioned close to the jaw line, thus reducing the possible surface area for extra cutting and refinement. The incisions in all these specimens were therefore not refined post-desiccation and were likely performed pre-desiccation.



**Figure 7:** Variation in neck quality – ceremonial neck cut post-desiccation and commercial neck maintaining original pre-desiccation, decapitation incision.

The handling employed during desiccation influences neck shape. Necks were often rounded, likely aided by the use of a neck ring, with exception to 9% ambiguous heads and 33% commercial heads. In the ambiguous heads, evidence of a neck ring was present, but an anterior pinching of the lateral borders resulted in a triangular neck form. Greatest variation was witnessed in the commercial category. Subtle differences include 11% with a gently flayed edge to the rounded neck design – this may have been done to support necklace adornments, as witnessed in 19% commercial heads. 11% had a neck moulded into a bilateral oval. More obvious differences include 6% of necks that were cut crudely and allowed to contract so that no particularly identifiable shape was made. Another 6% of necks had been more carefully tailored to fold out and form a freestanding base – it is possible that at the time of decapitation, the initial incision made would have been across the shoulders to allow for more available skin to conduct this alteration.

In 83% of commercial heads, no evidence of a suspension cord is indicated. Their display thus depends on a self-supporting design or a supplementary stand. Those without skins made into a freestanding base, could have been adhered once onto the likes of a halved gourd shell platform, as identified in one such example. Adhesive materials included a transparent resin identified in only 6% specimens and pitch was found to line the neck's opening in 28% heads and plug the neck orifice of 11% – the act of blocking the orifice may however have been done to simply conceal the opening than secure it to a platform. The dark colouring of pitch was ideal as it blended well with that of the carbon stained skin.

#### 4.6. Preservation and conservation material application

Pitch was seemingly identified to preserve, conserve, disguise damage, and improve the aesthetic finish of heads. 67% of ceremonial *tsantsa* used this to secure toucan feather pendants to ear dangles, and in one case to fill a disused secondary suspension cord perforation at the crown of the head. In 58% commercial heads and 52% ambiguous heads, pitch was used more eclectically (e.g. to disguise damage and incisions, plug orifices, coat the eyelids and attach miscellaneous ornaments directly onto the skin). Notably due to the properties of pitch as a waterproof substance that can also inhibit microbial activity owing to the terpenoids it comprises, the use of pitch can evidently be acquainted to many different cultures, in different regions of the

world, in various historic contexts [31, 32]. Varnish coated the skin in only one ambiguous head. This was likely to promote long-term preservation, improve hygiene, and arguably enhance the aesthetic appearance of mummified remains [33]. Red pitch was also applied to protect and conceal damage in only one ambiguous head. Cotton (28% commercial heads and 13% ambiguous heads) and paper materials (11% commercial heads and 4% ambiguous heads) were sometimes applied to cushion and fill the head's cavity.

Foreign materials could have easily been applied by a secondary body and are not necessarily appropriate evidence of a head coming from either ceremonial or commercial origins. In most cases, museum conservators, traders and private collectors, likely applied the various materials. It is however possible that the SAAWC solely used pitch on ear pendants or to fill a secondary suspension cord perforation in ceremonial *tsantsa*.

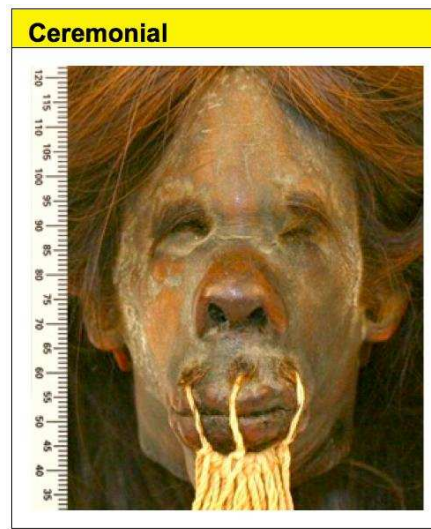
#### **4.7 Hair condition**

All ceremonial *tsantsa* and ambiguous heads present a distinctive long hairstyle, predominantly cut into three level tiers – influencing the fringe, temples and posterior scalp hair. This style is consistent with SAAWC fashions [1, 3].

Commercial heads tended to present particularly short or long hair, with no consistent styling performed – one commercial head had however falsely applied hair to create a more hairy scalp texture. These heads were likely taken from a populous residing in the more cosmopolitan towns, where fashions would be more varied.

Facial hair is notably uncommon across the collection. Moustaches or beards were extremely rare among the indigenous population of South America. This population present a sparse growth and development of facial and body hair, and most Indian groups also perceived this hair as ugly and were likely to remove any [34]. In contrast, Whiffen [35] often observed the prevalence of facial and body hair growth being a fundamental quality, significantly for those entering into and practicing shamanism across much of the North-West Amazonas (potentially including the SAAWC, although this is not stated).

In the ceremonial *tsantsa* and closely ceremonial resembling ambiguous heads, all or most being likely produced from SAAWC or other indigenous victims, facial hair was rare. Moustache hair was however present in one ceremonial *tsantsa* and four ambiguous heads. These may have been shamanistic bodies from enemy communities, if not outsiders to traditional indigenous cultures. The moustaches were consistently cropped short and intermittent in pattern (e.g. Figure 8). The hot stone applied to iron and cure the outer skin during desiccation, and singe away the soft facial down, was presumably hot enough to burn and shorten the moustache hair to its given length – evidence included a few intermittent hairs presenting round vacuoles at the ends. The chonta pins, which fastened the mouth during shrinkage and desiccation, would have obstructed access to the full upper lip. This explains the confined circles of hair that remains surrounding the mouth's perforations. It is thus possible that the removal of facial hair, as with facial down, was intentionally practiced by the SAAWC. The purpose, whether it be for aesthetics or superstition, are uncertain.




**Figure 8:** Intermittent moustache hair surrounds pin perforations about the mouth of a ceremonial *tsantsa*.

Comparatively, facial hair would have been more fashionable among the colonial or colonised townspeople, and presented in 28% of commercial heads likely produced from such subjects. Styles included sideburns, moustaches, soul patches and full beards. The hair had a more defined presence than the ceremonial type specimens, with post-mortem shrinkage causing the hair to appear long, untamed and bushy, unless combed and trimmed.

The condition and pathologies presenting in hair may indicate the environment specimens existed or the type of handling incurred. It is however not possible to determine if conditions such as sun bleaching, fungal infections (from *Phaeoophomycosis*) or fractures (*Trichorrhaxis nodosa* and *Central trichoptilosis*) in the hair shaft are ante-mortem or post-mortem. Evident cases of *Pediculosis humanis capitis De Geer* and hair casts are however only acquired on living subjects, due to a dependence on a living blood supply and active hair growth [36, 37].

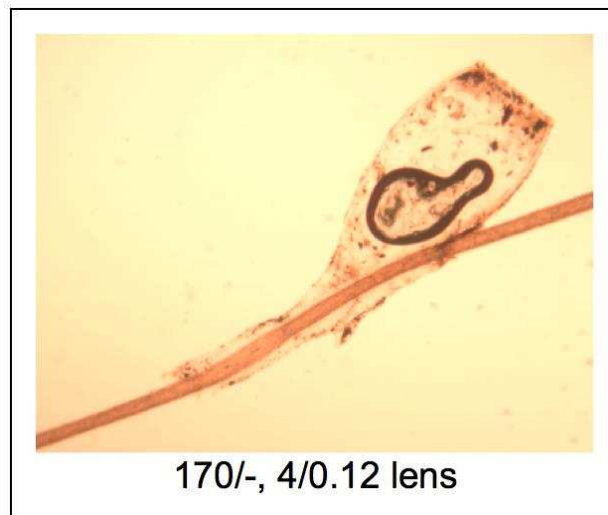
Sun bleaching predominantly affected 67% of ceremonial *tsantsa* (in contrast to 42% commercial heads and 48% ambiguous heads), creating a contrasting colour difference between underlying and superficial hairs. All affected hairs were positioned towards the head's vertex – the point most exposed to direct sunlight when an individual is postured in an upright position. These heads would have in life and possibly death, been exposed to the outdoors and intensive sunlight for extensive periods of time.



**Figure 9:** Microscopic view of a hair shaft colonised by black piedra.



Rare, but significant to 17% of ceremonial *tsantsa*, and 13% of ambiguous heads that closely align with ceremonial appearance, was the presence of black piedra (*Trichomyces nodularis*). This forms irregular dark brown-black nodules that colonise the hair shaft (Figure 9). The nodules consist of ascostromata, the hyphae and fruiting bodies of the fungus, from which fungal spores are released. It is an infection typically affecting scalp hair and is often asymptomatic. In severe cases it may cause the hair shaft to become brittle and break. Black piedra is caused by the dematiaceous filamentous fungus *pedraia hortae* – identified in soil and common in tropical areas, especially the rainforests of Malaysia and the Amazon of South America [38, 39, 40]. Black piedra thus signifies individuals that may have lived or were maintained in death, in the Amazon rainforest – this most likely being the SAAWC populous.



**Figure 10:** Microscopic view of a *Pediculus humanis capitis* De Geer nit.

*Pediculus humanis capitis* De Geer, in the form of nits (Figure 10), were predominantly and more profusely identified in 33% of commercial specimens, with minor intrusions only evident in 9% ambiguous heads. De Souza *et al.* [17] noticed a similar pattern when assessing five shrunken heads held by The National Museum, Rio de Janeiro, Brazil. Two heads were commercial with evidence of profuse nit infestation, two were ceremonial with no or few nits, and the fifth was not human. In agreement with de Souza *et al.* [17], the difference is likely related to the living condition in which the victims once existed. The ceremonial heads would have been taken from indigenous SAAWC peoples, who were preoccupied with grooming and existed in a spacious, open environment. Commercial specimens would have presumably come from those who survived in poor slum settlements, where overcrowding and the rapid spread of infestation and disease were common [17, 41. 42].

Evidence of possible disease, disorders or trauma was uncommon. Fractures in the hair shaft were however identified in 6% of commercial heads and were possibly the result of stressed styles, excessive combing, intensive heat exposure, or congenital disorders. Only 4% of ambiguous heads also presented hair casts, which can form in conjunction with various fungal skin infections or persistent and regular traction of the hair.

## 5. Conclusion

A total of 65% shrunken heads were classified confidently by origin. 56% were commercial, demonstrating the popularity of shrunken head manufacture among traders. Only 9% were defined as ceremonial *tsantsa*. The remaining 35% heads presented some ambiguity and could not be classified with any degree of confidence. This was predominantly due to atypical superficial applications applied post-desiccation, and sometimes physical anomalies that were incurred pre-desiccation.

It is challenging to confirm heads as ceremonial *tsantsa*. Traders sometimes produced commercial heads to closely resemble ceremonial *tsantsa*. The concept of all SAAWC *tsantsa*, being defined as ‘ceremonial,’ may also be debated. The popular business of exchanging a head for a gun, or other European material, meant SAAWC head-hunters sometimes became removed from the ceremonial intentions of head shrinking to focus purely on expanding profits. The SAAWC were also open to commissions, encouraging the production of atypical ceremonial *tsantsa* for western markets [1, 2, 3].

According to the detailed assessment performed on the defined ceremonial and commercial specimens, a series of new distinguishing features have been identified. These are stated in Table 2. In addition to current findings, it is evident that unstained skins also present as a yellow colour when the dermis is exposed, and a grey-white when the epidermis is retained. This has previously gone unidentified.

**Table 2:** New distinguishing features, and how they contrast, for ceremonial *tsantsa* and commercial shrunken heads.

Ceremonial <i>tsantsa</i>	Commercial shrunken head
1. Long narrow face, sloping brow, upturned & spread nose, with distended lips creating a receding chin and an elongated profile. Distinct compressions at the temples and lateral margins of the posterior head.	1. More convincingly proportioned face and an upright profile. Rounded to domed shaped scalp.
2. Superiorly pointed nostrils.	2. Nostrils retain a more naturally rounded shape.
3. Separation of the papillary and reticular layer of the dermis.	3. Minimal to no division of the papillary and reticular layer of the dermis.
4. Epidermal degeneration across prominent regions of the face.	4. The epidermis retained.
5. Removal of facial down.	5. Facial down shaved, creating a stubble texture.
6. ‘Over and over’ sutures.	6. A variety of suture techniques. ‘Baseball’ sutures are most common.
7. Necks with supporting neck ring removed, demonstrating a smooth and even inferior edge at the opening.	7. No neck ring and an uneven or irregular neck base edge. The edging of the neck may be flayed or have pitch/resin applied.
8. Limited evidence of conservation and preservation materials.	8. A variety of materials for conservation and preservation.
9. Scalp hair resembling long hairstyle, predominantly cut into three level tiers – influencing the fringe, temples and posterior scalp hair.	9. No particular style.
9. If facial hair presents, active attempts at removing can be identifiable.	9. Full facial hair may be retained. Hair untamed and bushy.
10. Black piedra common on hairs.	10. Profuse nit infestations are common.

## **Authors' contributions**

The manuscript was written through contribution from all the authors, who have given approval to the final version of the manuscript. All authors read and approved the final manuscript.

## **Author details**

<sup>1</sup> School of Anatomical Sciences, University of the Witwatersrand, Medical School, Parktown 2193, Johannesburg, South Africa.

<sup>2</sup> Face Lab, Liverpool John Moores University, IC1 Liverpool Science Park, 131 Mount Pleasant, Liverpool, L3 5TF, United Kingdom.

## **Acknowledgements**

Many thanks to the Centre for Anatomy and Human Identification at the University of Dundee (UK), where the research was predominantly conducted. Gratitude is also paid to the Smithsonian Institute (Washington DC, USA), The Science Museum (London, UK) and Elgin Museum (Elgin, UK), for permitting access to their collections.

## **Compliance with ethical guidelines**

## **Competing interests**

The authors declare that they have no competing interests.

## **References**

1. M.W. Stirling, Historical and Ethnographical Material on the Jivaro Indians, Smithsonian Institution Bureau of American Ethnology: Bulletin 117, Washington: Government Printing Office, 1938.
2. J.L. Castner, Shrunken Heads. Feline Press, Gainesville, F.L. USA, 2002.
3. M.J. Harner, The Jivaro: People of the Sacred Waterfalls. Berkeley, Los Angeles, London: University of California Press, 1972.
4. R.A. Philippi, Menschenköpfe als Trophäen bei wilden Völkern, Globus, Band 1872, xxi, 340-3.
5. K.C. Duncan, 1001 Curious Things: Ye Olde Curiosity Shop and Native American Art, University of Washington Press (2001) 146–7.
6. C. Morgan, Object of the month: shrunken heads (real and fake), Wellcome Trust, <http://blog.wellcomecollection.org/2014/06/27/object-of-the-month-shrunken-heads-real-and-fake/>, accessed: 27 June 2014.
7. P. Charlier, I. Huynh-Charlier, L. Brun, C. Herve, G. Lorin de la Grandmaison, Shrunken head (tsantsa): A complete forensic analysis procedure, Forensic Science International (2012) 222:399.e1- 399.e5.

8. D. Hermon, R. Gafny, A. Zamir, L. Hadas, M. Faerman, G. Kahila Bar-Gal, The genetic signature of a shrunken head. *Archaeological Anthropological Sciences* 3 (2011) 223-8.
9. B. Reichenpader, W. Buzina, P. Roll, The Mystery of Shrinking Heads. *Journal of Forensic Science International Supplement Series 1* (2009) 22-23.
10. A. Sauvageau, C. Kremer, V. Brochu, F. Julien, S. Racette, Jivaro Tsantsas or Shrunken Head. An Expertise of Authenticity Evaluation. *The American Journal of Forensic Medicine and Pathology* 30 (1) (2009) 72-4.
11. R.W. Mann, B.B. Farmer, J.W. Verano, South American shrunken heads: Genuines and fakes, *Bioantropologia* 2, 8-13.
12. G.L. Mutter, Jivaro tsantsas, authentic and forged: a study of two shrunken heads in the Mutter Museum, *Transactions and Studies of the College of Physicians of Philadelphia* 43 (1975) 78–82.
13. H.N. Wardle, Description of a tsantsa in the ethnological collection of the academy, with notes on another specimen. *Academy of Natural Sciences* 66 (1) (1914) 197-205.
14. N. Lynnerup, Mummies, *Yearbook of Physical Anthropology* 50 (2007) 162-90.
15. M.A. Verhoff, C. Witzel, K. Kreutz, F. Ramsthaler, The ideal subject distance for passport pictures, *Forensic Science International* 178 (2008), 153-6.
16. Fujifilm, UV/IR Digital Camera Technology, Fujifilm corporation, 2007.
17. S.M.F.M. De Souza, M. Fátima, K. Reinhard, A. Araújo, The Jivaro shrunken heads from the National Museum, Rio de Janeiro, Brazil: Authentic of Counterfeits? In: V World Congress on Mummy Studies, 2005, Turin. *Journal of Biological Research. Turin : Societa Italiana di Biologia Experimentale LXXX* (2005) 129-131.
18. Forensic Science Communications (FSC), Forensic Human Hair Examination Guidelines: Scientific Working Group on Material Analysis (SWGMA), Forensic Science Communications, U.S. Department of Justice, Federal Bureau of Investigation 2 (3) (2005) 1-32.
19. G.M. Roe, R. Cook, C. North, An evaluation of mounts for use in forensic hair examination, *Journal of the Forensic Science Society* 31 (1) (1991) 59-65.
20. J.B. Ambrosetti, Las grandes hachas ceremoniales de la Patagonia. *Anales del Museo Argentino de Ciencias Naturales III* (1903) 45-51, Buenos Aires.
21. R. Karsten, The Headhunters of Western Amazonas, *Societas Scientiarum Fennica, Commentations Humanarum Litterarum*, VII, 1, Helsingfors – Centraltryckeriet, 1935.
22. M. Dempsey, Hide, Skin and Leather Defects: A Guide to their Microscopy, A Lasra Publication, New Zealand Leather and Shoe Research Association, Swiftcopy Centre Ltd, 1984.
23. J.J Tancous, Skin, Hides and Leather Defects, Leather industries of America laboratory, 1992.
24. R.C. Vreeman, A.E. Carroll, Medical Myths, *British Medical Journal* 335 (2007) 128.
25. U. Blume, J. Ferracin, M. Verschoore, J.M. Czernielewski, H. Schaefer, Physiology of the vellus hair follicle: Hair growth and sebum excretion, *British Journal of Dermatology* 124 (1991) 21-28.
26. N. Otberg, H. Richter, H. Schaefer, U. Blume-Peytavi, W. Sterry, J. Lademann, Variations of Hair Follicle Size and Distribution in Different Body Sites, *Journal of Investigative Dermatology* 122 (2004) 14-19.

27. A. Pagnoni, A.M. Kligman, S. El Gamma, T. Stoudemayer, Determination of density of follicles on various regions of the face by cyanoacrylate biopsy: correlation with sebum output, *British Journal of Dermatology* 131 (6) (1994) 862-5.
28. L. Rudnicka, A. Rakowski, M. Olszewska, M. Slowinska, J. Czuwara, M. Rusek, A.M.C. Pinheiro, *Atlas of Trichoscopy, Dermoscopy in Hair and Scalp Disease*, Springer-Verlag London, 2012, 11-46.
29. J. Kemble, *Surgery for Nurses*, Bristol, John Wright and sons Ltd, 1949, 106.
30. K. Edwards, B. Housekeeper, *Serious Sportsman Taxidermy for Beginners: Introduction to taxidermy and deer foot projects 1-9*, B. Publications, Inc. Pennsylvania State University, 1991.
31. N. Robinson, R.P. Evershed, W.J. Higgs, K. Jerman, G. Eglinton, Proof of a Pine Wood Origin for Pitch from Tudor (Mary Rose) and Etruscan Shipwrecks: Application of Analytical Organic Chemistry in Archaeology, *Analyst* 112 (1987) 637–644.
32. J. Jones, T.F.G. Higham, R. Oldfield, T.P. O'Connor, S.A. Buckley, Evidence for Prehistoric Origins of Egyptian Mummification in Late Neolithic Burials, *PLoS ONE* 9 (8) (2014) e103608.
33. P. Carminati, A. Begeerock, H. Gill-Ferking, Surface Treatment of Mummies: Mummification, Conservation or Beatification, *Yearbook of Mummy Studies* 2 (2014) 159-66.
34. R. Karsten, *The Civilization of the South American Indians*, London: Kegan Paul, Trench, Turner and Co., Ltd, 1926.
35. T.W. Whiffen, *The North West Amazons*, London: Constable and Company Ltd, 1915.
36. B. Arriaza, N.C. Orellana, H.S. Barbosa, R.F.S. Menna-Barreto, A. Araújo, V. Standen, Severe head lice infestation in an Andean mummy of Arica, Chile, *International Journal of Parasitology* 98(2) (2012) 433-6.
37. S. Ahir, The Trichology Society: Pediculosis humanus, [www.hairscientists.org/head-lice](http://www.hairscientists.org/head-lice), accessed: 14 July 2014.
38. B. Adam, A.T. Soo-Hoo, K.C. Chong, Black piedra in West Malaysia, *Australian Journal of Dermatology* 18 (1977) 18:45-7.
39. G.S. De Hoog, J. Guarro, J. Gené, M.J. Figueras, *Atlas of Clinical Fungi*, CBS, Universitat Rovira i Virgili, 2005.
40. D. Larone, *Medically Important Fungi*, ASM Press, Washington DC, 1995.
41. D. Carrion, J. Vasconez, N. Bermudez, The case of Quito, Ecuador, *Centro de Investigaciones de Ciudad, Fernando Meneses #265 y Av. la Gasca, Quito, Ecuador* 1708-8311 (2005) 1-24.
42. A. Kern, J. Ritzen, Dying for change: Poor people's experience of health and ill health, *Sustainable Development and Healthy Environments*, 2005, World Health Organisation, [www.who.int/hdp/publications/dying\\_change.pdf](http://www.who.int/hdp/publications/dying_change.pdf), accessed: 14 July 2014.