



LJMU Research Online

Bulut, O, Liu, C-YJ, Koca, F and Wilkinson, C

Comparison of three-dimensional facial morphology between upright and supine positions employing three-dimensional scanner from live subjects

<http://researchonline.ljmu.ac.uk/id/eprint/7165/>

Article

Citation (please note it is advisable to refer to the publisher's version if you intend to cite from this work)

Bulut, O, Liu, C-YJ, Koca, F and Wilkinson, C (2017) Comparison of three-dimensional facial morphology between upright and supine positions employing three-dimensional scanner from live subjects. *Legal Medicine*, 27. pp. 32-37. ISSN 1344-6223

LJMU has developed [LJMU Research Online](#) for users to access the research output of the University more effectively. Copyright © and Moral Rights for the papers on this site are retained by the individual authors and/or other copyright owners. Users may download and/or print one copy of any article(s) in LJMU Research Online to facilitate their private study or for non-commercial research. You may not engage in further distribution of the material or use it for any profit-making activities or any commercial gain.

The version presented here may differ from the published version or from the version of the record. Please see the repository URL above for details on accessing the published version and note that access may require a subscription.

For more information please contact researchonline@ljmu.ac.uk

<http://researchonline.ljmu.ac.uk/>

Comparison of three-dimensional facial morphology between upright and supine positions employing three-dimensional scanner from live subjects

Ozgur Bulut^{a*}

Ching-Yiu Jessica Liu^b

Fatih Koca^c

Caroline Wilkinson^b

^a Department of Anthropology, Hitit University, Corum, Turkey

^b Face Lab, Liverpool John Moores University, Liverpool, United Kingdom

^c Department of Forensic Anthropology, Police Forensic Laboratory, Ankara, Turkey

* Corresponding author. Tel.: +90 5055430109.

E-mail address: ozgur.bulut@yahoo.com (O. Bulut).

Comparison of three-dimensional facial morphology between upright and supine positions employing three-dimensional scanner from live subjects

ABSTRACT

Facial soft tissue thicknesses (FSTT) measurements collected from Magnetic Resonance Imaging (MRI) and Computed Tomography (CT) imaging techniques are most commonly taken in the supine position for forensic craniofacial reconstruction. FSTT have been shown to be different in comparison to the upright position due to gravity. The variation of facial morphology between the upright and supine position of laser-scanned images taken from 44 individuals was investigated using volumetric analysis with deviation maps. Between 82.4%–86.7% of the facial surface area were within the error range of ± 2 mm between the supine and the upright position. This indicates that most anatomical landmarks taken from the MRI and CT data can be an accurate representative of the FSTT in the upright position. Seven landmarks located around the buccal region, masseteric region and the nasolabial region of the face showed the greatest FSTT deviation between the upright and supine position, thus these landmarks may affect the accuracy of facial reconstructions when using a CT or MRI database.

Keywords: Forensic Facial Reconstruction; Facial Soft Tissue Thickness; Facial Scan; Accuracy; Volumetric Analysis

1. Introduction

Forensic facial reconstructions such as the anthropometric (American) method [1], the combined (Manchester) method [2] and the automated methods [3] all require the use of average tissue thickness data taken from a related population. Studies have collected tissue thickness data from Magnetic Resonance Imaging (MRI) [4–6], Computed Tomography (CT) [7–11], Cone-Beam Computed Tomography (CBCT) [12,13], ultrasound [14–17], lateral radiographs [18–21] or from cadavers [22–24].

Some of these three-dimensional (3D) imaging techniques such as CT and MRI requires the subjects to be in the supine position, and the difference in soft tissue displacement due to gravity has been shown to be a false representation of the living in comparison to the upright position [17,25]. Some of these soft tissue thicknesses taken in the supine position are then applied to forensic facial reconstruction to create a likeness of an individual based on the skull. Tissue thickness differences resulted from gravitational factors may well affect the accuracy of a facial reconstruction.

A 3D facial shell can be created with many 3D imaging techniques such as CT scans, CBCT scans, laser scans etc. Volumetric analysis of the 3D face using shell deviation facial maps have been used in many studies to compare the difference in facial tissue thicknesses [25–31]. The facial shells can be superimposed with many commercially available ‘best-fit’ algorithms such as VAM [30], Geomagic Qualify [25], VRMesh [32] etc. In showing the shell-to-shell deviation, the area of differences can be displayed as a color map.

Surface examination or measurements of the face have also been used, where photographic images of the face between the upright and supine position were compared morphologically [30,33]. See et al. [30] compared measurements between

different anatomical landmarks of the face, and the authors assessed the angle and the shape of the facial contour, and also made observations relating to other changes to the facial soft tissues. Mally et al. [33] compared the anatomical facial features of the face using a grading scale to represent signs of aging. The method proposed by Mally et al. [33] was more subjective, but the study gave a clear overview on the volume changes of midface aging. Morphological assessments, as such, do not give information on the exact area or depth in tissue change, but with the use of high quality photographic images giving texture information, displacement on detailed facial features can be analyzed.

Lee et al. [25] and Wilkinson et al. [29] assessed the accuracy of facial reconstructions using shell-to-shell deviation maps as a method of volumetric analysis. Both studies compared the reconstructions to the original 3D face scans of the subjects. Wilkinson et al. [29] used CT scans comparison, although it was concluded that the reconstructions showed a good level of accuracy to the CT scans, this result may not represent recognition rate, as the authors are aware of the soft tissue distortions along with the difference in skin texture in comparison to a real face, these representation of faces may not be comparable to day-to-day facial recognition.

With the change in pose, FSTT differences can be observed around the masseter, cheek and mouth area [7,16,29]. De Greef et al. [34] compared the tissue thicknesses between CT (Supine) and ultrasound (Upright), where the greatest difference were shown around the gonion, supraglenoid and the occlusal line.

See et al. [30] and Iblher et al. [31] compared females of a young group to an older group and showed tissue depth displacement increases with age. Both studies suggested that facial soft tissue displacement of the lower face around the mouth and the gonial region was most prominent, but these changes in soft tissue are more

marked in the older group. Iblher et al. [31] also suggests that with the increase in elasticity and deformability, the old group showed a higher tissue mobility of the facial soft tissue, hence more displacement.

Forensic facial reconstruction prefers to use a FSTT database of the closest population in relation to the subject, but many available databases are from CT and MRI. By exploring the soft tissue changes between the supine and upright position, the differentiation of facial anatomical landmarks can be identify, thus can suggest the accuracy of certain landmarks when using a CT or MRI database. This study aims to analyze 3D facial morphology variation between upright and supine position and reach a conclusion as to which region of the face is modified with the change in pose. Specific anatomical facial landmark with the largest differentiation between the supine and upright position will be suggested, and these landmarks should be used with caution when applying database such as CT or MRI.

2. Materials and Methods

2.1. Acquisition and Preparation of Facial Scan Data

44 volunteers, between the ages of 22 and 49 years, were recruited from employees at the Police Forensic Laboratory in Ankara, Turkey. Among body mass index (BMI) categories (<20, 20–25, >25) as slender, normal and obese, only subjects who fell into the normal BMI category were included. All volunteers had no previous orthodontic treatments, facial plastic surgery or any facial deformities. Informed consents were obtained from all individuals.

The faces were scanned with the Fastscan Cobra 3D Laser scanner (Polhemus,

Colchester, USA). The subjects were scanned in the upright and supine positions to acquire 3D facial images. The 3D face scans were converted to .STL files by using Fastscan 4.0.7 (Polhemus, Colchester, USA), and then imported to GOM Inspect software, version 7.5 SR2 for Windows (Gesellschaft für Optische Messtechnik, Braunschweig, Germany). Unnecessary regions were cropped, and the required regions of the faces were saved for further analysis.

2.2. Alignment and Comparison Process

Volumetric analysis of the 3D face scans between the upright and supine positions were assessed using the 3D morphometric surface comparison option within the GOM Inspect software. The supine scans were first aligned to the upright position in GOM Inspect, and the upright scans were automatically aligned using the best-fit registration or the RPS (Reference Point System) registration method. This 3D inspection and mesh processing software provided several 3D work activities including automatic and best-fit pre-alignment, shape analysis of 3D point clouds and surface comparison of the 3D objects (Fig.1).

After alignment, the face shells between the two different poses were compared for analysis of deviation. GOM Inspect compared the surface morphology discrepancy between the shells. Each surface-to-surface comparison was set in the upright position as a reference. The software showed continuous colour maps of deviation for volumetric comparisons of the faces in the different poses.

A surface-to-surface deviation map may be computed and automatically produced within the software. From this continuous colour map, the general deviation of the face is clearly visible and can be easily understood. The results include the maximum

and minimum range of surface deviations with the average distance between the two surfaces (Fig.1).

3. Results

Surface-to-surface deviation maps for 44 comparisons between each paired face scan of the upright and supine positions were performed and the percentage of distributions for the deviations is presented in Table 1.

The discrepancies between the two surfaces were computed as the minimum limit of deviation error defined within ± 2 mm. In figure 1, the colors on the spectrum bars and the facial scans indicate the distribution of the errors: “green” represents the deviation within ± 2 mm; “yellow to red” between $+2$ to $+10$ mm; and “blue” between -2 to -6 mm. The areas of yellow and red implies that the scan of the supine position is more prominent than the scan of upright position, and the areas of the bluish color implies that the scan of supine position is less prominent than the scan of upright position.

The deviation map for the 44 subjects showed between 82.4%–86.7% of the facial surface area were within the error range of ± 2 mm between the supine and the upright position. When the error deviation was broadened to ± 5 mm, the deviation map increased to 95.2%–97.5%.

Subjects showed similar color deviation pattern, the tissue thickness difference between $+3$ and $+7$ mm shown as the yellow–orange–colored areas occurred around the buccal region. This tissues thickness difference extends into the posterior parotid-masseter region shown as the red-colored areas ($\geq +8$ and $\leq +10$ mm). This suggests that the scan in the supine position is more prominent. The area shown in light blue

color represents a tissue thickness difference of -3 to -5 mm, this area of differences is also similar across the subjects around the nasolabial region extending towards the mental eminence and the jowl. This suggests that the associated area is less prominent in comparison to the upright position.

32 of all subjects showed a slight difference in the deviation pattern around the nasolabial region, where the color difference was focused anterior to the nasolabial fold extending towards the jowl and not the mental eminence. Other subjects showed the tissue thickness differences to be posterior to the nasolabial fold. With the red-colored area indicating a tissue thickness difference around $\geq+8$ and $\leq+10$ mm, only 9 subjects showed an extended area towards the temporal region in comparison to other subjects, where the area is confined below the temporal region around the parotid-masseter area (Fig. 2).

Among 44 subjects, tissue thickness differences exceeding ± 2 mm ($<\pm 2$ to ± 10 mm) were between 14.6%–17.4% of the facial surface area. These areas were located around the buccal, masseteric and the nasolabial region. The differences suggest the greatest deviation in soft tissue thickness between the upright and supine poses. Using the soft tissue landmarks suggested by De Greef et al. [34] to define specific areas of the face, seven landmarks as inferior malar, supra canina, sub canina, supraglenoid, mid masseter, gonion, and occlusal line showed the greatest tissue thickness deviation over ± 2 mm (Fig. 3).

4. Discussion

Advances in 3D imaging techniques have allowed an objective assessment by comparing 3D surfaces. The GOM Inspect software has allowed a quantitative

assessment of the surface morphology discrepancy between the facial scans of upright and supine positions. The Fastscan Cobra 3D laser scanner has been reported to be a reliable tool with low inter-and intra-observer errors [35]. Although this laser scanning technique may create artifacts in scanning dark or reflective items such as hair, metal or items with a complex surface [36,37], this was not a problem since all subjects had minimal facial hair.

De Greef et al. [34] compared the supine and upright position of the FSTTs of 12 individuals. The exact figures were not given within their study, but the comparison between the CT (supine) and ultrasound (upright) tissue thickness data were shown in a graph as a median within the scale of +8mm and -4mm. This range is narrower in comparison to this current study with a tissue thickness range between +10mm and -6mm. This difference could have been caused by a difference in age, sex and population. The sample in De Greef et al. [34] was represented by 12 individuals (1M, 11F) with an average age of 19.7 and an average BMI of 19.5. As suggested by See et al. [30] and Iblher et al. [31] that facial soft tissue displacement increases with the effect of aging, this lower average age in comparison to the current study may explain the narrower range in tissue thickness changes.

De Greef et al. [34] also compared a CT shell to a 3D camera shell, and this may induce error from analyzing the deviation between shells obtained from different imaging methods. By using the same laser imaging method in comparing upright and supine position of the face, variables are minimized to focus on the differences caused by gravitational changes.

This study showed that a change in pose would have a difference between 2 to 10 mm on soft tissue thicknesses around the buccal region, masseteric region and the nasolabial region of the face. Studies have suggested that these area of tissue

thickness changes is related to gravity, and these specific area of tissue thickness differences could be caused by a difference in age, fat distribution, skin elasticity, muscle tone etc. [30,31,38].

The areas with the largest soft tissue deviation were found around the mouth, cheeks and the masseter region as defined to seven landmarks (inferior malar, supra canina, sub canina, supraglenoid, mid masseter, gonion and occlusal line), similar to previously published studies [7,29–31,34]. The greatest tissue thickness difference around the masseteric region is also consistent with the area of landmarks around the gonion, supraglenoid and the occlusal line [16,30,31].

Gierloff et al. [39] showed multiple subcutaneous fat compartments of the face with 9 virtual CT autopsies. With the effecting of aging, perhaps the higher tissue mobility may cause the displacement of fat pads more readily giving rise to the change in tissue thickness caused by gravity. The pattern in facial soft tissue displacement may be linked to the fat distribution compartments of the face.

5. Conclusion

This study presented the difference in 3D facial morphology between upright and supine positions. We performed an automated procedure for surface-to-surface comparison using 3D facial laser scans. With all 44 subjects from this study showing around 84% of the face being within ± 2 mm of error between the supine and upright 3D surfaces, these results suggest that previously published FSTT databases collected from CT or MRI are acceptable values within a minimal error range.

The selected seven facial anatomical landmarks showing the greatest variation in tissue thickness may be inaccurate to create a facial reconstruction of the subject

alive. In addition, further studies may require a larger 3D facial data to suggest a correctional factor when using FSTT data taken in the supine position. This may allow us to use accurate FSTT measurements and improve accuracy of forensic facial reconstructions in creating a closer representation of the subject alive.

References

1. K.T. Taylor, *Forensic art and illustration*, CRC Press, New York, 2010.
2. C. Wilkinson, *Forensic facial reconstruction*, Cambridge University Press, Cambridge, 2004.
3. D. Vandermeulen, P. Claes, G. Willems, J.G. Clement, P. Suetens, Automated facial reconstruction. In: C. Wilkinson, C. Rynn (Eds), *Craniofacial Identification*, Cambridge University Press, Cambridge, 2012, pp. 203–21.
4. D. Sahni, G. Singh, I. Jit, P. Singh, Facial soft tissue thickness in northwest Indian adults, *Forensic Sci Int.* 176 (2008) 137–46.
5. D. Sahni, I. Jit, M. Gupta, P. Singh, S. Suri, K. Sanjeev, Preliminary study on facial soft tissue thickness by magnetic resonance imaging in Northwest Indians, *Forensic Sci Commun.* 4 (2002) 1-7.
6. C.M.S. Fernandes, M. da Costa Serra, J.V.L. Da Silva, P. Yoshito Noritomi, F.D.A. de Sena Pereira, R.F.H. Melani, Tests of one Brazilian facial reconstruction method using three soft tissue depth sets and familiar assessors, *Forensic Sci Int.* 214 (2012) 211–e1.
7. D. Vandermeulen, P. Claes, D. Loeckx, S. De Greef, G. Willems, P. Suetens, Computerized craniofacial reconstruction using CT-derived implicit surface representations, *Forensic Sci Int.* 159 (2006) S164–S174.
8. D. Cavanagh, M. Steyn, Facial reconstruction: Soft tissue thickness values for South African black females, *Forensic Sci Int.* 216 (2011) 215–e1.
9. O. Bulut, S. Sipahioglu, B. Hekimoglu, Facial soft tissue thickness database for craniofacial reconstruction in the Turkish adult population, *Forensic Sci Int.* 242 (2014) 44–61.
10. P. Panenková, R. Beňuš, S. Masnicová, Z. Obertová, J. Grunt, Facial soft tissue thicknesses of the mid-face for Slovak population, *Forensic Sci Int.* 220 (2012) 293–e1.
11. O. Bulut, N.K. Altinbas, H.A. Unlu, I. Hizliol, T. Bora, M. Tiftik, In vivo facial soft tissue thickness measurements for Turkish Subadults, *Aust J Forensic Sci.* 47 (2015) 475-490.
12. H.S. Hwang, M.K.Park, W.J. Lee, J. H. Cho, B. K. Kim, C.M. Wilkinson, Facial soft tissue thickness database for craniofacial reconstruction in Korean adults, *J Forensic Sci.* 57 (2012) 1442–7.
13. N.A. Perlaza Ruiz, Facial soft tissue thickness of Colombian adults, *Forensic Sci Int.* 229 (2013) 160–e1.
14. I.H. El-Mehallawi, E.M. Soliman, Ultrasonic assessment of facial soft tissue thicknesses in adult Egyptians, *Forensic Sci Int.* 117 (2001) 99–107.

15. M.H. Manhein, G.A. Listi, R.E. Barsley, R. Musselman, N.E. Barrow, D.H. Ubelaker, In vivo facial tissue depth measurements for children and adults, *J Forensic Sci.* 45 (2000) 48–60.
16. S. De Greef, P. Claes, D. Vandermeulen, W. Mollemans, P. Suetens, G. Willems, Large-scale in-vivo Caucasian facial soft tissue thickness database for craniofacial reconstruction, *Forensic Sci Int.* 159 (2006) S126–S146.
17. C.M. Wilkinson, In vivo facial tissue depth measurements for white British children, *J Forensic Sci.* 47 (2002) 459–65.
18. H. Utsuno, T. Kageyama, T. Deguchi, Y. Umemura, M. Yoshino, H. Nakamura, et al., Facial soft tissue thickness in skeletal type I Japanese children, *Forensic Sci Int.* 172 (2007) 137–43.
19. H. Utsuno, T. Kageyama, K. Uchida, K. Kibayashi, Facial soft tissue thickness differences among three skeletal classes in Japanese population, *Forensic Sci Int.* 236 (2014) 175–80.
20. H. Utsuno, T. Kageyama, K. Uchida, M. Yoshino, H. Miyazawa, K. Inoue, Facial soft tissue thickness in Japanese children, *Forensic Sci Int.* 199 (2010) 109–e1.
21. H. Utsuno, T. Kageyama, T. Deguchi, M. Yoshino, H. Miyazawa, K. Inoue, Facial soft tissue thickness in Japanese female children, *Forensic Sci Int.* 152 (2005) 101–7.
22. M. Domaracki, C.N. Stephan, Facial Soft Tissue Thicknesses in Australian Adult Cadavers, *J Forensic Sci.* 51 (2006) 5–10.
23. N.H. De Almeida, E. Michel-Crosato, L.A.V. de Paiva, M.G.H. Biazevic, Facial soft tissue thickness in the Brazilian population: New reference data and anatomical landmarks, *Forensic Sci Int.* 231 (2013) 404–e1.
24. S. Codinha, Facial soft tissue thicknesses for the Portuguese adult population, *Forensic Sci Int.* 184 (2009) 80–e1.
25. W.J. Lee, C.M. Wilkinson, H.S. Hwang, An Accuracy Assessment of Forensic Computerized Facial Reconstruction Employing Cone-Beam Computed Tomography from Live Subjects, *J Forensic Sci.* 57 (2012) 318–27.
26. C.H. Kau, S. Richmond, A.I. Zhurov, J. Knox, I. Chestnutt, F. Hartles, et al., Reliability of measuring facial morphology with a 3-dimensional laser scanning system, *Am J Orthod Dentofacial Orthop.* 128 (2005) 424–30.
27. C. Wilkinson, A. Tillotson, Post-mortem prediction of facial appearance. In: C. Wilkinson, C. Rynn (Eds.), *Craniofacial Identification*, Cambridge University Press, Cambridge, 2012, pp. 166.
28. S. Richmond, A.I. Zhurov, A. Toma, Three-dimensional facial imaging. In: C. Wilkinson, C. Rynn (Eds.), *Craniofacial Identification*, Cambridge University Press, Cambridge, 2012, pp. 154–65.
29. C. Wilkinson, C. Rynn, H. Peters, M. Taister, C.H. Kau, S. Richmond, A blind accuracy assessment of computer-modeled forensic facial reconstruction using computed tomography data from live subjects, *Forensic Sci Med Pathol.* 2 (2006) 179–87.
30. M.S. See, C. Roberts, C. Nduka, Age-and gravity-related changes in facial morphology: 3-dimensional analysis of facial morphology in mother-daughter pairs, *J Oral Maxillofac Surg.* 66 (2008) 1410–6.
31. N. Iblher, E. Gladilin, B.G. Stark, Soft-tissue mobility of the lower face depending on positional changes and age: a three-dimensional morphometric surface analysis, *Plast Reconstr Surg.* 131 (2013) 372–81.

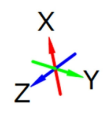
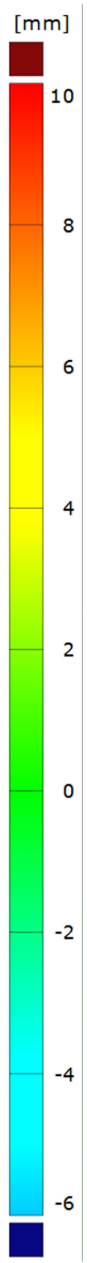




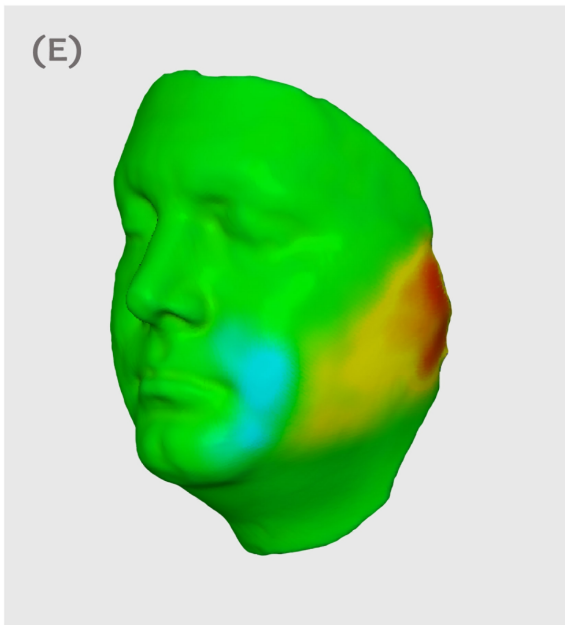
32. L.J. Short, B. Khambay, A. Ayoub, C. Erolin, C. Rynn, C. Wilkinson, Validation of a computer modelled forensic facial reconstruction technique using CT data from live subjects: A pilot study, *Forensic Sci Int.* 237 (2014) 147–e1.
33. P. Mally, C.N. Czyz, A.E. Wulc, The role of gravity in periorbital and midfacial aging, *Aesthet Surg J.* 34 (2014) 809–22.
34. S. De Greef, P. Claes, W. Mollemans, M. Loubele, D. Vandermeulen, P. Suetens, G. Willems, Semi-automated ultrasound facial soft tissue depth registration: method and validation, *Journal of Forensic Science*, 50 (2005) 1-7
35. H.K. Park, J.W. Chung, H.S. Kho, Use of hand-held laser scanning in the assessment of craniometry, *Forensic Sci Int.* 160 (2006) 200–6.
36. T. Houlton, Scanning the face of the McManus Tsanta, *Axis Online J CAHId.* 4 (2012) 1-20.
37. A. Tillotson, Could craniofacial analysis have a role to play in Disaster Victim Identification?, Dissertation, University of Dundee, Dundee, 2012.
38. S.R. Coleman, R. Grover, The anatomy of the aging face: volume loss and changes in 3-dimensional topography, *Aesthet Surg J.* 26 (2006) S4–S9.
39. M. Gierloff, C. Stöhring, T. Buder, J. Wiltfang, The subcutaneous fat compartments in relation to aesthetically important facial folds and rhytide, *J Plast Reconstr Aesthet Surg.* 65 (2012) 1292–7.

List of Figure Captions

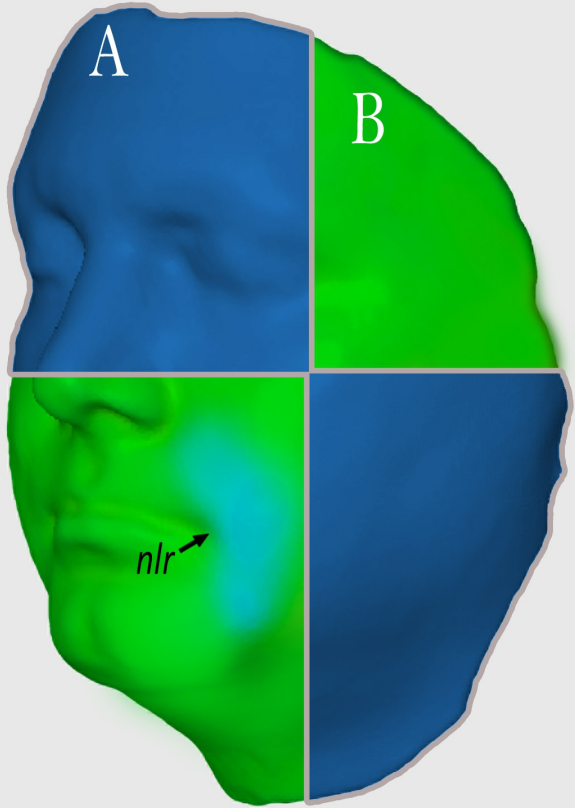
Fig. 1. Surface-to-surface color deviation map between supine and upright facial scans for 5 individuals of the sample (subjects A, B, C, D and E)

Fig. 2. Superimposed of upright and supine facial morphology and surface deviation patterns of image I and image II (A: Upright Facial Morphology, B: Supine Facial Morphology, *nlr*: nasolabial region, *pma*: parotid-masseter region)

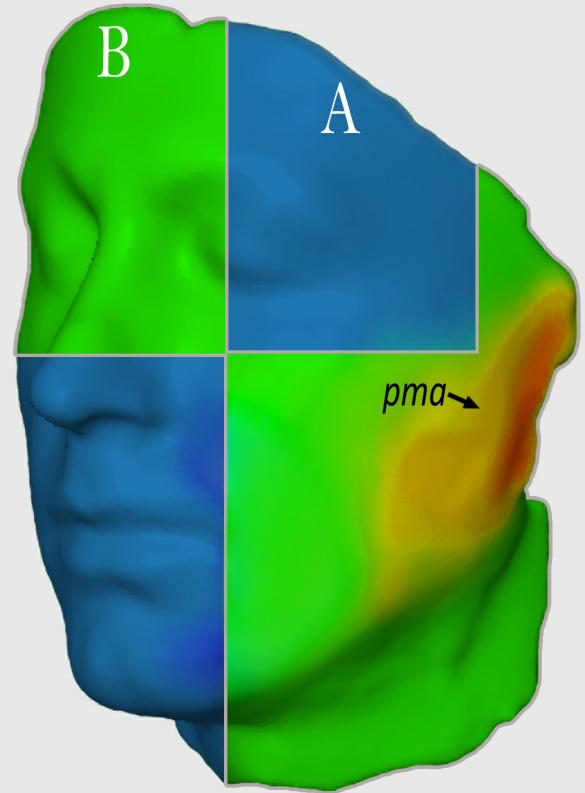
Fig. 3. Seven landmarks (1: inferior malar; 2: supra canina, 3:sub canina, 4: supraglenoid, 5: mid masseter, 6: occlusal line; 7: gonion,) showing the greatest tissue thickness deviation over $\pm 2\text{mm}$ (a: 3D skull with FSTT at landmarks; b: Superimposed of 3D skull and 3D reconstructed face with FSTT at landmarks)



I



II



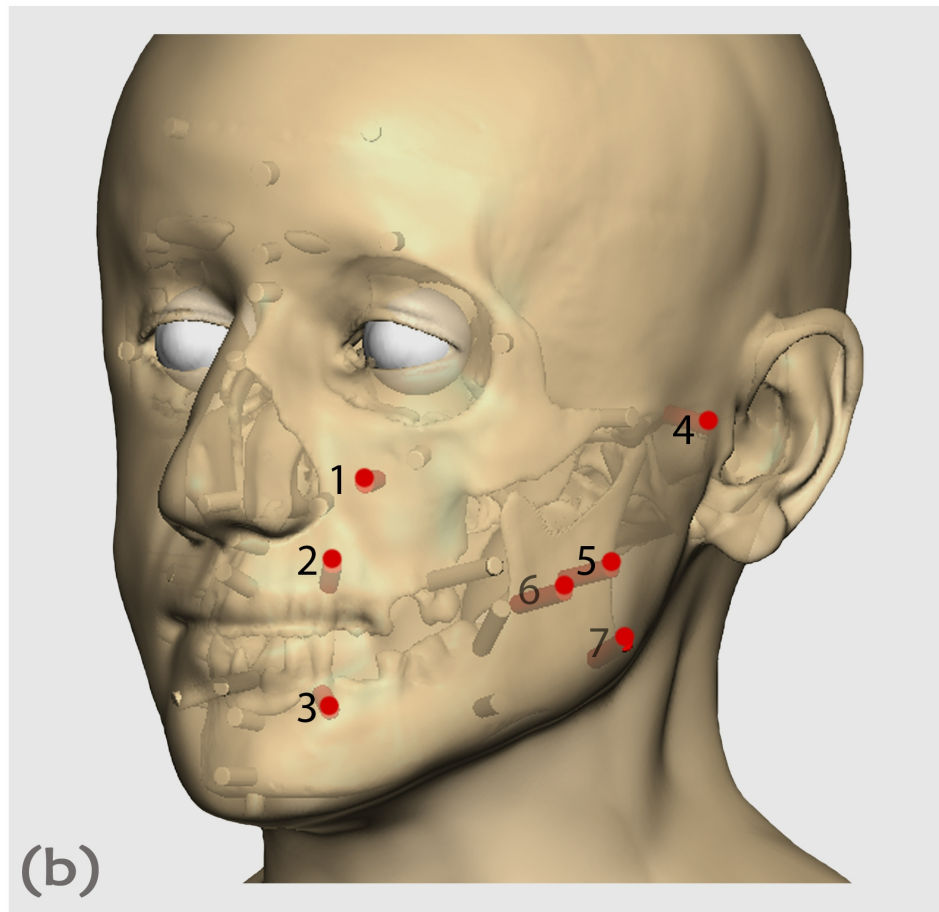
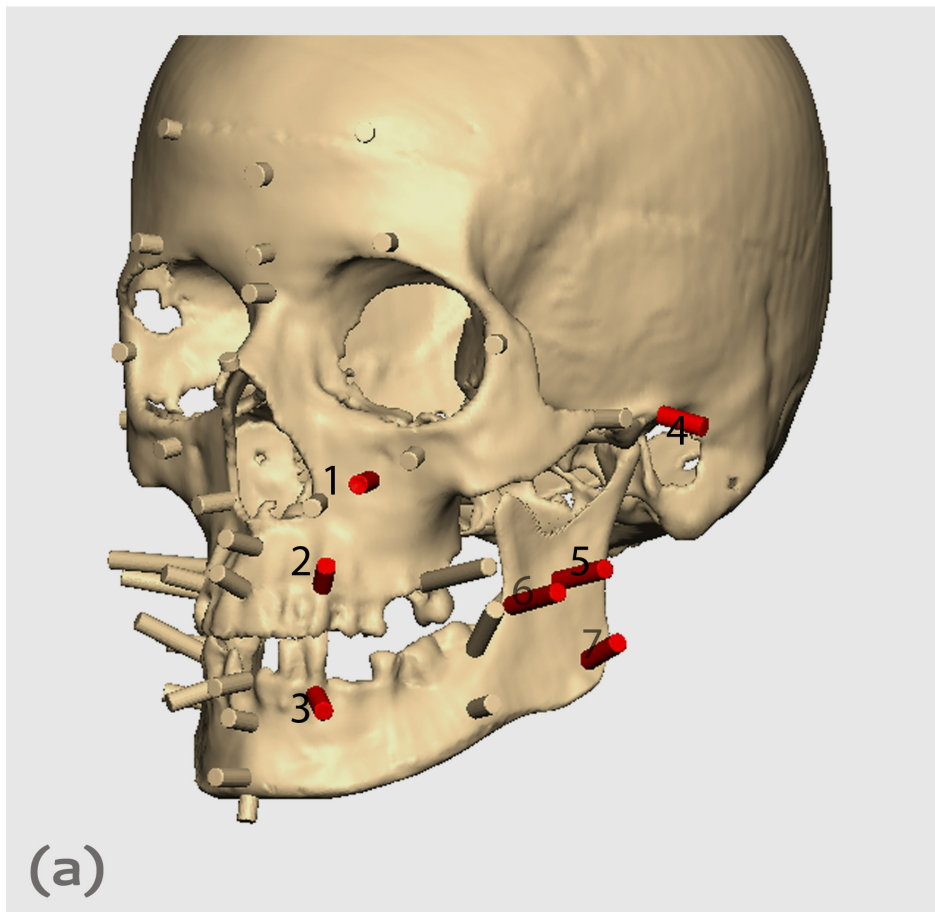


Table 1 Distribution (%) of the deviation error between the 3d facial scans of supine position and upright position within each defined error range (minimum range within ± 2 mm)

Deviation (X: mm, minimum range within ± 2 mm)						
	$-10.0 \leq X < -5.0$	$-5.0 \leq X < -2.0$	$-2.0 \leq X \leq 2.0$	$2.0 \leq X \leq 5.0$	$5.0 \leq X \leq 10.0$	Total (%)
Subject 1	2.6	5.0	84.8	5.0	2.6	100
Subject 2	0	6.0	85.4	6.0	2.6	100
Subject 3	1.0	7.4	82.6	7.0	2.0	100
Subject 4	0.6	7.4	83.6	6.8	1.6	100
Subject 5	2.6	5.0	84.8	5.0	2.6	100
Subject 6	1.3	6.3	84.8	5.4	2.2	100
Subject 7	1.5	6.9	82.4	7.1	1.7	100
Subject 8	0.9	7.3	83.1	7.1	1.6	100
Subject 9	2.0	5.2	85.1	5.4	2.3	100
Subject 10	0.3	5.5	85.6	6.4	2.2	100
Subject 11	1.0	7.5	82.5	6.8	2.2	100
Subject 12	0.9	7.6	84.5	5.6	1.4	100
Subject 13	2.0	4.0	85.9	5.2	2.9	100
Subject 14	1.0	6.0	86.7	6.3	2.0	100
Subject 15	1.0	7.0	83.2	6.8	2.0	100
Subject 16	0.6	6.4	84.9	6.8	1.3	100
Subject 17	2.5	5.0	84.0	6.0	2.5	100
Subject 18	0.7	6.0	85.3	6.4	1.6	100
Subject 19	1.0	4.0	86.6	7.4	1.0	100
Subject 20	0.6	7.4	83.2	6.8	2.0	100
Subject 21	2.6	5.0	84.4	5.4	2.6	100
Subject 22	0.2	6.0	85.8	6.4	1.6	100
Subject 23	1.0	7.4	82.6	7.0	1.0	100
Subject 24	1.1	7.3	84.6	5.8	1.2	100
Subject 25	2.3	5.0	83.7	6.4	2.6	100
Subject 26	0	6.0	85.0	6.3	2.7	100
Subject 27	1.1	7.3	84.6	6.0	1.0	100
Subject 28	1.0	7.2	83.6	6.8	1.4	100
Subject 29	2.6	4.0	84.4	5.4	8.6	100
Subject 30	0	6.0	85.0	6.0	3.0	100
Subject 31	0.6	4.4	86.0	7.0	2.0	100
Subject 32	0.5	7.4	83.1	7.8	1.2	100
Subject 33	2.6	5.0	84.0	6.0	2.4	100
Subject 34	0.2	6.5	85.3	6.0	2.0	100
Subject 35	1.1	7.0	82.9	7.0	2.0	100
Subject 36	0.6	7.4	84.5	5.8	1.7	100
Subject 37	2.4	5.1	84.9	5.0	2.6	100
Subject 38	3.0	6.0	82.6	6.0	2.4	100
Subject 39	1.0	7.4	83.6	7.0	1.0	100
Subject 40	0.6	6.4	84.5	6.9	1.6	100
Subject 41	2.6	5.6	84.8	5.0	2.0	100
Subject 42	1.1	5.9	84.4	6.1	2.5	100
Subject 43	1.0	6.4	83.6	6.5	2.5	100
Subject 44	1.6	7.4	83.0	6.8	1.2	100