



LJMU Research Online

Irish, JD

Tooth transposition prevalence and type among sub-Saharan Africans

<http://researchonline.ljmu.ac.uk/id/eprint/12107/>

Article

Citation (please note it is advisable to refer to the publisher's version if you intend to cite from this work)

Irish, JD (2019) Tooth transposition prevalence and type among sub-Saharan Africans. American Journal of Human Biology. ISSN 1042-0533

LJMU has developed **LJMU Research Online** for users to access the research output of the University more effectively. Copyright © and Moral Rights for the papers on this site are retained by the individual authors and/or other copyright owners. Users may download and/or print one copy of any article(s) in LJMU Research Online to facilitate their private study or for non-commercial research. You may not engage in further distribution of the material or use it for any profit-making activities or any commercial gain.

The version presented here may differ from the published version or from the version of the record. Please see the repository URL above for details on accessing the published version and note that access may require a subscription.

For more information please contact researchonline@ljmu.ac.uk

<http://researchonline.ljmu.ac.uk/>



LJMU Research Online

Irish, JD

Tooth transposition prevalence and type among sub-Saharan Africans

<http://researchonline.ljmu.ac.uk/id/eprint/12107/>

Article

Citation (please note it is advisable to refer to the publisher's version if you intend to cite from this work)

Irish, JD (2019) Tooth transposition prevalence and type among sub-Saharan Africans. AMERICAN JOURNAL OF HUMAN BIOLOGY. ISSN 1042-0533

LJMU has developed **LJMU Research Online** for users to access the research output of the University more effectively. Copyright © and Moral Rights for the papers on this site are retained by the individual authors and/or other copyright owners. Users may download and/or print one copy of any article(s) in LJMU Research Online to facilitate their private study or for non-commercial research. You may not engage in further distribution of the material or use it for any profit-making activities or any commercial gain.

The version presented here may differ from the published version or from the version of the record. Please see the repository URL above for details on accessing the published version and note that access may require a subscription.

For more information please contact researchonline@ljmu.ac.uk

<http://researchonline.ljmu.ac.uk/>

1
2
3
4
5 **Tooth transposition prevalence and type among sub-Saharan Africans**
6
7
8
9
10

11
12 Joel D. Irish

13
14 Research Centre in Evolutionary Anthropology and Palaeoecology,
15

16
17 Liverpool John Moores University
18
19
20
21

22
23 10 text pages

24
25 6 reference pages

26
27 2 tables

28
29 1 figure
30
31
32
33
34

35 Running Title: Tooth transposition among sub-Saharan Africans
36
37
38
39
40

41 Correspondence to: Prof. Joel D. Irish
42 Research Centre in Evolutionary Anthropology and Palaeoecology
43 School of Biological and Environmental Sciences
44 Liverpool John Moores University
45 Liverpool L3 3AF
46 United Kingdom
47 +44 (0)151 231 2387
48 J.D.Irish@ljmu.ac.uk
49
50
51
52
53

54 *KEY WORDS* anomalies, ectopic eruption, prevalence, dental arch, Africa
55
56
57
58
59
60

Abstract

Objectives: Although rare, tooth transposition—an exchange in location of two teeth—is a frequent topic of study. Clinical and, to a much lesser extent, dental anthropological research have focused predominantly on prevalence (0.03-0.74% in several world populations) and case studies, albeit on a restricted spatiotemporal scale. Many regions have received little attention, including sub-Saharan Africa, while premodern data are few. Here, the aim is to supplement both fields of dental research by reviewing previous publications, and newly reporting transposition rates, types, and co-occurring abnormalities in time-successive samples across the sub-continent.

Methods: Dental data in 51 sub-Saharan samples (>2500 individuals) dating >10,000 BC-20th century were recorded. Of these, 36 are of modern and 15 pre-modern age, comprising males and females ≥ 12 -years of age. Transposition presence, quadrant, and type were tabulated, cases described, and prevalence presented. In the latter case, Poisson 95% confidence intervals were calculated to better discern true population rates at various geographic levels.

Results: Overall, six of 1886 modern individuals (0.32%) and one of pre-modern age evidence Mx.C.P1, an exchange of the maxillary canine and first premolar. Various associated dental abnormalities are also evident, including retained deciduous teeth, reduced permanent crowns, and agenesis.

Conclusions: This study provides additional insight into the geographic distribution, features, and time depth of transposition, along with hints supporting a genetic etiology and, potentially, some indications of diachronic change from an initial Mx.C.P1 to several types more recently based on pre-modern evidence. It is of clinical concern today, but is not just a modern anomaly.

1) INTRODUCTION

Tooth transposition, a partial or complete exchange of location between teeth, is rare. Based on results of limited sampling, primarily in Europe and, by diminishing degrees, the U.S., Mideast, India, and Africa, its prevalence is 0.03%-0.74% (though see below) in modern populations (Van Reenen, 1964; Peck et al., 1993, Burnett, 1999; Hatzoudi & Papadopoulous, 2006; Onyeaso & Onyeaso, 2006; Watted et al., 2015; etc.). Excluding syndromic cases (e.g. Lewyllie et al., 2017), a meta-analysis by Papadopoulous et al. (2010) yielded a mean of 0.33%. Thus, it may follow that documentation is equally rare. Not so.

A search for alternative forms of the words “transposition” and “tooth” or “teeth” or “dental” or “incisor” or “canine” or “cuspid” or “premolar” or “bicuspid” or “molar” yielded >350 results on Scopus (scopus.com), Web of Science (<http://apps.webofknowledge.com/>), and PubMed (ncbi.nlm.nih.gov/pubmed). For example, PubMed returned 363 unique titles, with 243 referencing the positional anomaly. Of these, 238 (97.9%) are clinical in scope, including: 1) case studies and treatment (Newman, 1977; Shapira & Kuffinec, 1983; Maia & Maia, 2005; Onyeaso & Onyeaso, 2006; Hatzoudi & Papadopoulous, 2006; Babacan et al., 2008; Taguchi et al., 2009; Kuttapa et al., 2011, etc.), 2) literature reviews (Järvinen, 1982; Peck et al., 1993; Huber et al., 2008; Papadopoulos et al., 2010), 3) a combination of these two (Shapira et al., 1989; Peck & Peck, 1995; Mattos et al., 2005; Tripathi et al., 2014; Watted et al., 2015; Loil, 2017), 4) etiology (Feichtinger et al., 1977; Sandham & Harvie, 1985; Shah, 1994; Shapira et al., 2000; Ely et al., 2006; Lewyllie et al., 2017) and 5) in one case, forensic pathology (Nambiar et al., 2014). Tooth transposition is largely perceived to be a modern orthodontic issue (Shapira & Kuffinec, 1989, 2001; Peck et al., 1993; Peck & Peck, 1995; Plunket et al., 1998; Budai et al.,

1
2
3 2003; Maia & Maia, 2005; Yilmaz et al., 2005; Mattos et al., 2005; Ely et al., 2006; Babacan et
4 al., 2008; Tripathi et al., 2014; Watted et al., 2015; among others). However, as the remaining
5
6 five of 238 articles (2.1%) reveal, the anomaly has long affected humans, based on dental
7
8 anthropological research in mostly pre-modern (archaeological) samples from the New and Old
9
10 Worlds (Nelson, 1992; Lukacs, 1998; Burnett, 1999; Burnett & Weets, 2001; Sholts et al., 2010).
11
12
13

14
15 The present study complements both clinical and anthropological research by exploring
16
17 further the geographic range of transposition and its antiquity. Firstly, prevalence is reported in
18
19 samples across sub-Saharan Africa—a major yet underreported world region. Case studies are
20
21 described to assess comparability with others worldwide. Specifically, prior study found that
22
23 maxillary transposition is most common; the canine and first premolar are frequently affected;
24
25 unilateral left quadrant expression dominates; occurrences seem biased toward females; other
26
27 developmental abnormalities in tooth formation and position (though not stress, e.g., hypoplasia)
28
29 often co-occur (below); and a genetic etiology is thought likely but not confirmed (e.g. Shapira
30
31 & Kuffinec, 1989, 2001; Peck et al., 1993; Peck & Peck, 1995; Plunket et al., 1998; Budai et al.,
32
33 2003; Maia & Maia, 2005; Yilmaz et al., 2005; Mattos et al., 2005; Ely et al., 2006; Babacan et
34
35 al., 2008; Tripathi et al., 2014; Watted et al., 2015). Lastly, tooth transposition in pre-modern
36
37 specimens, some dating to >9000 BC, is also discussed with one new-found example described.
38
39

40
41 The overarching intent, then, is to help further place “clinical research . . . in historical
42
43 perspective,” and understand better the “evolutionary origins and significance of this dental
44
45 anomaly” (Lukacs, 1998:479).
46
47

48 49 **2) METHODS**

50
51 Tooth transposition data were collected during the course of research into sub-Saharan African
52
53 population affinities (Irish, 1993, 1997, 1998, 2010, 2013, 2016a,b; Irish & Guatelli-Steinberg,
54
55
56
57

1
2
3 2003; Irish et al., 2014, 2018), using highly hereditary nonmetric traits from the Arizona State
4 University Dental Anthropology System (ASUDAS) (Turner et al., 1991; Scott & Irish, 2017). In
5
6 a few cases, transposition recorded by the author was either previously or subsequently reported
7
8 by other authors, and is so noted. All told, 52 samples defined securely by ethnicity and/or site
9
10 provenience across 19 countries were analyzed. Sampling was purposefully broad to represent a
11
12 maximum number of populations at the sub-continental level. These samples comprise 2742
13
14 skeletal dentitions and casts of living individuals dating 10,880 BC-20th century.
15
16
17
18

19 For the present study, only those aged ≥ 12 -years with at least one extant quadrant were
20 included. This left 51 samples with 2527 maxillae and 2116 mandibles for which transposition,
21
22 e.g. Mx.C.I2, Mx.C.P1, Mx.C to M1, Mx.I2.I1 and Mx.C to I1 (after Peck & Peck, 1995), and
23
24 abnormalities are reported (Peck et al., 1993, 1996; Yilmaz et al., 2005). Based on the curation
25
26 records or as determined from diagnostic skeletal indicators (Buikstra & Ubelaker, 1994), 246
27
28 maxillae were categorized as 'male' or 'male?', 892 'female' or 'female?', and 389 unknown.
29
30 Mandible counts are 1043, 745, and 328. Samples were then subdivided into: 1) 36 modern,
31
32 considered 19th-20th centuries, with 1886 maxillary and 1597 mandibular dentitions, and 2) 15
33
34 pre-modern samples, 10,880 BC-AD 1780, totaling 641 and 519, respectively. These dates are
35
36 from curation data, or sources referenced in Irish (1993, 1997, 2013, 2016b, et al., 2014). Due to
37
38 the rarity of transposition, all modern samples were then pooled to obtain prevalence by sub-
39
40 Saharan region—western, central, eastern, southern—rather than 36 rates of mostly 0.00%. The
41
42 total sample is large relative to the aforementioned prevalence studies, but the infrequency and
43
44 vast geographic scale encouraged use of a Poisson model to calculate 95% confidence intervals
45
46 (CI), within which true population rates are likely contained (e.g. Rothman et al., 2008). For the
47
48
49
50
51
52
53
54
55
56
57
58
59
60

1
2
3 smaller total pre-modern sample, derived from the same geographic range plus markedly greater
4
5 time depth, only counts and a description are provided.
6

7 8 **3) RESULTS**

9
10 Six of the 1886 modern maxillae, 0.32%, evidence transposition (Table 1) with a 95% CI of
11
12 0.12-0.69%. Three are from the central region (0.96% of 314; CI 0.20-2.79%) and three from
13
14 southern sub-Saharan Africa (0.37% of 806; CI 0.08-1.09%).
15

16
17 The central individuals, all ethnic Hutu, derive from one cemetery (3/93 individuals;
18
19 3.2%) in Nyirankuba Cave, near Ruhengeri, Rwanda (Ribot, 2003; Giblin, 2008). Each has
20
21 Mx.C.P1 (Peck & Peck, 1995), i.e. maxillary canine-first premolar exchange. Brabant (1963)
22
23 also noted the anomalies; unfortunately, sexes of the affected individuals were not reported in
24
25 this French-language publication, which is generally unavailable today. For the present study, the
26
27 sexes were determined as two females and one male. The first female has unilateral partial left
28
29 transposition (Figure 1A). Many teeth are missing post-mortem, but associated abnormalities
30
31 include left first and second premolar rotation, a reduced right second premolar, reduced right
32
33 and left lateral incisors, and a retained deciduous left canine. The second female exhibits bilateral
34
35 Mx.C.P1, with partial right- and complete left transposition (Figure 1B). Beyond the premolar
36
37 rotation, abnormalities include a reduced right lateral incisor, a congenitally absent left lateral
38
39 incisor, and bilateral third molar agenesis—which is otherwise very rare (<4.5%) in sub-Saharan
40
41 populations (Irish, 2016b). The male has partial left side transposition. Only the left second
42
43 premolar and first molar are retained postmortem. The root of the latter tooth is taurodont, but no
44
45 other abnormalities are evident.
46
47
48
49

50
51 Of the three affected modern southern Africans two, both females, are from a collection
52
53 of 143 casts of San, from the !Kung, Naron, Tshakwe, Mkaukau, and Gwikwe ethnic groups
54
55
56
57

1
2
3 (Irish, 1993). The prevalence, 1.4% (2/143), was also reported by Burnett (1999). The casts are
4 copies of originals from the Nuffield Foundation-Witwatersrand Kalahari Research Committee
5 Expedition to Ghanzi, Botswana (Irish, 1993). The first individual has right complete Mx.C.P1,
6 with an impacted maxillary left first premolar, and mandibular second premolar agenesis. The
7 second individual also has right complete Mx.C.P1. Further maxillary abnormalities include a
8 retained right deciduous canine, right lateral incisor agenesis, and peg-shaped left lateral incisor.
9
10 The third southern African case, unilateral partial right Mx.C.P1 (Figure 1C), occurred in one 32-
11 year old male out of 57 Swazi (1.7%); this sample was chosen randomly from a larger Swazi
12 collection for the nonmetric study (Irish, 2016b). No other abnormalities are evident.
13
14
15
16
17
18
19
20
21
22
23

24 Lastly, transposition occurred in one of 641 pre-modern maxillae (Table 2), and none of
25 the 519 mandibles. This southern region male displays unilateral right partial Mx.C.P1 (Figure
26 1D). Accompanying abnormalities include reduced third molars and a retained right deciduous
27 canine. It is one of 41 complete crania recorded in the Matjes River Rockshelter sample from
28 South Africa (Irish et al., 2014). Unfortunately, this particular cranium is undated, though Matjes
29 River and nearby rock shelters were used by local peoples during 9186-250 BC.⁴⁵
30
31
32
33
34
35
36
37

38 **4) DISCUSSION**

39
40 Numerous transposition articles are available yet the rates, 0.03%- 0.64% [excluding 0.74% in
41 Van Reenen's (1964) small Africa sample], are based on few studies from fewer locations. They
42 are limited further spatially, i.e. patients visiting a local clinic, and/or sample sizes (Peck et al.,
43 1993, Hatzoudi & Papadopoulous, 2006; Papadopoulous et al., 2010; Watted et al., 2015; etc.).
44
45 Less is known about other regions including sub-Saharan Africa, where only five studies have
46 been published and are subject to the above limitations. One reports 11 cases in 8125 (0.14%)
47 dental patients, but from just one location in Nigeria (Umweni & Ojo, 1997). Of interest, only
48
49
50
51
52
53
54
55
56
57
58
59
60

1
2
3 four Mx.C.P1 examples were observed. A second clinical study reports a higher prevalence,
4 0.60%, but again in one location and a smaller sample of 361 Nigerian students; the types are
5 unspecified (Onyeaso & Onyeaso, 2006). The other studies are anthropological, including the
6 Rwandan cases (Brabant, 1963). As well, two of 385 casts from two southern region groups,
7 many of which are included in prior research (Irish, 1993, 1997) and the present study, were
8 noted with Mx.C.P1 at 0.52% (Burnett, 1999). Lastly, Van Reenen (1964) recorded a rate of
9 0.74% Mx.C.P1 in 406 casts of San from Botswana, some of which may duplicate those in
10 Burnett (1999) and here.
11
12
13
14
15
16
17
18
19
20
21

22 The present results, 0.32% (6/1866) and CI 0.12-0.69%, lie within the range for other
23 world groups (above)—perhaps suggesting uniform occurrence of transposition independent of
24 population origin. While not completely ‘modern’ (19th-20th centuries), the total sample size
25 from 36 well-defined ethnic groups in many locations is large (Table 1). Further, transposition
26 was not the focus of study during nonmetric trait recording, so sampling was basically random.
27 Thus, the results are, arguably, representative estimates for the collective native inhabitants of
28 sub-Saharan Africa. With regard to regional prevalence (Table 1), although some insight may be
29 obtained, the anomaly’s infrequency, again, compromises reliability—until larger samples are
30 available at these specific levels.
31
32
33
34
35
36
37
38
39
40
41

42 Of the six modern individuals with transposition, many features are also comparable with
43 those noted in the introduction for other populations. The maxilla is involved (100%), all are the
44 Mx.C.P1 type (100%), and five of six (83.3%) have unilateral expression. That said, three of the
45 five occurrences, 60%, are in the right maxilla—contra reported left quadrant dominance. Back
46 in agreement, four individuals (66.7%) were females, and five (83.3%) evidence abnormalities
47 known to co-occur. The latter include: 1) 33% (2/6) with a retained maxillary deciduous canine,
48
49
50
51
52
53
54
55
56
57
58
59
60

1
2
3 compared to 50% for other world areas, 2) 50% (3/6) reduced or peg-shaped permanent teeth—
4
5 mostly lateral incisors, relative to 25%, and 3) 50% (3/6) agenesis, often lateral incisors, which
6
7 otherwise occurs in 37-40% of cases (Shapira & Kuffinec, 1989; Peck et al., 1993, 1996; Peck &
8
9 Peck, 1995; Plunket et al., 1998; Budai et al., 2003; Mattos et al., 2005; Tripathi et al., 2014;
10
11 Watted et al., 2015). Moreover, though not the focus here, a genetic etiology may be supported
12
13 in that these sub-Saharan characteristics emulate those of other populations, while transposition
14
15 occurs multiple times within two samples, perhaps suggesting familial affinity (see Nelson, 1992
16
17 for an overview of this and other potential causes of transposition); these factors are reminiscent
18
19 of more common positional anomalies commonly recorded as ASUDAS traits, including incisor
20
21 winging, midline diastema, and torsomolar angle (Turner et al., 1991; Scott & Irish, 2017). Of
22
23 course, specific genetic-focused research and increasing sample numbers are requisite for
24
25 confirmation.
26
27
28
29
30

31 With exceptions, little is known about pre-modern transposition. From the New World,
32
33 nine of 106 (8.5%) Native American crania dating 3800-2500 BC, from Santa Cruz Island have
34
35 Mx.C.P1 (Nelson, 1992). A study of other Santa Barbara Channel Island samples found seven of
36
37 966 (0.73%), 5500-600 BC, with Mx.C.P1 (Sholts et al., 2010). Eleven of 510 crania (2.2%)
38
39 from New Mexico, AD 1300-1846, display this transposition (Burnett & Weets, 2001). In the
40
41 Old World, one of 20 (5.0%) from Sarai Khola (1000-270 BC), and one of ca. 90 (>1.0%) from
42
43 Harappa—both in Pakistan (2500 BC), exhibit Mx.C.P1 (Lukacs, 1998). From northeast Africa,
44
45 one of 205 (0.49%) from Semna South in far-north Sudan has Mx.C.P1 (Burnett, 1999); the date
46
47 is 100 BC-AD 350 (Irish, 1993). In addition, transposition of unnamed type(s) was reported in
48
49 some Egyptian specimens of unspecified date (perhaps 3400-1077 BC?) (Satinoff, 1972). As
50
51 above, these studies have sampling issues, i.e. few in number and restricted to one region. As
52
53
54
55
56
57
58
59
60

1
2
3 well, it is the existence of transposition in these mostly small samples (though see Sholts et al.,
4
5 2010) that likely prompted the publications and contributed to several extreme rates (1.1-8.5%).
6

7
8 The total of 641 pre-modern individuals is relatively large, and the sampling was random,
9
10 as above (Table 2). That said, the geographic and temporal scales are significantly greater than in
11
12 the abovementioned studies, so the overall and regional samples are likely not representative, at
13
14 least relative to the modern analyses. Further, the regions are not equally represented. Thus, the
15
16 result (1/641) is primarily useful in assessing further the type(s) and antiquity of transposition
17
18 alongside those described earlier.
19

20
21 Characteristics of the affected sub-Saharan individual parallel many from modern cases,
22
23 with unilateral Mx.C.P1 and associated abnormalities; yet, contrarily, this was a male with right
24
25 quadrant transposition. The Santa Barbara Channel Island (Nelson, 1992; Sholts et al., 2010) and
26
27 Pakistan features (Lukacs, 1998) correspond with modern tendencies, though the rest vary to
28
29 some extent. In the New Mexico study, males (55.6%) and the right quadrant (66.7%) were more
30
31 affected (Burnett & Weets, 2001), while the Sudanese individual was also male (Burnett, 1999).
32
33 Accompanying crown rotation, reduced size, retained deciduous teeth, and agenesis occur as
34
35 well, although less than modern cases (i.e. personal observation, 1989; Nelson, 1992; Lukacs,
36
37 1998; Burnett & Weets, 2001; Sholts et al., 2010). Of interest, not only is Mx.C.P1 the most
38
39 common today but, based on this overview, it is the only type recorded in pre-modern samples.
40
41 The oldest confirmed examples date 5500 BC (Sholts et al., 2010) in the New World and 2500
42
43 BC in the Old World (Lukacs, 1998). As mentioned, the present southern African individual
44
45 *could* predate both (≤ 9186 BC), to help establish further the antiquity of transposition; of course,
46
47 the date is unknown, and could be younger. In any event, though samples and examples are few,
48
49 it seems Mx.C.P1 may be the earliest, with other maxillary, i.e. Mx.C.I2, Mx.C to M1, Mx.I2.I1,
50
51
52
53
54
55
56
57

1
2
3 Mx.C to I1 (Peck & Peck, 1995), and mandibular types not evident until recently. In sum, this
4
5 overview not only provides additional historical context, but new insight into the distribution,
6
7 origins and, perhaps, evolution of tooth transposition. It is patently not just a modern anomaly.
8
9

10 **ACKNOWLEDGMENTS**

11
12 Thank you to everyone at the: American Museum of Natural History, Arizona State University,
13
14 Florisbad Quaternary Research Station, Institut royal des Sciences naturelles de Belgique, Musée
15
16 de l'Homme, National Museums of Kenya, Natural History Museum, National Museum of
17
18 Natural History, Université de Bruxelles, University of Cambridge, University of Cape Town,
19
20 and University of the Witwatersrand. Funded by the National Science Foundation (BNS-
21
22 9013942, BNS-0104731, BCS-0840674).
23
24
25

26 **CONFLICT OF INTEREST STATEMENT**

27
28 The author declares no potential conflicts of interest with respect to the authorship and/or
29
30 publication of this article.
31
32
33
34
35
36
37
38
39
40
41
42
43
44
45
46
47
48
49
50
51
52
53
54
55
56
57
58
59
60

REFERENCES

- Babacan, H., Kiliç, B., & Biçakçi, A. (2008). Maxillary canine-first premolar transposition in the permanent dentition. *Angle Orthod.*, 78(5), 954-960.
- Brabant, H. (1963). Observations anthropologiques et odontologiques sur les dents des Hutu du Rwanda. *Mus R Afr Centrale Tervuren Belg Ann Ser IN-8*. 47, 1-30.
- Budai, M., Ficzer, I., Gabris, K., & Tarjan, I. (2003). Frequency of transposition and its treatment at the Department of Orthodontics of Semmelweis University in the last five years. *Fogorv SZ*, 96(1), 21-24.
- Buikstra, J.E., & Ubelaker, D.H. (1994). *Standards for Data Collection from Human Skeletal Remains*. Arkansas Archaeological Survey Research Series, 44, Fayetteville.
- Burnett, S.E. (1999). Prevalence of maxillary canine-first premolar transposition in a composite African sample. *Angle Orthod.*, 69(2), 187-189.
- Burnett, S.E., & Weets, J.D. (2001). Maxillary canine-first premolar transposition in two Native American skeletal samples from New Mexico. *Am J Phys Anthropol.*, 116(1), 45-50.
- Ely, N.J., Sherriff, M., & Cobourne, T. (2006). Dental transposition as a disorder of genetic origin. *Eur J Orthod.*, 28(2), 145-151.
- Feichtinger, C., Rossiwall, B., & Wunderer, H. (1977). Canine transposition as autosomal recessive trait in an inbred kindred. *J Dent Res.*, 56(12), 1449-52.
- Giblin, J. (2008). New work on the later archaeology of Rwanda 2006 to 2007: A preliminary fieldwork report. *Nyame Akuma*, 69, 45-55.
- Hatzoudi, M., & Papadopoulos, M.A. (2008). Prevalence of tooth transposition in Greek population. *Hell Orthod Rev.*, 9(1), 11-22.

- 1
2
3 Huber, K.L., Suri, L., & Taneja, P. (2008). Eruption disturbances of the maxillary incisors: a
4
5 literature review. *J Clin Pediatr Dent.*, 32(3), 221-30.
6
7
8 Irish, J.D. (1993). *Biological Affinities of Late Pleistocene through Modern African Aboriginal*
9
10 *Populations: The Dental Evidence* [Ph.D. dissertation]. Arizona State University, Tempe.
11
12 Irish, J.D. (1997). Characteristic high- and low-frequency dental traits in sub-Saharan African
13
14 populations. *Am J Phys Anthropol.*, 102(4), 455-467.
15
16
17 Irish, J.D. (1998). Ancestral dental traits in recent sub-Saharan Africans and the origins of
18
19 modern humans. *J Hum Evol.*, 34(1), 81-98.
20
21
22 Irish, J.D. (2010). The mean measure of divergence (MMD): its utility in model-free and model-
23
24 bound analyses relative to the Mahalanobis D2 distance for nonmetric traits. *Am J Hum*
25
26 *Biol.*, 22(3), 378–395.
27
28
29 Irish, J.D. (2013). Afridonty: the ’’Sub-Saharan African Dental Complex’’ revisited. In Scott,
30
31 G.R. and Irish, J.D. (eds.), *Anthropological Perspectives on Tooth Morphology: Genetics,*
32
33 *Evolution, Variation*. Cambridge University Press, Cambridge, pp. 278–295.
34
35
36 Irish, J.D. (2016a). Assessing dental nonmetric variation among populations. In Irish, J.D. and
37
38 Scott, G.R. (eds.), *A Companion to Dental Anthropology*. Wiley Blackwell, New York. pp.
39
40 265-286.
41
42
43 Irish, J.D. (2016b). Who were they really? Model-free and model-bound dental nonmetric
44
45 analyses to affirm documented population affiliations of seven South African ’’Bantu’’
46
47 samples. *Am J Phys Anthropol.*, 159(4), 655–670.
48
49
50 Irish, J.D., & Guatelli-Steinberg, D. (2003). Ancient teeth and modern human origins: an
51
52 expanded comparison of African Plio-Pleistocene and recent world dental samples. *J Hum*
53
54 *Evol.*, 45(2), 113–144.
55
56
57

- 1
2
3 Irish, J.D., Black, W., Sealy, J., & Ackermann, R. (2014). Questions of Khoesan continuity:
4
5 Dental affinities among the indigenous Holocene peoples of South Africa. *Am J Phys*
6
7 *Anthropol.*, 155(1), 33-44.
8
9
10 Irish, J.D., Bailey, S.E., Guatelli-Steinberg, D., Delezene, L.K., & Berger, L.R. (2018). Ancient
11
12 teeth, phenetic affinities, and African hominins: Another look at where *Homo naledi* fits in.
13
14 *J Hum Evol.*, 122, 108-123.
15
16
17 Järvinen, S. (1982). Mandibular incisor-cuspid transposition: a survey. *J Pedod.*, 6(2), 159-63.
18
19 Kuttapa, N., Nayak, U.K., Shetty, A., & Murali, P.S. (2011). Bilateral maxillary canine-premolar
20
21 transposition. *J Ind Orthod Soc.*, 45, 193.
22
23
24 Lewyllie, A., Roosenboom, J., Indencleef, K., Claes, P., Swillen, A., Devriendt, K., Carels, D.,
25
26 Cadenas De Llano-Pérula, M., Willems, G., & Verdonck A. (2017). A comprehensive
27
28 craniofacial study of 22q11.2 Deletion Syndrome. *J Den Res.*, 96(12), 1386–1391.
29
30
31 Loli, D. (2017). Dental transpositions: a systematic review. WebmedCentral > Review articles.
32
33 Downloaded from <http://www.webmedcentral.com> on 23-Nov-2017.
34
35
36 Lukacs, J.R. (1998). Canine transposition in prehistoric Pakistan: Bronze Age and Iron Age case
37
38 reports. *Angle Orthod.*, 68(5), 475-480
39
40
41 Maia, F.A., & Maia, N.G. (2005). Unusual orthodontic correction of bilateral maxillary canine–
42
43 first premolar transposition. *Angle Orthod.*, 75(2), 266-276.
44
45
46 Mattos, B.S.C., Carvalho, J.C.M., Matusita, M., & Alves, A.P.P.P. (2006). Tooth transposition–
47
48 A literature review and a clinical case. *Brazilian J Oral Sci.*, 5(16), 953-957.
49
50
51 Nambiar, S., Mogra, S., & Shetty, S. (2014). Transposition of teeth: a forensic perspective. *J For*
52
53 *Dent Sci.*, 6(3), 151.
54
55
56
57
58
59
60

- 1
2
3 Nelson, G.C. (1992). Maxillary canine/third premolar transposition in a prehistoric population
4
5 from Santa Cruz Island, California. *Am J Phys Anthropol.*, 88(2), 135-144
6
7
8 Newman, G.V. (1977). Transposition: orthodontic treatment. *J Am Dent Assoc.*, 94(3), 544-547.
9
10 Onyeaso, C.O., & Onyeaso, A.O. (2006). Occlusal/dental anomalies found in a random sample
11
12 of Nigerian schoolchildren. *Oral Health Prev Dent.*, 4(3), 181–186.
13
14
15 Papadopoulos, M.A., Chatzoudi, M., & Kaklamanos, E.G. (2010). Prevalence of tooth
16
17 transposition: a meta-analysis. *Angle Orthod.*, 80(2), 275-285.
18
19
20 Peck, S., & Peck, L. (1995). Classification of maxillary tooth transpositions. *Am J Orthod*
21
22 *Dentofacial Orthop.*, 10(5), 505–517.
23
24
25 Peck, L., Peck, S., & Attia, Y. (1993). Maxillary canine-first premolar transposition, associated
26
27 dental anomalies and genetic basis. *Angle Orthod.*, 63(2), 99-109.
28
29
30 Peck, S., Peck, L., & Kataja, M. (1996). Anomalies of tooth number and size associated with
31
32 malposition of the maxillary canine. *Am J Phys Anthropol Suppl.*, 22, 183.
33
34
35 Plunket, D.J., Dysart, P.S., Kardos, T.B., & Herbison, G.P. (1998). A study of transposed canines
36
37 in a sample of orthodontic patients. *Br J Orthod.*, 25(3), 203-208.
38
39
40 Ribot, I. (2003). Craniometrical analysis of central and east Africans in relation to history: a case
41
42 study based on unique collections of known ethnic affiliation. *Anthropol et Préhist.*, 114,
43
44 25-50.
45
46
47 Rothman, K.J., Greenland, S., & Lash, T.L. (2008). *Modern Epidemiology* (Vol. 3). Wolters
48
49 Kluwer Health/Lippincott Williams & Wilkins, Philadelphia.
50
51
52 Sandham, A., & Harvie, H. (1985). Ectopic eruption of the maxillary canine resulting in
53
54 transposition with adjacent teeth. *Tandlaegebladet*, 89(1), 9-11.
55
56
57
58
59
60

- 1
2
3 Satinoff, M.I. (1972). The medical biology of the early Egyptian populations from Asswan,
4
5 Assyut and Gebelen. *J Hum Evol.*, 1(3), 247-257.
6
7
8 Scott, G.R., & Irish J.D. (2017). *Human Tooth Crown and Root Morphology: The Arizona State*
9
10 *University Dental Anthropology System*, Cambridge University Press, Cambridge.
11
12 Shah, N. (1994). Extraoral tooth eruption and transposition of teeth following trauma. *Endod*
13
14 *Dent Traumatol.*, 10(4), 195-197.
15
16
17 Shapira, J., Chaushu, S., & Becker, A. (2000). Prevalence of tooth transposition, third molar
18
19 agenesis and maxillary canine impaction in individuals with Down Syndrome. *Angle*
20
21 *Orthod.*, 70(4), 290-296.
22
23
24 Shapira, Y., & Kufninec, M.M. (1983). Orthodontic management of mandibular canine-incisor
25
26 transposition. *Am J Orthod.*, 83(4), 271-276.
27
28
29 Shapira, Y., & Kufninec, M.M. (1989). Tooth transposition-review of the literature and the
30
31 treatment considerations. *Angle Orthod.*, 59(4), 271-276.
32
33
34 Shapira, Y., & Kufninec, M.M. (2001). Maxillary tooth transpositions: characteristic features and
35
36 accompanying dental anomalies. *Am J Orthod Dentofacial Orthop.*, 119(2), 127-134.
37
38
39 Shapira, Y., Kufninec, M.M., & Stom, D. (1989). Maxillary canine-lateral incisor transposition--
40
41 orthodontic management. *Am J Orthod Dentofacial Orthop.*, 95(5), 439-44.
42
43
44 Sholts, S.B., Clement, A.F., & Wärmländer, S.K. (2010). Brief communication: Additional cases
45
46 of maxillary canine-first premolar transposition in several prehistoric skeletal assemblages
47
48 from the Santa Barbara Channel Islands of California. *Am J Phys Anthropol.*, 143(1), 155-
49
50 160.
51
52
53
54
55
56
57
58
59
60

- 1
2
3 Taguchi, Y., Hayashi-Sakai, S., Iizawa, F., & Numa-Kinjoh, N. (2009). Classification of
4
5 maxillary canine transpositions in Japanese children: a report of 10 cases. *Ped Dent J.*,
6
7 19(1), 136-144.
8
9
- 10 Tripathi, S., Singh, R.D., Singh, S.V., & Arya, D. (2014). Maxillary canine transposition—A
11
12 literature review with case report. *J Oral Biol Craniofacial Res.*, 4(2), 155-158.
13
14
- 15 Turner, C.G., Nichol, C.R., & Scott, G.R. (1991). Scoring procedures for key morphological
16
17 traits of the permanent dentition: the Arizona State University dental anthropology system.
18
19 In Kelley, M.A. and Larsen, C.S. (eds.), *Advances in Dental Anthropology*, Wiley-Liss,
20
21 New York, pp. 13-32.
22
23
- 24 Umweni, A.A., & Ojo, M.A. (1997). The frequency of tooth transposition in Nigerians, its
25
26 possible aetiologic factors and clinical implications. *J Dent Assoc S Afr.*, 52(9), 551-554.
27
28
- 29 Van Reenen, J.F. (1964). Dentition, jaws and palate of the Kalahari Bushmen. *J Dent Assoc S*
30
31 *Afr.*, 19, 1-15.
32
- 33 Watted, N., Abu-Hussein, M., Hussein, E., Proff, P., & Watted, A. (2015). A dental
34
35 transposition: literature review and clinical management. *J Dent Med Sci.*, 14, 80-85.
36
37
- 38 Yilmaz, H.H., Türkkahraman, H., & Sayın, M.Ö. (2005). Prevalence of tooth transpositions and
39
40 associated dental anomalies in a Turkish population. *Dentomaxillofacial Radiol.*, 34(1), 32-
41
42 35.
43
44
45
46
47
48
49
50
51
52
53
54
55
56
57

FIGURE LEGEND

FIGURE 1 (A) Female Hutu from Rwanda with left Mx.C.P1 (arrow); numbers indicate 1) reduced second premolar, 2) reduced lateral incisors, and 3) retained deciduous canine. **(B)** Second female Hutu, showing bilateral Mx.C.P1 and 1) third molar agenesis, 2) reduced lateral incisor, and 3) congenitally absent lateral incisor. **(C)** Right Mx.C.P1 in South African Swazi male. **(D)** Mx.C.P1 in pre-modern South African male, with 1) bilaterally-reduced third molars and 2) retained deciduous canine.

TABLE 1 Tooth Transposition Frequency (k) and Percent Present (%) out of Total Number of Dentitions Observed (n) in Modern Population Samples from Four Geographic Regions of Sub-Saharan Africa (see text for details).

Region	Countries of Origin	Date	k	%	n
Western	Benin, Cameroon, Ghana, Nigeria, Senegal, Togo	19 th -20 th centuries	0	0.00	317
Central	Chad, Congo, Democratic Republic of the Congo, Gabon, Rwanda	19 th -20 th centuries	3 [†]	0.96	314
Eastern	Ethiopia, Kenya, Somalia, Tanzania	19 th -20 th centuries	0	0.00	449
Southern	Botswana, South Africa	19 th -20 th centuries	3 ^{‡§}	0.37	806
Total			6	0.318	1886

[†]Royal Belgian Institute of Natural Sciences (Cat No. AF13 #659, AF12 #651, AF6 #605).

[‡]Arizona State University (Cat No. BU 82, BU 99).

[§]Dart Collection, University of the Witwatersrand, (Cat No. A 1570).

TABLE 2 Tooth Transposition Frequency (k) and Number of Dentitions Observed (n) in Premodern Population Samples from Four Geographic Regions of Sub-Saharan Africa (see text for details).

Region	Countries of Origin	Date	k	n
Western	Burkina Faso, Cameroon	5879 BC-AD 1390	0	15
Central	Democratic Republic of the Congo, Niger	7700 BC-AD 1400	0	103
Eastern	Kenya	8100 BC-AD 1350	0	121
Southern	South Africa	10,880 BC-AD 1780	1 [†]	402
Total			1	641

[†]National Museum Bloemfontein (Cat No. P1447).

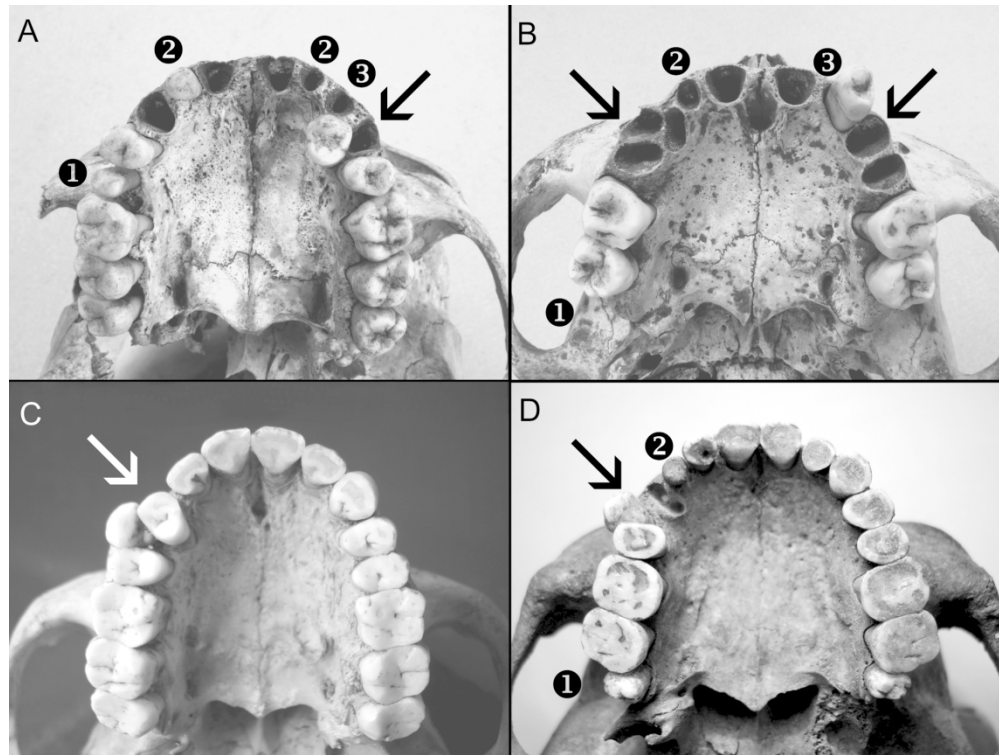


FIGURE 1 (A) Female Hutu from Rwanda with left Mx.C.P1 (arrow); numbers indicate 1) reduced second premolar, 2) reduced lateral incisors, and 3) retained deciduous canine. (B) Second female Hutu, showing bilateral Mx.C.P1 and 1) third molar agenesis, 2) reduced lateral incisor, and 3) congenitally absent lateral incisor. (C) Right Mx.C.P1 in South African Swazi male. (D) Mx.C.P1 in pre-modern South African male, with 1) bilaterally-reduced third molars and 2) retained deciduous canine.