



LJMU Research Online

Wilkinson, C, Liu, CYJ, Shrimpton, S and Greenway, E

Craniofacial identification standards: a review of reliability, reproducibility, and implementation

<http://researchonline.ljmu.ac.uk/id/eprint/22905/>

Article

Citation (please note it is advisable to refer to the publisher's version if you intend to cite from this work)

Wilkinson, C, Liu, CYJ, Shrimpton, S and Greenway, E (2024) Craniofacial identification standards: a review of reliability, reproducibility, and implementation. Forensic Science International. ISSN 0379-0738

LJMU has developed **LJMU Research Online** for users to access the research output of the University more effectively. Copyright © and Moral Rights for the papers on this site are retained by the individual authors and/or other copyright owners. Users may download and/or print one copy of any article(s) in LJMU Research Online to facilitate their private study or for non-commercial research. You may not engage in further distribution of the material or use it for any profit-making activities or any commercial gain.

The version presented here may differ from the published version or from the version of the record. Please see the repository URL above for details on accessing the published version and note that access may require a subscription.

For more information please contact researchonline@ljmu.ac.uk

<http://researchonline.ljmu.ac.uk/>



Review Article

Craniofacial identification standards: A review of reliability, reproducibility, and implementation

Caroline Wilkinson^{*}, Ching Yiu Jessica Liu, Sarah Shrimpton, Elysia Greenway

Face Lab, Liverpool John Moores University, United Kingdom



ARTICLE INFO

Keywords:

Craniofacial

Standards

Facial reconstruction/approximation

Forensic

ABSTRACT

There are numerous anatomical and anthropometrical standards that can be utilised for craniofacial analysis and identification. These standards originate from a wide variety of sources, such as orthodontic, maxillofacial, surgical, anatomical, anthropological and forensic literature, and numerous media have been employed to collect data from living and deceased subjects. With the development of clinical imaging and the enhanced technology associated with this field, multiple methods of data collection have become accessible, including Computed Tomography, Cone-Beam Computed Tomography, Magnetic Resonance Imaging, Radiographs, Three-dimensional Scanning, Photogrammetry and Ultrasound, alongside the more traditional *in vivo* methods, such as palpation and direct measurement, and cadaveric human dissection. Practitioners often struggle to identify the most appropriate standards and research results are frequently inconsistent adding to the confusion. This paper aims to clarify how practitioners can choose optimal standards, which standards are the most reliable and when to apply these standards for craniofacial identification. This paper describes the advantages and disadvantages of each mode of data collection and collates published research to review standards across different populations for each facial feature. This paper does not aim to be a practical instruction paper; since this field encompasses a wide range of 2D and 3D approaches (e.g., clay sculpture, sketch, automated, computer-modelling), the implementation of these standards is left to the individual practitioner.

1. Introduction

The field of craniofacial identification is a long standing and controversial field, attracting practitioners from a variety of backgrounds including anatomy, anthropology, dentistry, forensic art, archaeology and forensic science. The range of expertise has led to different approaches and has created confusion as to the optimal methods for implementation in forensic and archaeological cases [1,2]. This field includes facial depiction from skeletal assessment (commonly known as reconstruction, approximation or reproduction), craniofacial superimposition, post-mortem imagery, facial image comparison and age progression/regression, and practitioners may utilise clinical imaging, anthropometry, anatomical and morphological standards, automated systems, machine learning and digital technology.

Understanding how the facial features relate to skeletal structure requires visualisation and/or measurement of the soft and hard tissues of the face. Some anatomists and anthropologists, such as Charles Bell [3], Duchenne de Bologna [4] and Charles Darwin [5], focused on understanding the relationships between the face, facial expression,

craniofacial anatomy and the skull and early research included craniometrics, cadaveric dissection, anthropometry, electrostimulation and palpation. The 1895 invention and access to radiographs created the opportunity to further study the faces/skulls of living individuals, and many anthropometrical and anthropological studies utilised x-rays to establish tissue depth data, anatomical standards and facial growth. More recently the increased use of digital technology and clinical imaging has further advanced this field providing tissue depth datasets and enabling more detailed analysis of the internal hard and soft tissues of the face through Computed Tomography (CT), Magnetic Resonance Imaging (MRI), ultrasound and most recently Cone-Beam Computed Tomography (CBCT). Surface scanners have also revolutionised this field and enabled data collection from the faces of living subjects in three-dimensions and four-dimensions (with motion/time).

However, there are advantages and disadvantages associated with each of these data collection modes and inherent problems relating to cadavers and living faces [6,7]. In addition, the use of anatomical/anthropometrical points has not been consistent across modes of collection, and this may in part be due to limitations related to the mode of

^{*} Correspondence to: Face Lab, Liverpool John Moores University, G05 Aquinas Building, Maryland Street, L1 9DE, United Kingdom.

E-mail address: c.m.wilkinson@ljmu.ac.uk (C. Wilkinson).

collection. These limitations will be discussed for each collection mode in the following section. All these factors should be considered when choosing the appropriate anatomical standards/data. Fundamentally any standards will be more reliable if the sample size is large, if there is agreement across multiple studies, if the standards have been confirmed on a variety of populations and if different modes of data collection have produced similar results. Practitioners often struggle to identify the most appropriate standards and researchers often disagree on the reliability and reproducibility of standards, adding to the confusion. In addition, some standards are difficult to implement practically, especially where the standard is poorly defined, requires radiographic analysis or training. It is also worth noting that some practitioners have been slow to adopt new standards, even when old standards have been discredited, and both manual and computer-based practitioners do not always utilise all craniofacial standards due to limitations with the individual techniques/systems.

This paper does not aim to be a practical instruction paper, but rather aims to clarify how practitioners can choose optimal standards, which standards demonstrate reliability and when these standards are appropriate in craniofacial identification. Since this field encompasses a wide range of 2D and 3D approaches (e.g., clay sculpture, sketch, automated, computer-modelling), the practical implementation of these standards is left to the individual practitioner.

This review paper describes the advantages and disadvantages of each mode of data collection and collates published research to review standards across different populations for each facial feature.

2. Modes of data collection

2.1. Cadaveric dissection

Human dissection is a well-established technique for the study of anatomy and its importance in education cannot be overstated. Human dissection demonstrates variation, asymmetry, anatomical detail and the significance of form and function, whilst exposing the researcher to active learning, tactile and visual data, practical skills, ethical issues and experience of death [8]. It is recognised as the most effective way [9,10] to study the human body and can clarify the relationship between the soft and hard tissues of the face at different regions. However, a cadaveric face is quite different from a living face and many changes occur post-mortem that can affect structure, morphology and appearance [11]. Post-mortem changes to facial appearance are well described in the literature [12,13].

It is usual for cadavers to be processed through a method of preservation, such as embalming, prior to dissection, and although embalming will stop decomposition it does cause some further problems in relation to facial appearance. Embalming is utilised to preserve tissue from decomposition by coagulating the protein which dehydrates and hardens the tissue and prevents bacterial growth. Current embalming techniques make use of motorised injection such as using a pressure pump to force the embalming fluid into the cadaver. Usually, the right carotid and femoral arteries are chosen as the sites for arterial embalming with the jugular or femoral veins as the sites where the blood is drained. Fluid diffusion leads to bloating, especially at the head, and the eyes, nose, lips, ears and cheeks will become swollen. Later in the process fluid will be released and the soft tissues will return to their original size. However, the shape of the features may be permanently affected by this temporary bloating [14]. The increase and decrease in facial tissue size is well documented [15,16] and studies suggest that embalmed cadaveric facial morphology may not be reliable [17].

In addition, the soft tissues of the face are significantly affected by gravity in combination with body position and the supine face appears different to the upright face, with sagging at the cheeks, jawline, eyes, mouth and neck [18]. Most studies on cadaveric material are carried out with the body in a supine position. Finally, human dissection studies are more likely to include elderly subjects, who may exhibit significant skin,

dental and facial feature changes associated with ageing, and often do not include populations from parts of the world with religions/cultures where body donation is not commonplace.

Therefore, anatomical standards created from cadaver research may not be wholly representative of a living population or universally applicable. This does not mean that all human dissection studies are unreliable, rather that results from studies at facial regions most affected by shrinkage, bloating, position and ageing, such as the orbits, cheeks and jawline, should be treated with caution [14]. In addition, standards may not be transferable between all populations, since most anatomical dissection studies include relatively homogenous subjects from European or North American anatomy departments.

2.2. Assessment by palpation

Tactile exploration of the living face has provided standards for regions of the face [19] where the hard tissues are most superficial, such as at the nose, orbits, jaw and zygomatic bones. Subjects can be studied in an upright position and, since there are no health risks associated with this method, any population can be recruited. However, palpation can be misleading, as many soft tissues can feel inflexible and are difficult to distinguish from bone. A good example of this is the temporalis muscle, which is so robust that it can feel as solid as bone in a living face. In addition, the exact position of a bony feature may be difficult to identify when covered by layers of soft tissue. Therefore, we can assume that palpation studies are the more unreliable of the modes of data collection due to these inherent problems.

2.3. Anthropometry

Craniofacial anthropometry [20–22] involves the measurement of the face and/or skull directly on the original specimen/subject using callipers and/or other anthropometrical tools, or indirectly from three-dimensional scans or photographs, known as photogrammetry [23,24], using digital measurement tools. These methods have been utilised to produce population statistics [25,26], mean datasets and 'normal' standards for both faces and skulls, and many have been shown to be reproducible. Subjects can be studied in an upright position and, since there are no health risks to these methods, any population can be recruited. However, different methods of measurement are not necessarily comparable, and each method has its own challenges. Measurement tools employed on a living face may distort the facial tissue through compression or stretching and measurements may be affected by facial expression or head position. Measurement from single photographs has inherent problems associated with the focal plane, visualisation and perspective, and these are well documented in the literature [27]. This means that similar measurements taken from photographs and direct anthropometry are not comparable and the location of anatomical points in two-dimensional images can be fraught with difficulty and the experience of the researcher will play a significant role in the reliability of the measurements. Three-dimensional photogrammetry and surface scanners employ multiple photographs, light or lasers to record and visualise three-dimensional and/or four-dimensional (with motion/time) shape and texture and can be utilised for data collection from faces and skulls [28–33]. There are numerous available surface scanners and low-cost versions allow home use on smart phones [34] and tablets – the reliability of some low-cost scanners may not be appropriate for craniofacial analysis, and the accuracy should be tested by comparison with direct measurement prior to utilisation for data collection [35]. Many commercially available scanners have been tested for accuracy and reliability [36,37]. Scan data can be collected very quickly, in an upright position with open eyes and with variable facial expression. The sample population has no limits and there are minimal health risks. This data can be analysed for population statistics, mean/normal standards and templates. It is worth noting that the choice of anthropometrical points on the skull or the face is not necessarily

consistent across studies, and this may be due to the different disciplines (dental, surgical, anthropological) involved in the data collection prioritising points relevant to their field. These scanners cannot visualise internal structures and are reliant on lighting and skin tone (better in bright light and for paler skin tones), and some scanners suffer from artefacts caused by metal, hair or shiny surfaces [38].

It is rare that photogrammetry or direct anthropometry includes hard and soft tissue data from the same individual, but this does occur in relation to the teeth and lips. With the exception of these dental studies [39–41], anthropometry can only produce mean data and not hard-soft tissue relationships.

2.4. Cephalograms

Cephalograms are x-ray images, otherwise known as radiographs or craniographs, produced from the head, living or deceased, depicting the skeletal structure and soft tissue profile in the plane of the radiographic plate. This enables the assessment of hard and soft tissue patterns, the measurement of tissue depths and the establishment of relationships between the hard and soft tissues [42]. There are international standards associated with cephalograms due to their use in dental research/treatment, and the protocols are established as reliable and reproducible [43]. The images are taken with an upright relaxed face and are therefore not affected by position. However, cephalograms only allow analysis in the plane of the radiographic plate, they will be affected by the angle of the head [44,45] and surrounding detail may not be visualised. In addition, cephalograms suffer from magnification [46,47] and cannot distinguish between different layers of soft tissue. During x-ray collection, subjects incur a dose of radiation, and the health risk limits the number and type of subject that can be studied - typically these studies include clinical or dental patients, who may not be wholly representative of a 'normal' population.

2.5. Magnetic resonance imaging (MRI)

MRI is a type of scan that uses strong magnetic fields and radio waves to produce detailed images of the inside of the body. The human body is largely made of water molecules, and each atom contains a proton, which is sensitive to any magnetic field. The scanner's magnetic field causes the water molecules to change alignment in response to the magnetic pulses created by the scanner. Although the patient cannot feel these changes, the scanner can detect them and, in conjunction with a computer, can create a detailed cross-sectional image [48]. The imaging data can be translated to produce a three-dimensional model of the head where different soft tissues (muscle, fat, cartilage) can be distinguished easily [49]. This enables detailed analysis of anatomical structure, morphology and action. MRI has no health risks for the subject and does not limit the subject sample. However, MRI is expensive, and many people find the procedure stressful (due to the knocking noise created by the scanner) and claustrophobic inside the scanner tube: these issues can limit research potential. In addition, subject faces are affected by position (supine), the pressure of the straps and pillows employed and eye closure [18]. Metal medical implants, such as a pacemaker, brain stimulator, or other devices, are another complicating factor. Whilst MRI is excellent for the visualisation of soft tissues, it is less reliable for the visualisation of bone, which creates problems in relation to accurate measurements and the translation to three-dimensional models [50].

2.6. Computed tomography (CT)

A computed tomography scan uses X-rays and a computer to create detailed images of the inside of the body. CT scans are sometimes referred to as CAT scans or computerised tomography scans. CT scans take a fast series of X-ray images, which are combined to visualise the 3D skeletal structure along with the overall soft tissues [48]. This produces excellent three-dimensional visualisation and enables the study of living

and deceased individuals using a reliable and reproducible protocol. However, subject faces suffer from positional effects (supine), strap and pillow deformation (forehead and neck), dental artefacts (spikes in the data caused by metal fillings) and radiation (causing health risks). There have been a number of studies exploring the effects of position on CT data from the face [51–53], and these studies suggest that most tissues of the face alter shape or position when the subject is supine, and the only unaffected feature appears to be the nose. CT can distinguish between bone and soft tissue but may be difficult to distinguish between different layers of soft tissues, such as muscle and fat, and this limits any anatomical research [54]. Due to the health risks associated with CT imaging, typical samples tend to include clinical or dental patients [55], who may not be representative of a normal population, and the data may include only the regions of the head associated with the clinical/dental diagnosis/treatment. For example, clinical data often does not include the orbits (to reduce the effects to the eyeballs [56]) and dental data may be exclusively at the maxilla or mandible. This makes retrospective data difficult to utilise and limits opportunities for research. It is becoming more common for CT scans to be produced for cadavers at the mortuary, but this data suffers from the same issues associated with cadavers outlined in the human dissection paragraph.

2.7. Cone-beam computed tomography (CBCT)

CBCT visualises soft and hard tissues of the face without the same high levels of radiation as produced by ordinary CT, and this low dose radiation has similar health risks to radiographs [57]. Although the soft tissues are not as accurately visible in CBCT images as in MRI and ultrasonography, it enables the three-dimensional visualisation of each subject in enough detail for most craniofacial analysis [58]. The subject can also be scanned in an upright position and dental artefacts are less common. CBCT enables a more inclusive protocol and does not limit the sample population, and research opportunities are less restricted. However, CBCT is not yet commonly accessible, and the detail of the scans is not as high as for other modes of data collection. In a study that reviewed various imaging technologies [59] for the assessment of three-dimensional facial morphology as applied to facial reconstruction, the researchers found that there was a decrease in the error rate when CBCT was utilised.

2.8. Ultrasound

Ultrasonography can visualise soft tissues in two, three and four-dimensions (with movement/time) and can distinguish between different layers of soft and hard tissues. This enables detailed analysis of soft and hard tissue relationships and can be utilised in an upright position [60–63]. The health risks to the subject are minimal and therefore the sample population is unrestricted. However, the process is quite time consuming, and ultrasound cannot travel through air, so gel or liquid is necessary between the ultrasound probe and the subject. This is possible on skin surfaces, but limits use around the eyes, hair, mouth or ears. In addition, the probe pressure may cause compression at the skin surface and the range of imaging is limited by the probe size, which in turn is limited by the undulations of the facial surface.

2.9. Three-dimensional surface acquisition methods

The three-dimensional surface of the face can be captured by various surface data acquisition methods. This includes photogrammetry and surface scanning using high precision scanners [64–66]. These methods are contactless, can be portable or static, more cost effective in comparison to medical imaging methods, and with minimal health risks. Most importantly, it enables the capture of colour and texture information of the face. However, with the range of software and hardware available, the accuracy of the three-dimensional acquisition and standards vary based on the equipment, environment, and the reflective

properties of the object [67–69]. Four-dimensional facial capture (dynamic three-dimensional) are related to photogrammetry and involve a fixed rig, such as those used in filmmaking for realistic special effects and animation [70]. Such systems have the potential to study facial movement and expression [71,72]. None of these acquisition methods can collect internal anatomy and only provide surface information.

2.10. Tissue depth datasets

Tissue depth datasets are utilised across many craniofacial identification methods, to present the average soft tissues at a series of anatomical points across the skull. These are often divided by biological sex and/or ethnic group and there are numerous published sets of tissue depths from populations across the world from adult subjects [73–75] and a smaller number from children [75]. Optimal data would be full head collected from a large number of living subjects in three-dimensional with an upright position and minimal health risks. Currently, optimal data includes CBCT or MRI with living data preferable to cadaveric data, and upright data preferable to supine data. Challenges [76,77] with published data are the lack of consistency between the anthropometrical points utilised for craniofacial measurements and the small number of subjects when the data is divided/compared by sex, age, ethnic group, and BMI.

Some researchers call for tissue depth datasets to be combined [75, 78–80], thereby creating a universally applicable large-scale database [6]. These researchers maintain that an increased sample size reduces error in more substantial amounts than splitting samples according to previously observed differences. A cadaveric dissection study of 40 Australian subjects [15] identified a correlation between facial soft tissue depths and craniometric dimensions and devised a series of multiple linear regression equations. However, when the researchers tested these equations, using ultrasound data collected from 71 living Australian subjects [81], they concluded that the regression equations did not improve facial soft tissue estimation. A recent study using CBCT scans of 100 South African subjects [82] evaluated 9 different sets of facial tissue depth datasets and/or related regression formulae and found that the pooled universal datasets also performed poorly when compared to demographic-specific datasets and/or demographic-specific regression equations. These results suggest that there is still a use for demographic-specific datasets within the field of craniofacial identification. In addition, there is evidence that skeletal profile and dental occlusion has more of an effect on facial tissue depths than biological sex or ethnic group [83–87], suggesting that skeletal classification datasets may be appropriate for use in craniofacial identification.

There has not been consistency in the anthropometrical/anatomical points utilised for these datasets. This is, in part, due to the different modes of data collection; radiographs only enable measurement in the focal plane, ultrasound only enables measurement perpendicular to the surface of the bone (where the sound wave bounces back to the probe) and MRI may not allow some measurements when bone and space are difficult to distinguish. In addition, researchers have repeatedly ‘re-designed’ the measurement locations to facilitate practical utilisation of the datasets or to align with automation. These inconsistencies across datasets make comparisons between populations challenging and data combination more difficult.

3. Anatomical and anthropometrical standards by facial feature

3.1. The eyes

Positioning the eyeball within the orbit is one of the first steps in any facial depiction, and eyeball position is also critical when carrying out craniofacial superimposition for identification purposes. Eyeball size and location has a significant influence on facial proportions and humans are very sensitive to perception of eye displacement when recognizing familiar faces [88,89]. In addition, eyeball prominence

(anteroposteriorly) influences the morphology of the eyelids and how we perceive the set/openness of the eyes relative to the brow and cheeks. Research [90,91] shows that as little as 3 mm error in eye size/position can lead to a significant reduction in similarity levels and eyes are considered to be a primary distinguishing facial feature [92].

Mean eyeball and iris diameter measurements have been recorded from large numbers of subjects, populations and modes of collection including human dissection [93], cephalograms [94], CT [95], anthropometry [96], photogrammetry [97,98], and MRI [99], and there is consensus that the mean adult eyeball diameter is 24–25 mm, and the mean iris diameter is 12 mm. The mean neonatal eyeball diameter is recorded as 16 mm and the mean iris diameter in infants (up to 8 years) is 10.6 mm [100].

There are different published standards relating to the frontal view (superoinferior and mediolateral) position of the eyeball in the orbit. Traditionally [101,102], practitioners were advised to place the eyeball centrally within the orbit in the frontal view, with supporting research utilising palpation as the mode of data collection. Cadaveric dissection [103–106] and CT studies [95] reported 1–2 mm (or 3–5% of orbital width) superior and lateral divergence from the orbital centre and proposed proportional standards to predict superoinferior and mediolateral eyeball position (44% OBH and 58% OBB respectively); measured from the centre of the eyeball to the most superior/medial points on the orbital margin. These proportional standards were confirmed by a study utilising cephalograms from a different White European population [94], a cadaveric dissection study from South African subjects [107] and 3 modalities (cadaveric dissection, CT and CBCT) from a South African population [108]. A Korean study [109] utilising CBCT confirmed the mediolateral standard but found a more inferiorly placed eyeball in this cohort (56% OBH from superior orbital margin), suggesting that these standards may not be applicable to all populations.

There are also different published standards relating to the lateral view (anteroposterior) position of the eyeball in the orbit. Traditionally [101,102], in lateral view, practitioners were advised to place the cornea tangent to a line connecting the midpoints of the superior and inferior margins of the orbit, but these publications did not provide any research data to support this standard. A number of studies utilising cadaveric dissection [103,105], MRI [99] and radiography [110] of large databases of living subjects are in agreement that the anterior most point of the cornea falls, on average, 3.7–4 mm anterior to the tangent line connecting the midpoints of the superior and inferior orbital margins (or with the tangent line touching the flat plane of the iris rather than the cornea). Recent cephalogram [94] and CT [95] studies suggest that anteroposterior eyeball position can be predicted using a proportional standard (53% OBH) measured from deepest point on the lateral orbital margin. Since this practical standard does not rely on scale and is confirmed on different populations using different modes of data collection, it can be considered reliable for use by practitioners. Further research [99] suggests that eyeball prominence is directly related to orbital depth, with deep-set eyes associated with deep orbits and a heavy brow ridge.

There is anatomical consensus [93,103,104,111] that Whitnall’s tubercle and the anterior lacrimal crest can be identified to determine the position of the outer and inner canthi of the eye, as these anatomical structures are directly determined by the form and function of the eyelids and lacrimal apparatus. Human dissection studies illustrate that Whitnall’s tubercle is present on the lateral border of the orbit where the palpebral ligaments anchor the eyelids at this point [112,113]. However, the literature [110] does not agree on how far the outer canthus is located medial to Whitnall’s tubercle and one practitioner guide [114] even suggests the lateral canthus should be placed lateral to the tubercle. However, since Whitnall [115] clearly states that the lateral canthus lies medial to the tubercle, and all cadaveric dissection studies agree on this point, we can assume that the lateral placement was a reporting error. The distances medial to Whitnall’s tubercle suggested in the literature

Table 1
Reliable eye shape and position prediction standards.

Feature Standard	Populations	Modalities	References
Eyeball diameter Adult 24-25 mm Neonate 16 mm	Multiple	Cadaveric dissection; X-rays; CT; MRI	[93-95,99]
Iris diameter Adult 12 mm Infant (up to 8 years) = 10.6 mm	Multiple	Cadaveric dissection; Anthropometry	[96,97]
Eyeball position - frontal Superoinferior = 44% OBH Mediolateral = 58% OBB Measured eyeball centre to SOM/MOM	White European; Black South African	Cadaveric dissection; X-rays; CT; CBCT	[94,95,104-107]

OBH = orbital height; OBB = orbital breadth; SOM = most superior orbital point; MOM = most medial orbital point

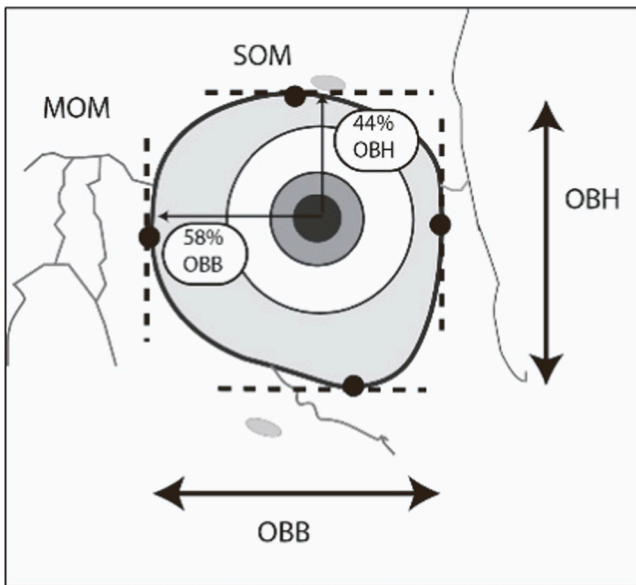
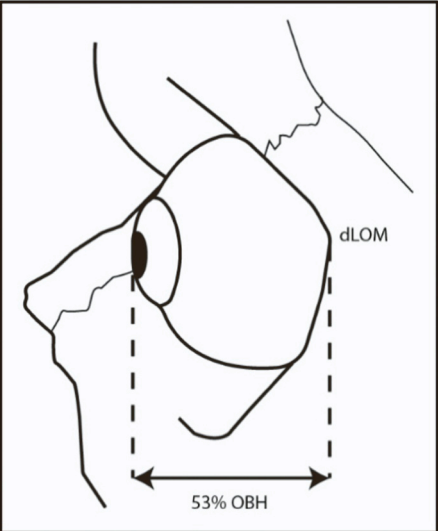
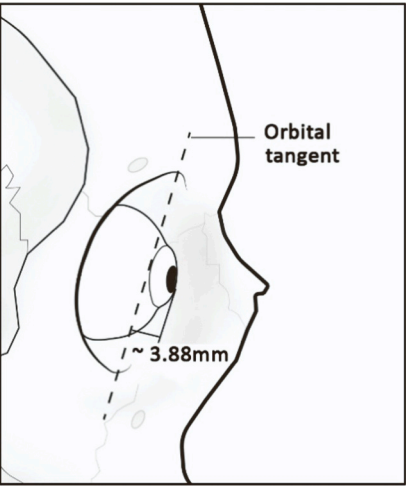
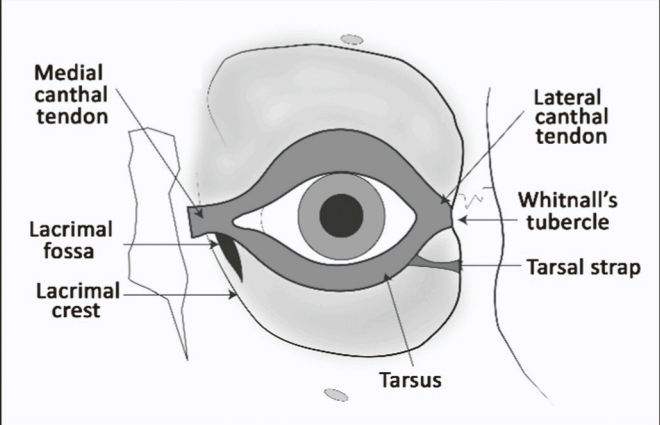


Image following Guyomarc'h et al. (2012)

Eyeball position - frontal Superoinferior = 56% OBH Mediolateral = 58% OBB Measured eyeball centre to SOM/MOM (as above)	Korean	CBCT	[109]
Eyeball position - lateral Distance of cornea from dLOM = 53% OBH dLOM = deepest point on lateral orbital margin	White European	Cadaveric dissection; MRI; X-rays	[94,95,99]

(continued on next page)

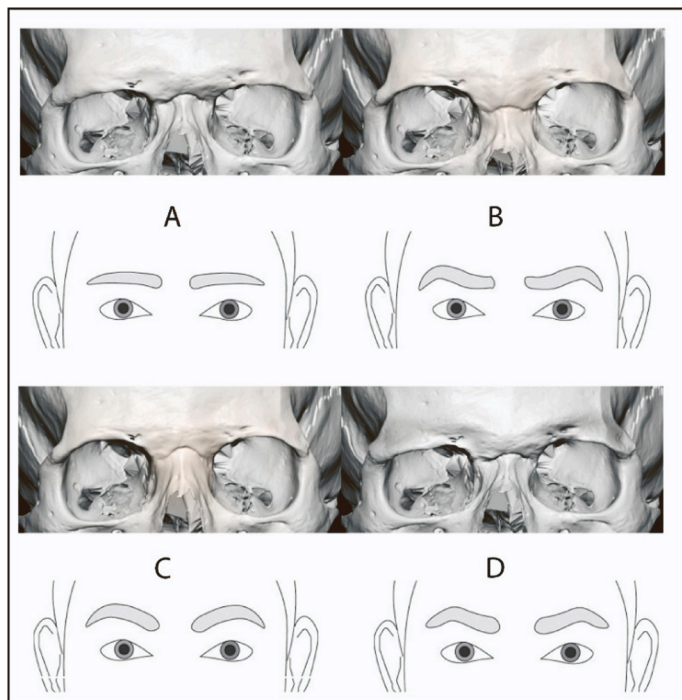
Table 1 (continued)

Feature Standard	Populations	Modalities	References
 <p data-bbox="135 766 574 819"><u>Image following Guyomarc'h et al. (2012)</u> Depth of orbital directly related to eyeball prominence.</p>			
 <p data-bbox="135 1351 542 1393"><u>Image following Wilkinson & Mautner (2003)</u></p>			
<p data-bbox="97 1372 239 1393">Medial canthus</p> <p data-bbox="97 1393 446 1415">8-12mm from medial orbital margin</p> <p data-bbox="97 1415 446 1436">Superior end of anterior lacrimal crest</p>	<p data-bbox="821 1372 957 1415">Turkish; White European</p>	<p data-bbox="1117 1372 1276 1393">Cadaveric dissection</p>	<p data-bbox="1300 1372 1388 1393">[124-126]</p>
			

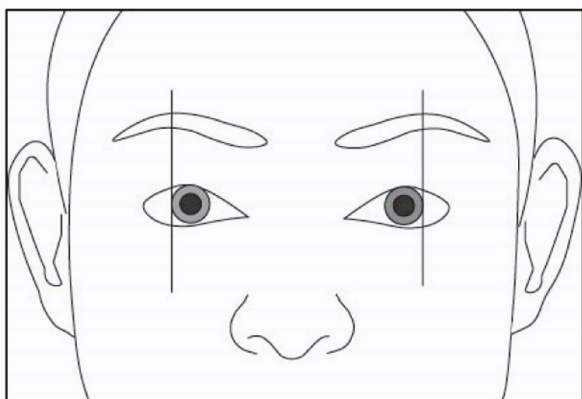
(continued on next page)

Table 1 (continued)

Feature Standard	Populations	Modalities	References
Lateral canthus Lies 5 mm medial to and at the same height as Whitnall's tubercle	White European; Black South African; Ethnic groups from USSR		[103,106,108,118-121]
Eyebrow pattern A) Strong brow ridge = low and straight eyebrow B) Weak brow ridge and low nasal root = wavy eyebrow C) Smooth brow and open orbits = arched eyebrow D) Strong brow ridge and thickened lateral suprorbital margin = triangular eyebrow	Ethnic groups from USSR	Ultrasound; Palpation	[120,122,131,132,138]



Superciliare (most superior part of the eyebrow) is located directly above the lateral border of the iris.



vary from 1 mm [116] to 13 mm [117], whilst cadaveric dissection studies seem to agree at 4–8 mm [106,110]. It is well established that orbit size varies widely, so it is unsurprising that there is disagreement relating to the mean distance between studies with small sample sizes from different populations. None of these cadaveric dissection studies had a sample size greater than 49 (and most utilised less than 10 cadavers) and there is evidence that the orbital structures are significantly affected by post-mortem changes [13]. However, the South African study [107] that utilised three different modalities (cadaveric dissection, CT and CBCT) and at least 30 subjects per modality, found consensus for

positioning the lateral canthus 4.5–5 mm medial to Whitnall's tubercle.

Traditionally, the superoinferior position (height) of the lateral canthus is thought to correspond to the position of the tubercle [118–120] and Stewart [121] noted that the bony attachments of the medial and lateral canthal tendons are almost horizontally aligned and parallel to the canthal axis. This relationship was confirmed in a cadaveric dissection study [105].

Human dissection demonstrates that the lacrimal sac sits in the lacrimal fossa surrounded anteriorly by the anterior lacrimal crest and draining fluid from the surface of the eyeball through ducts opening into

the inner canthus [93,103,104]. Therefore, the position of the medial canthus (inner corner of the eye) as lateral to the anterior lacrimal crest is not contested. However, the height of the inner canthus relative to the anterior lacrimal crest is contested, as is its position along the crest, with some researchers placing it at the inferior end [121], some centrally [122] and others placing it at the superior end [102]. Researchers have suggested distances from the medial orbital wall, and these also vary from 2 mm [119] to 5 mm [104], whilst other researchers suggest distances from the dacryon (the point of junction of the anterior border of the lacrimal bone with the frontal bone) as 10 mm [102] (although this latter measurement was shown to be inaccurate in a facial approximation accuracy study [123]). Cadaveric dissection studies [106,124–126] record the medial canthal ligament as 8–12 mm in length (from medial orbital margin to medial canthus) and attaching to the medial orbital wall at the superior end of the anterior lacrimal crest.

The shape of the eyelids is critical to assessments of facial attractiveness [127,128] and the eyes are a key feature utilised in face recognition [129,130]. There are a limited number of anatomical or anthropometrical standards relating to eyelid pattern. Some researchers [121,131] suggest that the shape of the upper eyelid echoes the shape of the supraorbital margin with the position of the upper eyelid crease determined by the deepest overhang at the supraorbital rim. These researchers also suggest that an open orbit, strong anterior lacrimal crest, and flat nasal root are indicative of an epicanthic fold. These observations were recorded using ultrasound [132] across a wide variety of ethnic groups from the former Soviet Union, but these standards have not been confirmed on other populations using different modalities.

The shape of the eyebrows is critical to face recognition [133–136] but there are limited anatomical or anthropometrical standards for the prediction of eyebrow pattern. Based on ultrasound and palpation studies on living subjects, researchers [121,122,131] suggest that the eyebrows echo the form of the superciliary arch, with strong brow ridges associated with lower straighter eyebrows and a strong brow ridge with an additional thickening at the lateral supraorbital margin associated with a triangular eyebrow shape. These researchers suggest that a weak brow ridge and low nasal root is associated with a 'wavy' eyebrow that starts at its medial end inferiorly to the supraorbital rim and rises to meet and follow the contour of the supraorbital rim. In addition, they suggest that an absent brow ridge and open orbital shape is associated with high arched eyebrows, more commonly seen in women and Central East Asian populations. Although these observations were made across a wide range of different ethnic groups from the former Soviet Union using ultrasound and palpation [132], these standards have not been confirmed on other populations using different modalities. A CT study of 180 Koreans [137] provided data to estimate the position of the eyebrow using orbital width and height. The study revealed that the morphology of the orbit had more influence on the position of the superior margin than the inferior margin of the eyebrow. In addition, regression equations were shown to better predict the middle part of the eyebrow, whilst the morphology of the orbital margin showed limited correlation to both ends of the eyebrow. One guideline that has been suggested is that superciliare (most superior part of the eyebrow) is located directly above the lateral border of the iris and this standard was confirmed in a photogrammetric study of 128 Australian subjects [138] showing only small errors in position (1 mm female, 5 mm male). However, this standard is not very practical for facial depiction from skeletal assessment, as the eyeball position is also estimated.

The most reliable standards for the prediction of eye shape and position for craniofacial identification are summarised in Table 1.

3.2. The nose

Every facial component is important for facial appearance, but the nose seems to have a special significance. It has a central position; it is often the most prominent part of the face; and it has cultural, ethnic, symbolic, and psychological significance [139]. As little as a 2 mm

change to nasal proportions has been shown to have a significant effect on similarity ratings [91] and research [140,141] indicates that the nose is a relatively important feature in face recognition.

Traditionally, the nose was always a difficult feature of the face to predict by analysis of skeletal structure, as it is mostly cartilaginous. Recent correlation studies utilising Chinese CBCT [142], Korean CT [143] and South African CT data [144] and cadaveric dissection research [145] suggest that the soft tissues of the nose are directly related to the skeletal structure of the nasal aperture. Since the 1950 s, many researchers have investigated and developed different methods to predict nasal projection and shape based on the skeletal portion of the nose.

One of the most persistent and practical methods is known as the 'two-tangent method' devised by Gerasimov [131] in the 1950 s; the most prominent point on the nasal tip is found at the intersection between a projected line following the direction of the nasal spine at the base of the nasal aperture and a second line following the direction of the most distal portion of the nasal bones (last third or less). This method has been tested numerous times on various populations using different modalities including 122 cephalograms from a White European population [146], CT scans from a Turkish population [147], CT scans from a White and Black US population [148], 66 CT scans from a Scandinavian population [149], cephalograms from a White Australians [150], cadaveric dissection of 49 South African subjects [106], 34 cephalograms from a Chilean population [151] and cephalograms from US children [152]. The results of this research are varied; for adults, several studies [146–148,151] support the use of this method, whilst others [106,149,150] suggest a consistent overestimation of nasal projection. For children, one study found this method to be reliable for boys, but not girls [152], although the sample size was small. Adaptations and supplementary guidance around the two-tangent method have been suggested by researchers [148,153,154], and these new methods have produced reliable results when tested across populations [2,146,147,149,150,155,156].

Krogman [157] developed a method to predict nasal projection that has been widely utilised in the United States; the average soft-tissue depth at midphiltrum is transferred to a line following the direction of the nasal spine, and the length of the nasal spine, from the junction with the vomer to the tip, is tripled and added to the tissue depth. However, this method has been tested on 122 cephalograms from a White European population [146], 34 cephalograms from a Chilean population [151] and 59 cephalograms from an Australian population [150], and each study found this method to be highly inaccurate. Other methods found to be inaccurate and/or impractical when evaluated by other researchers include standards suggested by George [158], Macho [159] and Stephan et al. [150].

A large-scale study [160] using 600 radiographs from a Brazilian population suggested that a ninety-degree angle from prosthion to nasion will predict the most prominent point on the nasal tip, and this standard was confirmed in two other studies using CT data from Brazilian populations [161,162].

Recently proposed standards have been developed from Japanese [84,163] and Thai [164] subjects using cephalograms and CBCT data respectively, but these studies were only evaluated on the same population and have not been tested using different modalities.

There are a few standards relating to nasal width estimation. Gerasimov [131] suggested, based on cadaveric dissection research, that the widest part of the nasal aperture is three-fifths of the overall width of the soft nose and a study of 55 Romanian subjects using CT data [165] confirmed a close relationship between the maximum nasal aperture width and the maximum nasal width, the bone being a significant predictor for the morphology of soft tissue. The three-fifths standard was tested, using CT data from 79 White, Black and Asian US [148] subjects and 5 CT scans from Belgian subjects, and was found to be accurate regardless of ethnic group. However, a study of 250 Brazilian subjects [161] using CT data found no correlation between nasal width and nasal

Table 2
Reliable nose shape and profile prediction standards.

Feature Standard	Populations	Modalities	References
Nasal projection 1. Most prominent nasal point = intersection of line following distal portion of nasal bones and line following the direction of the nasal spine (as if nasal spine is an arrowhead)	White European (1,2); Turkish (1,2); Chilean (1,2); White, Black and Asian US (1,2); Australian (3); Brazilian (3)	X-rays; CT	[147,148,150,153,155,156,160-163]

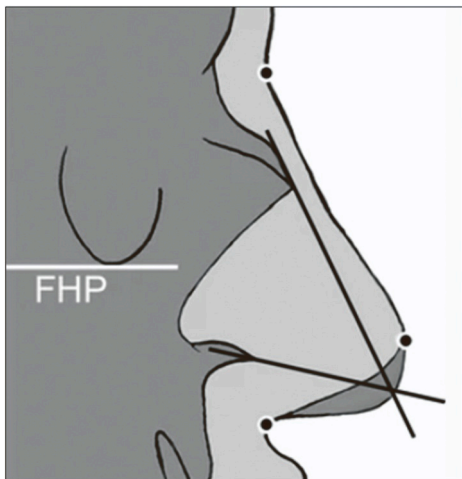


Image following Rynn et al. (2010)
FHP = Frankfurt Horizontal Plane

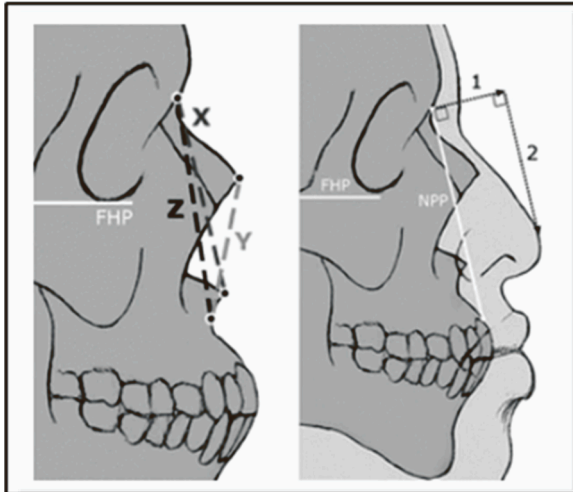
2. Three craniometrics measured to predict six soft tissue dimensions:
X = nasion-acanthion; Y = rhinion-subspinale; Z = nasion-subspinale;

(continued on next page)

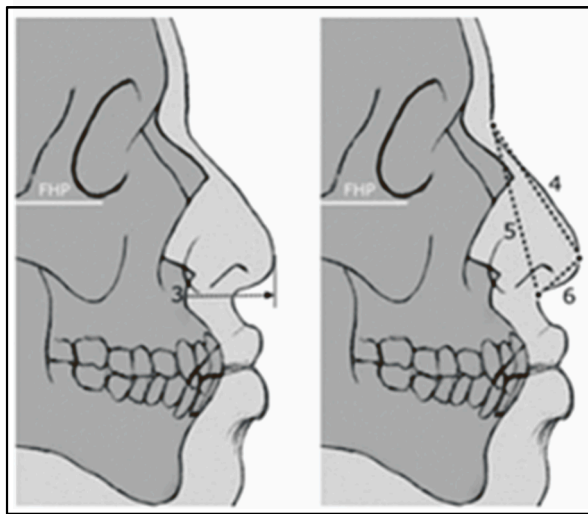
Table 2 (continued)

Feature Standard	Populations	Modalities	References
------------------	-------------	------------	------------

1 = pronasale anterior projection from NPP;
 2 = pronasale height down from nasion in NPP;
 3 = pronasale projection in FHP;
 4 = nasal length; 5 = nasal height; 6 = nasal depth



$1 = 0.83Y - 3.5$	$5 \text{ for females} = 0.63Z + 17$
$2 = 0.9X - 2$	$5 \text{ for males} = 0.78Z + 9.5$
$3 = 0.93Y - 6$	$6 \text{ for females} = 0.5Y + 1.5$
$4 = 0.74Z + 3.5$	$6 \text{ for males} = 0.4Y + 5$



Images following Rynn et al. (2010)

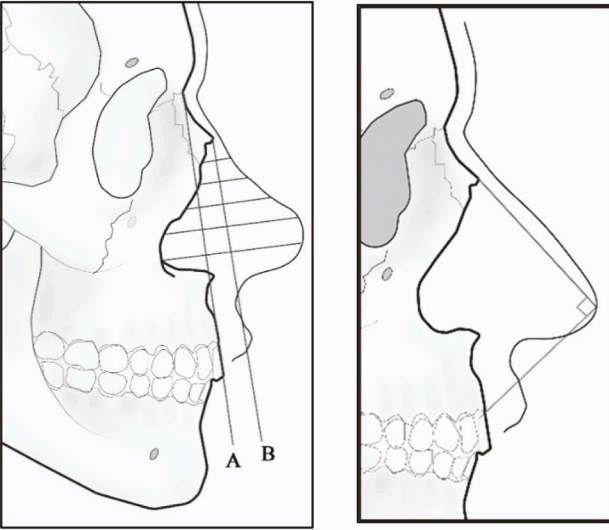

FHP = Frankfurt Horizontal Plane

NPP = Nasion-Prosthion Plane

3. Nasal profile

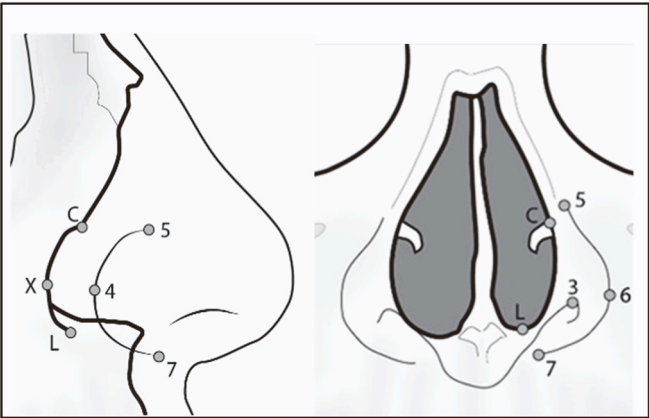
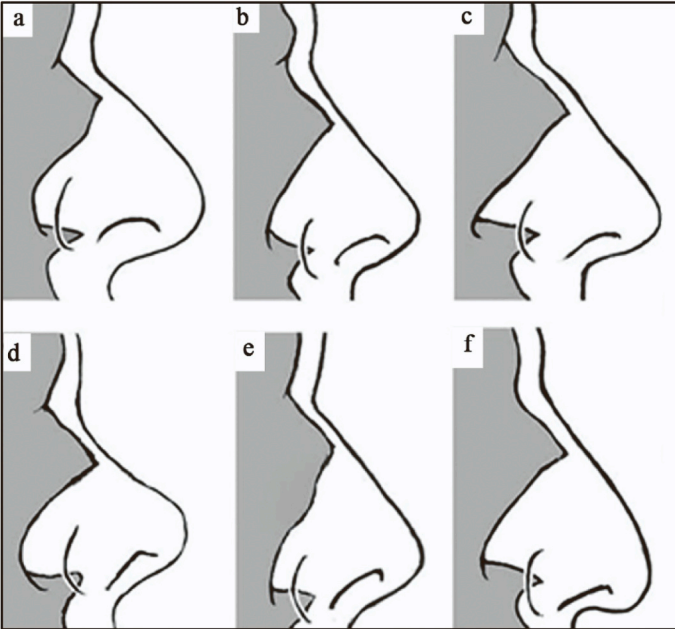
(continued on next page)

Table 2 (continued)

Feature Standard	Populations	Modalities	References
 <p data-bbox="119 761 730 787"><u>Images following Prokopec & Ubelaker (2002); Tedeschi-Oliveira et al. (2016)</u></p> <p data-bbox="119 787 730 812">A = nasion-prosthion; B = parallel to line A touching rhinion</p> <p data-bbox="119 812 730 838">Distance from line B to nasal profile mirrored other side of line with 2mm addition to create nasal profile</p> <p data-bbox="119 838 730 863">Rhinion–Pronasale–Prosthion = 90° angle</p> <p data-bbox="119 863 730 889">Nasal width</p> <ol data-bbox="119 904 730 1042" style="list-style-type: none"> Nasal width = 5/3 maximum nasal aperture width (NAW) Inter-alar distance (max. nasal width) = 76% inter-canine distance (ICD) Male nasal width = $18.035 + 0.44400 \times \text{ICD}$ Female nasal width = $17.390 + 0.42393 \times \text{ICD}$ ICD measured between most prominent points on canine alveolar bone at level of subspinale Male nasal width = $23.77 + (\text{NAW} \times 0.42) + 3.31$ <p data-bbox="119 1042 730 1068">NAW = nasal aperture width</p> <p data-bbox="119 1106 730 1132">Nasal tip shape</p> <p data-bbox="119 1132 730 1157">Nasal tip contour mirrors nasal bone contour with 60 degree dorsal head tilt</p>			
	<p data-bbox="989 744 1165 1170">Ethnic groups across USSR (1); US White, Black and Asian (1); White European (1); Romanian (1); India (2); Malaysia (2); Saudi Arabia (2); Brazilian (2,3,4) North American; European</p>	<p data-bbox="1165 744 1308 1170">Cadaveric dissection; CT</p>	<p data-bbox="1308 744 1495 1170">[122,131,132, 148,161,165,168, 175]</p> <p data-bbox="1308 1106 1495 1132">[176,177]</p>
 <p data-bbox="119 1713 730 1738">Other nasal morphology</p> <p data-bbox="119 1738 730 1764">Nasal alae lie approx. 5 mm anterior and inferior to aperture border</p> <p data-bbox="119 1764 730 1789">Superior part of alar groove is at the same height as the inferior turbinate (christa conchalis)</p> <ol data-bbox="119 1789 730 1904" style="list-style-type: none"> 3 = most superior point on nostril border 4 = most posterior point on alar groove, or alar crest point (ac) 5 = most superior point on alar groove 6 = most lateral point on ala 7 = most inferior point on alar curvature, or subalare (sbal) <p data-bbox="119 1904 730 1930">C = inferior turbinate, or conch</p> <p data-bbox="119 1930 730 1955">X = most posterior point on lateral border of piriform aperture (PLB)</p> <p data-bbox="119 1955 730 1981">L = lowest point on aperture border</p>			<p data-bbox="1308 1713 1495 1751">[122,131,132, 148]</p>
	<p data-bbox="989 1702 1165 1957">Ethnic groups across USSR; European; White, Black and Asian US</p>	<p data-bbox="1165 1702 1308 1957">Cadaveric dissection; Ultrasound; CT data</p>	

(continued on next page)

Table 2 (continued)

Feature Standard	Populations	Modalities	References
			
<p><u>Image following Rynn et al. (2010)</u> Deviation of bony nasal septum corresponds to contralateral nasal deviation Corresponding bony (gray) and soft nasal profiles. a = Rounded aperture and nasal tip. b = Average aperture and nasal tip. c = Sharply angled aperture and nasal tip. d = Rounded aperture and nasal tip, upturned nose. e = Angled aperture and nasal tip, upturned nose. f = Angled aperture and nasal tip, down-turned nose</p>			
			
<p><u>Image following Rynn et al. (2010)</u> Nasolabial Crease/Fold (NLC/F) pattern</p> <ul style="list-style-type: none"> • Origin at upper edge of alar margin above maxillary first molar. • NLC/F is more prominent when canine fossa is deep and when midface profile is strong. • Canine fossa shallow < 3 mm, moderate < 6 mm and deep if >6 mm. • Upper part formed by concavity of levator muscles and terminates at projection of second molar. 	<p>Ethnic groups across USSR; US ethnic groups; European</p>	<p>Palpation; Ultrasound; Cadaveric dissection; Skulls with AM face images</p>	<p>[120,131,181]</p>

aperture width and this suggests that the standard may not be applicable to all populations.

Krogman's standard for nasal width prediction [157] has been utilised and promoted by practitioners across the United States [102]. This standard advised the addition of 10 mm to the maximum nasal aperture

width for White Europeans, and 16 mm for Africans, but has been shown to be inaccurate [166] and not applicable to many other populations. A CBCT study of 108 Thai subjects [167] found that the distance between the infraorbital foramina correlated to 75% nasal width, but this has not been confirmed by any other research.

Standards for nasal width also utilise the teeth and CT and ultrasound studies [132,148] from different populations have found that inter-canine distance is correlated to nasal width with regression formulae suggested for practitioners [123]. Orthodontic literature [168], using facial images and dental casts of 81 Brazilian subjects, confirms the relationship between inter-alar distance (maximum nasal width) and the maxillary teeth, suggesting inter-alar distance equals 76% inter-canine distance. This is supported by other orthodontic research on multiple populations [169–174] and inter-alar width is a routinely used method in the selection of upper anterior teeth. One study utilising 246 CT scans of Brazilian subjects [161] found no direct correlation between nose width and any variables of the piriform aperture nor between inter-canine distance and nasal width, and the CBCT study of 108 Thai subjects [167] found that intercanine distance was equal to nasal width; these studies suggest that these anatomical standards may not be applicable to all populations. One study of 96 Brazilian subjects using CBCT data [175] found that nasal width was associated with the lower width of the piriform aperture, sex, skeletal facial height, and age. This study suggested multiple linear regression equations for male subjects and a further study [161] using CT scans of 246 Brazilian subjects confirmed this prediction method.

A study of 25 CT scans from a US population [176] found that the contour of the tip of the soft nose follows the contour of the superior portion of the nasal aperture and this standard was supported by further study of 103 CT scans from a German population [177]. Several researchers have found, from ultrasound [132] and cadaveric dissection [131] studies of ethnic groups from across the former Soviet Union, that the nasal alae lie approximately 5 mm anterior and inferior to the aperture border with the superior part of the alar groove at the same height as the inferior turbinate (crista conchalis) [123] and the lateral profile of the nasal aperture border mirrored in shape (but not scale) to the nasal profile. These standards were evaluated in a study of 79 CT scans of White, Black and Asian US subjects and 5 CT scans of Belgian subjects [148], and confirmed as applicable across populations, along with a new finding that any deviation of the bony nasal septum will correspond to a contralateral nasal deviation.

All the selected nasal standards were further re-evaluated in a blind accuracy study [148] using 12 skulls from a German population, on which the noses were reconstructed and compared to the ante-mortem images of the subjects through resemblance ratings by 50 volunteers. Overall, 81% of volunteers indicated that the predicted noses exhibited no/slight differences from the actual noses of the subjects.

Some researchers have suggested that the presence or absence of a nasolabial crease/fold (NLC/F) can be determined by skeletal assessment. A cadaveric dissection study of 4 subjects [178] classified the shape of the NLC/F as concave, straight or convex, but the lack of demonstrative models has led to inconsistency in the classification. For example, two further cadaveric dissection studies [179,180] agreed that NLC/F is straight, concave or convex, but recorded opposite directions for the latter two classifications. A convex NLC/F was the highest reported at 60%, followed by straight (30%) and convex (10%). Palpation and ultrasound research [121] places the origin of the NLC/F at the upper edge of the alar margin above the maxillary first molar and consider the prominence of the fold as dependent on the depth of the canine fossa, the angle of horizontal profiling, the protrusion of the frontal surface of the cheekbones, and the presence of teeth. The canine fossa is considered shallow if it is less than 3 mm, moderate if less than 6 mm and deep if 6 mm or more, and the NLC/F is more prominent when the canine fossa is deep and when the midface profile is strong [121]. The NLC/F is also prominent in edentulous individuals. Gerasimov [131] mentions that the upper part of the fold is formed by the concavity of the levator muscles and that the depth of the canine fossa is correlated with the depth of the fold in the midportion and is terminated at the central portion of the levator anguli oris muscle. He also states that the fold starts from the edge of the nasal alae above the crista conchalis, continues along the canine fossa and terminates at the

projection of the second molar. The NLC/F is directed inwards towards the lower jaw. In young individuals, the fold is shapeless with little outline and increases as a person ages. A study [181] of the William Bass Collection at the University of Tennessee, using 83 subjects with skull photographs and ante-mortem facial images, found that the NLC/F related to the canine fossa depth in 95% of the subjects. The NLC/F prediction was then tested using 9 skulls with ante-mortem images from the Helmer Collection, and results showed 67% correct prediction. However, the researchers recorded difficulty in distinguishing between a full or nasal portion only NLC/F based on both skeletal and facial assessments.

Table 2 summarises the most reliable standards for nasal shape prediction for craniofacial identification.

3.3. The mouth

The mouth is a key feature involved in face recognition – both human and automated [136,182,183]. Although shown to be less important than the eyes for familiar face recognition [135,184,185], the mouth provides crucial lower face proportions and profile structure [89].

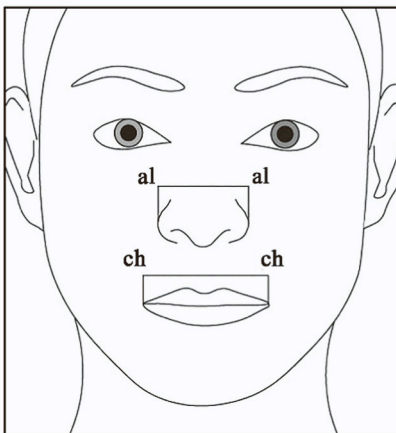
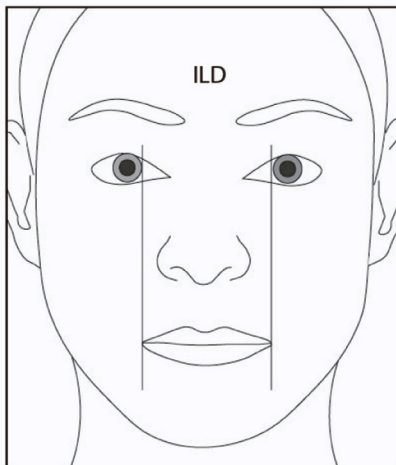
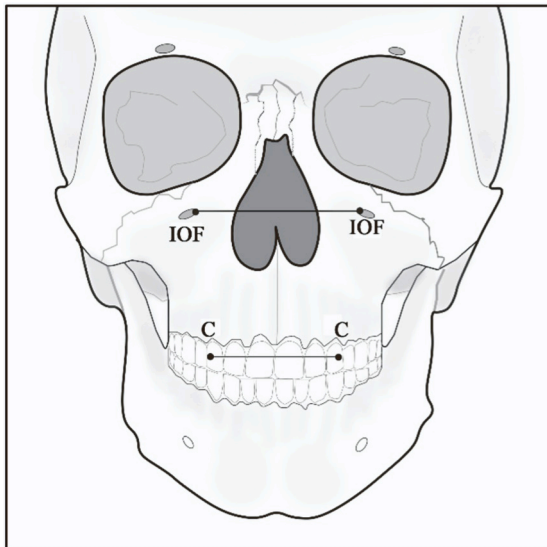
Orthodontic and maxillofacial literature agree that lip shape and dental pattern are directly related, and facial profile and lower face shape will be significantly changed as a result of orthodontic treatment [186–189]. A number of studies [190–195] have demonstrated a significant correlation between lip shape and size and dental prominence, dental occlusion, and mouth width.

There are many mouth width standards available to practitioners and some of these standards have been evaluated on different populations using different modalities. In a cadaveric dissection study of fifty Korean subjects [196], the infraorbital foramina lay within the same vertical plane as the cheilions (corners of the mouth) in 50% of cases, and the distance between the infraorbital foramina overestimated actual mouth width by only 0.6 mm. A further cadaveric dissection study on 9 Australian subjects [197] confirmed the infraorbital foramina are a reliable prediction for the position of the mouth corners. Intercanine distance has also been used to predict mouth width (intercanine distance = 75% intercheilion distance) and this standard was established in a photogrammetric study of 93 Australian subjects [198] and then confirmed using cadaveric dissection of 9 further Australian subjects [196]. However, a cadaveric dissection study of 49 South African subjects [106] found that intercanine distance was closer to 60% mouth width. It is worth noting that these guidelines were obtained and re-evaluated using cadaver data or from faces in supine positions; causing many shortcomings, as gravity as well as post-mortem dehydration and distortion negatively impacts the reliability of measurements. Anthropometric studies of 168 Arab [199] and 200 Indian subjects [173] confirmed the 75% rule, but a CBCT study of 120 black and 39 white southern African adults [200] found a mouth width estimation error of approx. 3.7 mm. The researchers suggested demographic-specific percentages (77% for black subjects) and demographic-specific regression formulae, but these also recorded an error of more than 3 mm for mouth width estimation. Finally, two CBCT studies, one of 108 Thai subjects [167] and one of 322 Brazilian subjects [201], and an anthropometric study of 110 Saudi subjects [202] found that intercanine distance was correlated to mouth width, but that the standard should be adjusted to 80% mouth width for Brazilian and Saudi subjects and 82% mouth width for Thai subjects. The Thai study also found that infraorbital foramina distance reliably indicated mouth width. In contrast, a CBCT and three-dimensional surface scan study of 180 Chinese subjects [203] found no relationship between intercanine distance and mouth width.

Interalar width has also been shown to be positively correlated to mouth width. Anthropometric studies of 200 Nigerian [204], 168 Arab [198], 200 Indian [173], 100 Indian [205] and 110 Saudi subjects [201] found interalar width was 73%, 68%, 76%, 76% and 70% mouth width respectively. Where there were sex differences these were not consistent

Table 3
Reliable mouth shape prediction standards.

Feature Standard	Populations	Modalities	References
Mouth width (chelion-chelion) Mouth corners are directly inferior to: <ul style="list-style-type: none"> • infraorbital foramina (IOF) • medial borders of the iris (ILD) intercanine distance (C-C) = 75-80% interchelion distance (ch-ch) interalar distance (al-al) – 68-76% mouth width (ch-ch)	Korean; Australian; South African; Indian; Arab; Thai; Brazilian; Nigerian; Saudi; British	Cadaveric dissection; Photographs; Anthropometry; CBCT; 3D surface scans	[1,107,167,173,196-204,206]



(continued on next page)

Table 3 (continued)

Feature Standard	Populations	Modalities	References
Oral fissure position	US; Ethnic groups across USSR	Cephalograms; Anthropometry	[118,132,158,207]
<ul style="list-style-type: none"> Fissure positioned at level of lower quarter of maxillary central incisors. Fissure moves up for class II malocclusion to reveal maxillary incisors. Fissure moves down for class III malocclusion to occlusal line. 			
Lip thickness	British (1,2); US (3); Central European (3)	Anthropometry; Cephalograms	[158,206,209]
1. White Europeans: <ul style="list-style-type: none"> Upper lip thickness = 0.4 + 0.6(upper teeth height) Lower lip thickness = 5.5 + 0.4(lower teeth height) Total lip thickness = 3.3 + 0.7(total teeth height) Lip shape has proved more difficult to estimate 2. Indian subcontinent: <ul style="list-style-type: none"> Upper lip thickness = 3.4 + 0.4(upper teeth height) Lower lip thickness = 6 + 0.5(lower teeth height) Total lip thickness = 7.2 + 0.6(total teeth height) Lip shape has proved more difficult to estimate 3. Upper lip border = upper 1/4 maxillary central incisor Lower lip border = lower 3/4 mandibular central incisor			
Philtrum	South African	CBCT	[200]
Distance between maxillary central-lateral incisor junctions = Cupid's bow width			

Table 4
Reliable ear prediction standards.

Feature Standard	Populations	Modalities	References
Ear position	Korean; European; Indian; Bulgarian	Cephalograms; CT	[221-223, 236,237]
<ul style="list-style-type: none"> External ear canal = approx. 9.5 mm inferior and 2 mm anterior to porion Upper (superior) edge of ear located at the eyebrow tail (FHP) Lower (inferior) edge of ear located at upper lip level (FHP) 			
Ear dimensions	Ethnic groups across USSR (1,2); White European (1,2); Indian (3,4); Chinese (3,4)	Anthropometry; Photogrammetry	[131, 225-230,233, 234]
1. Nose length + 10 mm = ear height 2. Ear breadth = 57% ear height 3. Ear inclination = 20° angle from vertical or 4. Ear inclination = 15° more vertical than dorsal angle of nose			

across the studies.

The most reproducible anatomical standard for the prediction of mouth width appears to be the interlimbus distance (between the medial borders of the iris) and this has been demonstrated in 96 British [206] and 123 Australian [1] populations using anthropometry and photogrammetry respectively. However, this is not a very practical standard for use in facial depiction from skeletal assessment since the eyeball size and position are also estimated. Other mouth width standards that have been shown to be unreliable are interpupillary distance [196,205] and mental foramina [196] distance.

Researchers have also attempted to produce standards for estimating lip thickness. An anthropometrical study of 191 British subjects [205] found that lip thickness was positively related to the height of the teeth and regression equations for White Europeans and Asians from the Indian subcontinent were suggested (see Table 3). A South African CBCT study of 124 black and 29 white adults [207] developed a series of regression equations, and found that face height produced the strongest correlation with lip height. However, these equations have not been tested to date.

The Russian school [131,209] place the upper lip margin on a level

with the upper margin of maxillary central incisor crowns, and the lower lip margin on a level with the lower margin of mandibular central incisor crowns. This is in agreement with several researchers [101,102] who state that the lip thickness is equal to the vertical distance of the upper cementum-enamel junction to the lower cementum-enamel junction. However, this is in contrast to other practitioner guidelines [158] that place the upper lip border at the same level as the upper quarter mark of the maxillary central incisor and the lower lip border at the same level as the lower three-quarter mark of the mandibular central incisor. All these lip thickness standards were reevaluated on 86 subjects from central Europe [208] using lateral head cephalograms and the regression equations [205] were found to be the most accurate for female subjects and the latter standard [158] for male subjects.

The position of the oral fissure has been the subject of much debate in the literature. Traditionally, practitioner standards stated that the mouth fissure is positioned at the level of the midpoint of the upper incisor crowns [119] or level with the cutting edge of the upper central incisors [206]. One study of 54 lateral craniographs of US subjects [158] placed the oral fissure in between these two extremes at the lower third (female mean) or quarter (male mean) of the maxillary central incisors. Some researchers relate the oral fissure position to the type of incisor occlusion with a lower fissure for class III and a higher fissure for class II malocclusions [132,210]. All these oral fissure location standards were reevaluated on 86 subjects from central Europe [209] using lateral head cephalograms and the lower quarter of the maxillary central incisors proved to be the most accurate estimation for males and females.

Some researchers [121] have suggested that the width of the philtrum column at the upper lip can be estimated as the distance between the midpoints of the maxillary central incisors. This standard was tested in a CBCT study of 159 South Africans [199] and the Cupid's bow was found to be greater than the maxillary central incisor measurement by 5–7 mm. However, the distance between the maxillary central-lateral incisor junction width proved to be a better estimate of the Cupid's bow width, being only 1–2 mm larger.

There are many studies [211–218] that demonstrate significant changes to lip shape and position (e.g., reduced lip thickness and lowering of oral fissure) with advanced age in adulthood, due to the effects of gravity, tooth loss, reduction of skin elasticity, and subcutaneous fat redistribution. It is likely that these age-related changes are more significant than any intra-population variation.

Table 3 summaries the most reliable standards for mouth shape prediction for craniofacial identification.

3.4. The ear

The relationship between the external ear and the skull is not well understood. Early 19th century cadaveric dissection studies [219,220] suggested that the cartilaginous opening of the ear is placed approx. 5 mm posterior and superior to the external auditory meatus. However, more recent studies of CT scans of 67 Korean subjects [221] and cephalograms of 22 [222] and 160 [223] European subjects have recorded an inferior distance of approx. 9.5 mm from the opening of the porion (most superior and outer bony surface point of external auditory meatus) to the external ear and approx. 2 mm anterior distance. The latter study claims that the position of tragus (fleshy part over the external ear opening) relative to the skeletal structures could only be broadly approximated due to the wide range of inferior distances (1–20 mm).

An anthropometric study of 462 Tajiks [131] (an ethnic group from the former USSR) suggested that ear length/height 'roughly' approximates to the height of the nose measured from the base to the glabella and another anthropometric study of 161 Bulgarians [224] confirmed this, whilst acknowledging a 2 mm underestimation. This in turn was shown to be inaccurate by several anthropometric studies of US groups [225,226] that recorded 95% of subjects with a nose length 10 mm less than ear height. A more recent large-scale study using CT scans of 78 Australian living subjects, 2190 three-dimensional facial scans of British subjects and anthropometric measurements of 1328 White and 1010 Black US cadavers and 47 Australian living subjects [227] further indicated this was an unreliable standard. This large-scale study rejected some other suggested standards that the axis of the ear was parallel to the ascending ramus of the mandible [218] and the breadth of the ear was equal to half of its length [131], but confirmed previous research [224,228–230] suggesting that ear breadth and height are correlated with breadth-to-height ratio of approx. 0.57 and found a small correlation between the mastoid process length and the breadth of the ear [131].

Research utilising more than 200 skulls and related ante-mortem images from the former Soviet Union [121] suggested that the direction of the mastoid process (skull in Frankfurt Horizontal) indicates whether or not the ear has an adherent or lobed form; with a forward pointing mastoid process indicating a lobed ear and an inferiorly pointing mastoid process indicating an attached ear. There are contrasting reports on the reliability of this rule; a CT study of 78 Australian subjects [226] found no correlation between mastoid direction and earlobes, whereas a study utilising ante-mortem images and skulls from 66 US subjects [231] confirmed mastoid direction as 91% accurate at predicting lobes (40 out of 44 subjects) and 64% accurate at predicting adherent ears (14 out of 22 subjects). However, the criterion for mastoid process direction was not consistent across these studies (change in direction or overall direction?) and this feature requires further research and evaluation.

Some researchers [121] have suggested that a strongly developed supramastoid crest indicates upper ear projection (from the side of the head) whilst a rough external surface of the mastoid process indicates lower ear projection (from the side of the head). There are also contrasting reports on the reliability of these rules; the CT study of 78 Australian subjects [226] found no correlation between mastoid pattern and ear projection, whereas the study utilising ante-mortem images and skulls from 66 US subjects [230] confirmed mastoid pattern as 77% accurate at predicting ear prominence (27 out of 35 subjects) and 81% accurate at predicting non-prominence (25 out of 31 subjects). This feature requires further research and evaluation.

A review of artistic guidelines pertinent to surgical plastic facial surgery [232] stated that the main axis of the ear is parallel to the angle of the dorsal ridge of the nose. This rule was invalidated by several anthropometric studies [224,225,233,234] that found ear inclination 15° more toward the vertical than the dorsal angle of the nose. Further artistic guidelines for plastic surgery [235] state that the ear sits back

one ear-length (approx. 7 cm) from the lateral orbital rim and with the top of the ear level with the eyebrow and inclined approximately 20 degrees. Anthropometrical studies of 700 Indian subjects [236] and 450 Bulgarian subjects [237] confirmed that the position of the superior edge of the ear was most commonly located on a level with the eyebrow tail, while the inferior edge of the ear was located level with the upper lip (in Frankfurt Horizontal Plane).

Table 4 summarises the most reliable standards for ear shape prediction for craniofacial identification.

4. Conclusion

Practitioners often struggle to identify the most appropriate craniofacial standards and understand their reliability and reproducibility. This paper clarifies optimal standards for the relationship between the soft and hard tissues of the face by reviewing previous research; the conclusions reached are based on sample size, number of studies, diversity of populations, subject status (cadaver/living) and mode/s of data collection. It is hoped that this paper can provide some direction for practitioners and present areas where more research would be beneficial. Future research should aim to include diverse cohorts to establish reproducibility across a global population, and under-studied areas of the face remain at the eyelids, ears, and the vermilion line of the lips.

Declaration of Competing Interest

The authors declare no conflicts of interest.

Acknowledgements

This research did not receive any specific grant from funding agencies in the public, commercial, or not-for-profit sectors.

References

- [1] C.N. Stephan, Anthropological facial reconstruction—recognizing the fallacies, 'unembracing' the errors, and realizing method limits, *Sci. Justice*: J. Forensic Sci. Soc. 43 (4) (2003) 193–200.
- [2] R.A. Paim Strapasson, L. Stocco Baccarin, R.F. Haltenhoff Melani, Forensic facial reconstruction: a systematic review of nasal prediction techniques, *J. Forensic Sci.* 64 (6) (2019) 1633–1639.
- [3] F. Cummings, Charles Bell and the anatomy of expression, *Art. Bull.* 46 (2) (1964) 191–203.
- [4] Duchenne, G.B. de Boulogne. 1862. Edited and translated by Cuthbertson, R.A. 1990. The mechanism of human facial expression. Cambridge University Press.
- [5] C. Darwin, P. Prodger, The Expression of the Emotions in Man and Animals, Oxford University Press, USA, 1998.
- [6] C.N. Stephan, B. Meikle, N. Freudenstein, R. Taylor, and, P. Claes, Facial soft tissue thicknesses in craniofacial identification: data collection protocols and associated measurement errors, *Forensic Sci. Int.* 304 (2019) 109965.
- [7] M. Khatri, D. Misra, S. Rai, A. Misra, Unfolding the mysterious path of forensic facial reconstruction: review of different imaging modalities, *MAMC J. Med. Sci.* 3 (3) (2017) 120.
- [8] D.G. Jones, Reassessing the importance of dissection: a critique and elaboration, *Clin. Anat.*: Off. J. Am. Assoc. Clin. Anat. Br. Assoc. Clin. Anat. 10 (2) (1997) 123–127.
- [9] R.B. Gunderman, P.K. Wilson, Exploring the human interior: the roles of cadaver dissection and radiologic imaging in teaching anatomy, *Acad. Med.* 80 (8) (2005) 745–749.
- [10] L.J. Rizzolo, and, W.B. Stewart, Should we continue teaching anatomy by dissection, *Anat. Rec. Part B: N. Anat.*: Off. Publ. Am. Assoc. Anat. 289 (6) (2006) 215–218.
- [11] M. Lee Goff, Early post-mortem changes and stages of decomposition in exposed cadavers, *Exp. Appl. Acarol.* 49 (2009) 21–36.
- [12] M.A. Clark, M.B. Worrell, J.E. Post-mortem changes in soft tissues, in: W. D. Haglund, M.H. Sorg (Eds.), *Forensic Taphonomy: The Post-mortem Fate of Human Remains*, CRC Press, 1997, pp. 151–164.
- [13] C.M. Wilkinson, A. Tillotson, Post-mortem prediction of facial appearance. *Cpt.* in: C.M. Wilkinson, C. Rynn (Eds.), *Craniofacial Identification*, Cambridge University Press, 2012, pp. 166–183.
- [14] H. Hadi, C.M. Wilkinson, The post-mortem resilience of facial creases and the possibility for use in identification of the dead, *Forensic Sci. Int.* 237 (2014) 149–e1.

- [15] E. Simpson, M. Henneberg, Variation in soft-tissue thicknesses on the human face and their relation to craniometric dimensions, *Am. J. Phys. Anthropol.: Off. Publ. Am. Assoc. Phys. Anthropol.* 118 (2) (2002) 121–133.
- [16] I.C.S. Galdames, M.C. López, D.A.Z. Matamala, F.J.P. Rojas, S.R.T. Muñoz, G. Suazo, L. Cantin, M. Zavando, R. Perez, M. Torres, Comparisons in soft-tissue thicknesses on the human face in fresh and embalmed corpses using needle puncture method, *Int. J. Morphol.* 26 (1) (2008) 165–169.
- [17] P.S. Sledzik, M.S. Micozzi, Autopsied, embalmed, and preserved human remains: distinguishing features in forensic and historic context, in: W.D. Haglund, M. H. Sorg (Eds.), *Forensic Taphonomy: The Post-mortem Fate of Human Remains*, CRC Press, 1996, pp. 483–496.
- [18] O. Bulut, C.Y.J. Liu, F. Koca, C.M. Wilkinson, Comparison of three-dimensional facial morphology between upright and supine positions employing three-dimensional scanner from live subjects, *Leg. Med.* 27 (2017) 32–37.
- [19] T. Balueva, E. Veselovskaya, L. Valencia-Caballero, A. Methadzovic, Nuevos estudios en el área de reconstrucción facial a partir de datos craneológicos, *Rev. Esp. De. Antropol. F. iS.* (2009) 11–22.
- [20] Farkas, L.G. (Ed.). 1994. *Anthropometry of the Head and Face*. Lippincott Williams and Wilkins.
- [21] C.K. Deutsch, A.R. Shell, R.W. Francis, B.D. Bird, The Farkas system of craniofacial anthropometry: methodology and normative databases, *Handb. Anthr.: Phys. Meas. Hum. Form. Health Dis.* (2012) 561–573.
- [22] C. Sforza, V.F. Ferrario, Soft-tissue facial anthropometry in three dimensions: from anatomical landmarks to digital morphology in research, clinics and forensic anthropology, *J. Anthr. Sci.* 84 (2006) 97–124.
- [23] Galantucci, L.M., Ferrandes, R., and Percoco, G. 2006. Digital photogrammetry for facial recognition.
- [24] L.G. Farkas, W. Bryson, J. Klotz, Is photogrammetry of the face reliable, *Plast. Reconstr. Surg.* 66 (3) (1980) 346–355.
- [25] J.H. Relethford, Apportionment of global human genetic diversity based on craniometrics and skin color, *Am. J. Phys. Anthropol.: Off. Publ. Am. Assoc. Phys. Anthropol.* 118 (4) (2002) 393–398.
- [26] A.H. Ross, D.H. Ubelaker, and, A.B. Falsetti, Craniometric variation in the Americas, *Hum. Biol.* (2002) 807–818.
- [27] M. Aksu, D. Kaya, I. Kocadereli, Reliability of reference distances used in photogrammetry, *Angle Orthod.* 80 (4) (2010) 670–677.
- [28] T.S. Douglas, Image processing for craniofacial landmark identification and measurement: a review of photogrammetry and cephalometry, *Comput. Med. Imaging Graph.* 28 (7) (2004) 401–409.
- [29] J.Y. Wong, A.K. Oh, E. Ohta, A.T. Hunt, G.F. Rogers, J.B. Mulliken, C.K. Deutsch, Validity and reliability of craniofacial anthropometric measurement of three-dimensional digital photogrammetric images, *Cleft Palate-Craniofacial J.* 45 (3) (2008) 232–239.
- [30] K. Dütpe, M. Becker, B. Schönmeier, Evaluation of facial anthropometry using three-dimensional photogrammetry and direct measuring techniques, *J. Craniofacial Surg.* 29 (5) (2018) 1245–1251.
- [31] O. Ekrami, P. Claes, J.D. White, A.A. Zaidi, M.D. Shriver, S. Van Dongen, Measuring asymmetry from high-density three-dimensional surface scans: an application to human faces, *PLoS One* 13 (12) (2018) e0207895.
- [32] A.C. Da Silveira, J.L. Daw, B. Kusnoto, C. Evans, M. Cohen, Craniofacial applications of three-dimensional laser surface scanning, *J. Craniofacial Surg.* 14 (4) (2003) 449–456.
- [33] K.B. Naudi, R. Benramadan, L. Brocklebank, X. Ju, B. Khambay, A. Ayoub, The virtual human face: superimposing the simultaneously captured three-dimensional photorealistic skin surface of the face on the untextured skin image of the CBCT scan, *Int. J. Oral. Maxillofac. Surg.* 42 (3) (2013) 393–400.
- [34] H.L. Rudy, N. Wake, J. Yee, E.S. Garfein, O.M. Tepper, Three-dimensional facial scanning at the fingertips of patients and surgeons: accuracy and precision testing of iPhone X three-dimensional scanner, *Plast. Reconstr. Surg.* 146 (6) (2020) 1407–1417.
- [35] M.T. Ross, R. Cruz, T.L. Brooks-Richards, L.M. Hafner, S.K. Powell, M. A. Woodruff, Comparison of three-dimensional surface scanning techniques for capturing the external ear, *Virtual Phys. Prototyp.* 13 (4) (2018) 255–265.
- [36] Boehnen, C., and Flynn, P. 2005, June. Accuracy of three-dimensional scanning technologies in a face scanning scenario. In 5th International Conference on 3-D Digital Imaging and Modeling (three-dimensionalIM'05); 310-317. IEEE.
- [37] D. Ettorre, G. Farronato, M. Candida, E. Quinzi, V. C. Grippaudo, A comparison between stereophotogrammetry and smartphone structured light technology for three-dimensional face scanning, *Angle Orthod.* 92 (3) (2022) 358–363.
- [38] Liu, F., Tran, L., and Liu, X. (2019). three-dimensional face modeling from diverse raw scan data. In Proceedings of the IEEE/CVF International Conference on Computer Vision; 9408-9418.
- [39] Albitoosh, A.A.O., and Mossey, P.A. 2016. Prediction of Naso-labial Morphology from Dental Pattern Assessments (Doctoral dissertation, University of Dundee).
- [40] M. Javaid, A. Haleem, L. Kumar, Current status and applications of three-dimensional scanning in dentistry, *Clinical Epidemiol. Glob. Health* 7 (2) (2019) 228–233.
- [41] K. Lopatienė, A. Sidlauskas, A. Vasiliauskas, L. Čecytė, V. Švalkauskienė, and, M. Sidlauskas, Relationship between malocclusion, soft tissue profile, and pharyngeal airways: a cephalometric study, *Medicina* 52 (5) (2016) 307–314.
- [42] L.G. Farkas, B.D. Tompson, M.J. Katic, C.R. Forrest, Differences between direct (anthropometric) and indirect (cephalometric) measurements of the skull, *J. Craniofac. Surg.* 13 (1) (2002) 105–108.
- [43] K.J. Showfety, P.S. Vig, S. Matteson, A simple method for taking natural-head-position cephalograms, *Am. J. Orthod.* 83 (6) (1983) 495–500.
- [44] S. Malkoc, Z. Sari, S. Usumez, A.E. Koyuturk, The effect of head rotation on cephalometric radiographs, *Eur. J. Orthod.* 27 (3) (2005) 315–321.
- [45] R.C. Hoogveen, G.C.H. Sanderink, W.E.R. Berkhout, Effect of head position on cephalometric evaluation of the soft-tissue facial profile, *Dentomaxillofacial Radiol.* 42 (6) (2013) 20120423.
- [46] J. Rino Neto, J.B.D. Paiva, G.V. Queiroz, M.F. Attizzani, H. Miasiro Junior, Evaluation of radiographic magnification in lateral cephalograms obtained with different X-ray devices: experimental study in human dry skull, *Dent. Press J. Orthod.* 18 (2013) 17e1–17e7.
- [47] J.M. Dibbets, K. Nolte, Effect of magnification on lateral cephalometric studies, *Am. J. Orthod. Dentofac. Orthop.* 122 (2) (2002) 196–201.
- [48] Mancuso, A.A., and Hanafee, W.N. 1985. *Computed tomography and magnetic resonance imaging of the head and neck*. Second edition. United States: N. p., Web.
- [49] A. Juerchott, M.A. Saleem, T. Hilgenfeld, C. Freudspurger, S. Zingler, C.J. Lux, M. Bendzus, S. Heiland, Three-dimensional cephalometric analysis using magnetic resonance imaging: validation of accuracy and reproducibility, *Sci. Rep.* 8 (1) (2018), 1-1.
- [50] B.V. Mehta, S. Rajani, G. Sinha, Comparison of image processing techniques (magnetic resonance imaging, computed tomography scan and ultrasound) for three-dimensional modeling and analysis of the human bones, *J. Digit. Imaging* 10 (1997) 203–206.
- [51] L. Munn, and, C.N. Stephan, Changes in face topography from supine-to-upright position—and soft tissue correction values for craniofacial identification, *Forensic Sci. Int.* 289 (2018) 40–50.
- [52] L. Gattinoni, Face the evidence: prone or supine, *Interv. Present. al 44. convegno Crit. Care Congr. tenutosi a Phoenix nel* (2015) 2015.
- [53] U. Ozsoy, R. Sekerci, E. Ogut, Effect of sitting, standing, and supine body positions on facial soft tissue: detailed three-dimensional analysis, *Int. J. Oral. Maxillofac. Surg.* 44 (10) (2015) 1309–1316.
- [54] A.N. Smith, and, G.A. Shah, A survey of routine head CT protocols in Australia, *Br. J. Radiol.* 70 (832) (1997) 372–374.
- [55] M.M. Rehani, and, M. Berry, Radiation doses in computed tomography: the increasing doses of radiation need to be controlled, *BMJ* 320 (7235) (2000) 593–594.
- [56] K.D. Hopper, J.D. Neuman, S.H. King, A.R. Kunselman, Radioprotection to the eye during CT scanning, *Am. J. Neuroradiol.* 22 (6) (2001) 1194–1198.
- [57] A.C. Miracle, S.K. Mukherji, Conebeam CT of the head and neck, part 1: physical principles, *Am. J. Neuroradiol.* 30 (6) (2009) 1088–1095.
- [58] Z. Fourie, J. Damstra, P.O. Gerrits, Y. Ren, Accuracy and reliability of facial soft tissue depth measurements using cone beam computer tomography, *Forensic Sci. Int.* 199 (1-3) (2010) 9–14.
- [59] C. Sforza, M.D. Menezes, V.F. Ferrario, Soft- and hard-tissue facial anthropometry in three dimensions: what's new, *J. Anthr. Sci.* 91 (2013) 159–184.
- [60] C.N. Stephan, R. Preisler, In vivo facial soft tissue thicknesses of adult Australians, *Forensic Sci. Int.* 282 (2018) 220–e1.
- [61] S. De Greef, P. Claes, D. Vandermeulen, W. Mollemans, P. Suetens, G. Willems, Large-scale in-vivo Caucasian facial soft tissue thickness database for craniofacial reconstruction, *Forensic Sci. Int.* 159 (2006) S126–S146.
- [62] S.L. Smith, G.S. Throckmorton, Comparability of radiographic and three-dimensional-ultrasound measurements of facial midline tissue depths, *J. Forensic Sci.* 51 (2) (2006) 244–247.
- [63] S.L. Smith, G.S. Throckmorton, A new technique for three-dimensional ultrasound scanning of facial tissues, *J. Forensic Sci.* 49 (3) (2004) 451–457.
- [64] A. Leipner, Z. Obertová, M. Wermuth, M. Thali, T. Ottiker, T. Sieberth, three-dimensional mug shot—three-dimensional head models from photogrammetry for forensic identification, *Forensic Sci. Int.* 300 (2019) 6–12.
- [65] A. Johnson, G. Jani, R. Carew, and, A. Pandey, Assessment of the accuracy of three-dimensional printed teeth by various three-dimensional printers in forensic odontology, *Forensic Sci. Int.* 328 (2021) 111044.
- [66] H. Eliasova, T. Dostalova, P. Urbanova, A comparison of the precision of three-dimensional images of facial tissues from the forensic point of view, *Forensic Imaging* 28 (2022) 200471.
- [67] K.C. Koban, P. Perko, L. Etzel, Z. Li, T.L. Schenck, R.E. Giunta, Validation of two handheld devices against a non-portable three-dimensional surface scanner and assessment of potential use for intraoperative facial imaging, *J. Plast., Reconstr. Aesthetic Surg.* 73 (1) (2020) 141–148.
- [68] C.A. Grant, M. Johnston, C.J. Adam, and, J.P. Little, Accuracy of three-dimensional surface scanners for clinical torso and spinal deformity assessment, *Med. Eng. Phys.* 63 (2019) 63–71.
- [69] M. Vogt, A. Rips, C. Emmelmann, Comparison of iPad Pro®'s LiDAR and TrueDepth capabilities with an industrial three-dimensional scanning solution, *Technologies* 9 (2) (2021) 25.
- [70] Wyndham, S. 2021. Difour-dimensional launches new four-dimensional facial capture system for even more realistic mocap. Redshark (<https://www.redsharknews.com/difour-dimensional-launches-new-four-dimensional-facial-capture-system-for-even-more-realistic-mocap/>).
- [71] H. Bejaoui, H. Ghazouani, W. Barhoumi, Sparse coding-based representation of LBP difference for three-dimensional/four-dimensional facial expression recognition, *Multimed. Tools Appl.* 78 (2019) 22773–22796, <https://doi.org/10.1007/s11042-019-7632-2>.
- [72] Papaioannou, A., Gecer, B., Cheng, S., Chrysos, G., Deng, J., Fotiadou, E. and Zafeiriou, S. 2022, November. MimicME: A Large Scale Diverse four-dimensional Database for Facial Expression Analysis. In *Computer Vision—ECCV 2022: 17th European Conference*, Tel Aviv, Israel, October 23–27, 2022, Proceedings, Part VIII (pp. 467-484). Cham: Springer Nature Switzerland.

- [73] C.M. Wilkinson, *Forensic Facial Reconstruction*, Cambridge University Press, 2004.
- [74] C.M. Wilkinson, C.M., and Rynn, C. (Eds.). 2012. *Craniofacial identification*. Cambridge University Press.
- [75] C.N. Stephan, E.K. Simpson, Facial soft tissue depths in craniofacial identification (Part I): an analytical review of the published adult data, *J. Forensic Sci.* 53 (6) (2008) 1257–1272.
- [76] T.H. Te Wai Pounamu, C.N. Stephan, Cephalometric landmark standards and recent trends in craniofacial identification (2018-22): avoiding imposters by describing variant landmarks as supplemental, *Forensic Imaging* 31 (2022) 200525.
- [77] C.N. Stephan, Accuracies of facial soft tissue depth means for estimating ground truth skin surfaces in forensic craniofacial identification, *Int. J. Leg. Med.* 129 (2015) 877–888.
- [78] C.N. Stephan, E. Simpson, Facial soft tissue depths in craniofacial identification (Part II): an analytical review of published sub-adult data, *J. Forensic Sci.* 53 (2008) 1273–1279.
- [79] C.N. Stephan, R.M. Norris, M. Henneberg, Does sexual dimorphism in facial soft tissue depths justify sex distinction in craniofacial identification? *J. Forensic Sci.* 50 (3) (2005) 1–6.
- [80] C.N. Stephan, 2018 tallied facial soft tissue thicknesses for adults and sub-adults, *Forensic Sci. Int.* 280 (2017) 113–123.
- [81] C.N. Stephan, E. Sievwright, Facial soft tissue thickness (FSTT) estimation models – and the strength of correlations between craniometric dimensions and FSTTs, *Forensic Sci. Int.* 286 (2018) 128–140.
- [82] T.M. Houlton, N. Jooste, M. Steyn, Testing regression and mean model approaches to facial soft-tissue thickness estimation, *Med. Sci. Law* 61 (3) (2021) 170–179.
- [83] A. Kurkuoglu, C. Pelin, B. Ozener, R. Zagyapan, Z. Sahinoglu, A.C. Yazıcı, Facial soft tissue thickness in individuals with different occlusion patterns in adult Turkish subjects, *Homo* 62 (4) (2011) 288–297.
- [84] H. Utsuno, T. Kageyama, K. Uchida, M. Yoshino, S. Oohigashi, H. Miyazawa, K. Inoue, Pilot study of facial soft tissue thickness differences among three skeletal classes in Japanese females, *Forensic Sci. Int.* 195 (1-3) (2010) 165–e1.
- [85] H. Utsuno, T. Kageyama, K. Uchida, and K. Kibayashi, Facial soft tissue thickness differences among three skeletal classes in Japanese population, *Forensic Sci. Int.* 236 (2014) 175–180.
- [86] S. Hamid, A.H. Abuaffan, Facial soft tissue thickness in a sample of Sudanese adults with different occlusions, *Forensic Sci. Int.* 266 (2016) 209–214.
- [87] M.A. Meundi, C.M. David, Facial soft tissue thickness in South Indian adults with varied occlusions—a cone beam computed tomography study, *J. Indian Acad. Oral. Med. Radiol.* 31 (3) (2019) 194.
- [88] K.R. Brooks, R.I. Kemp, Sensitivity to feature displacement in familiar and unfamiliar faces: beyond the internal/external feature distinction, *Perception* 36 (11) (2007) 1646–1659.
- [89] N.D. Haig, The effect of feature displacement on face recognition, *Perception* 13 (5) (1984) 505–512.
- [90] Z. Lewandowski, The influence of changes in size and proportion of selected facial features (eyes, nose, mouth) on assessment of similarity between female faces, *Coll. Antropol.* 39 (2015), 675-646.
- [91] S. Thitiorul, P. Navic, S. Das, P. Mahakkanukrauh, The important facial components for facial approximation: a review of the literature, *Chiang Mai Dent. J.* 42 (2) (2021). May-August 2021.
- [92] C. Saavedra, P. Smith, J. Peissig, The relative role of eyes, eyebrows, and eye region in face recognition, *J. Vis.* 13 (9) (2013), 410-410.
- [93] Whitmall, S.E. 1921. *The anatomy of the human orbit and accessory organs of vision*. Frowde and Hodder and Stoughton Publishers.
- [94] P. Zednikova Mala, J. Veleminska, Eyeball position in facial approximation: accuracy of methods for predicting globe positioning in lateral view, *J. Forensic Sci.* 63 (1) (2018) 221–226.
- [95] P. Guyomarc'h, B. Dutailly, C. Couture, H. Coqueugniot, Anatomical placement of the human eyeball in the orbit—validation using CT scans of living adults and prediction for facial approximation, *J. Forensic Sci.* 57 (5) (2012) 1271–1275.
- [96] L.G. Farkas, Accuracy of anthropometric measurements: past, present, and future, *Cleft Palate Craniofacial J.* 33 (1) (1996) 10–22.
- [97] K. Hemalatha, N.G. Chander, K.V. Anitha, Correlation between iris diameter and the width of the maxillary central incisor with digital image analysis, *J. Prosthet. Dent.* 119 (3) (2018) 450–454.
- [98] C.E.P. Machado, M.R.P. Flores, L.N.C. Lima, R.L.R. Tinoco, A. Franco, A.C. B. Bezerra, M.A. Guimarães, A new approach for the analysis of facial growth and age estimation: iris ratio, *PLoS One* 12 (7) (2017) e0180330.
- [99] C.M. Wilkinson, S.A. Mautner, Measurement of eyeball protrusion and its application in facial reconstruction, *J. Forensic Sci.* 48 (1) (2003) 12–16.
- [100] A. Ronneburger, J. Basarab, H.C. Howland, Growth of the cornea from infancy to adolescence, *Ophthalmic Physiol. Opt.* 26 (1) (2006) 80–87.
- [101] B.P. Gatliff, Facial sculpture on the skull for identification, *Am. J. Forensic Med. Pathol.* 5 (4) (1984) 327–332.
- [102] K.T. Taylor, *Forensic Art and Illustration*, CRC Press, Boca Raton, FL, 2001.
- [103] C.N. Stephan, P.L. Davidson, The placement of the human eyeball and canthi in craniofacial identification, *J. Forensic Sci.* 53 (3) (2008) 612–619.
- [104] Wolff, E. 1933. *The anatomy of the eye and orbit*. London: H. K. Lewis and Co.
- [105] W.W. Goldnamer, *The Anatomy of the Human Eye and Orbit*, The Professional Press, Chicago, 1923.
- [106] C.N. Stephan, A.J. Huang, P.L. Davidson, Further evidence on the anatomical placement of the human eyeball for facial approximation and craniofacial superimposition, *J. Forensic Sci.* 54 (2) (2009) 267–269.
- [107] Dorfling, H.F. 2017. *Aspects of facial features in a South African sample as applicable for facial approximations*. Doctoral dissertation, University of Pretoria.
- [108] H.F. Dorfling, Z. Lockhat, S. Pretorius, M. Steyn, A.C. Oettlé, Facial approximations: characteristics of the eye in a South African sample, *Forensic Sci. Int.* 286 (2018) 46–53.
- [109] K.M. Lee, W.J. Lee, J.H. Cho, and, H.S. Hwang, Three-dimensional prediction of the nose for facial reconstruction using cone-beam computed tomography, *Forensic Sci. Int.* 236 (2014) 194–e1.
- [110] C.N. Stephan, Facial approximation: globe projection guideline falsified by exophthalmometry literature, *J. Forensic Sci.* 47 (4) (2002) 730–735.
- [111] T. Rosenstein, N. Talebzadeh, M.A. Pogrel, Anatomy of the lateral canthal tendon, *Oral. Surg., Oral. Med., Oral. Pathol., Oral. Radiol. Endodontol.* 89 (1) (2000) 24–28.
- [112] Drake, R.L., Gray, H., Vogl, W., and Mitchell, A.W. 2005. *Gray's anatomy for students*. Elsevier Health Sciences TW.
- [113] K. Hwang, Y.S. Nam, D.J. Kim, S.H. Han, S.H. Hwang, Anatomic study of the lateral palpebral raphe and lateral palpebral ligament, *Ann. Plast. Surg.* 62 (3) (2009) 232–236.
- [114] W.M. Krogman, M.Y. Iscan, *The Human Skeleton in Forensic Medicine*. Springfield, Charles C. Thomas, IL, 1993, p. 1986.
- [115] S.E. Whitnall, On a Tubercle on the Malar Bone, and on the Lateral Attachments of the Tarsal Plates, *J. Anat. Physiol. Jul.* 45 (Pt 4) (1911) 429.
- [116] J.D. Sills, Computer photographic skull reconstruction (methods used in facial restoration), in: L.G. Farkas (Ed.), *Anthropometry of the Head and Face*, Raven Press, New York, 1994.
- [117] G.E. Anastassov, P.A. van Damme, Evaluation of the anatomical position of the lateral canthal ligament: clinical implications and guidelines, *J. Craniofac Surg.* 7 (1996) 429–436.
- [118] Angel, J.L. 1978. *Restoration of head and face for identification*. The 30th Annual Meeting of the American Academy of Forensic Sciences; Feb 20–25; St. Louis, MO.
- [119] R.M. George, Anatomical and artistic guidelines for forensic facial reconstruction, in: M.Y. Iscan, R.P. Helmer (Eds.), *Forensic Analysis of the Skull*, Wiley-Liss, New York, 1993, pp. 215–227.
- [120] B.A. Fedosyutkin, J.V. Nainys, The relationship of skull morphology to facial features, in: M.Y. Iscan, R.P. Helmer (Eds.), *Forensic Analysis of the Skull*, Wiley-Liss, New York, 1993, pp. 199–213.
- [121] T.D. Stewart, The points of attachment of the palpebral ligaments: their use in facial reconstructions on the skull, *J. Forensic Sci.* 28 (1983) 858–863.
- [122] C. Rynn, T.B. Balueva, E.R. Veselovskaya, Relationships between the skull and face. *Cpt* 16, in: C.M. Wilkinson, C. Rynn (Eds.), *Craniofacial Identification*, Cambridge University Press, 2012, pp. 193–202.
- [123] K.B. Altes, Feature proportion accuracy of hand-drawn facial approximation, *Sci. Justice* 56 (6) (2016) 443–452.
- [124] A. Gulses, A. Varol, O. Gayretli, N. Kocabiyik, M. Sencimen, Anthropometry of the medial canthal ligament related to naso-orbitoethmoidal fractures, *J. Craniofacial Surg.* 23 (4) (2012) 1151–1153.
- [125] E. Poh, H. Kakizaki, D. Selva, I. Leibovitch, Anatomy of medial canthal tendon in Caucasians, *Clin. Exp. Ophthalmol.* 40 (2) (2012) 170–173.
- [126] T.J. Robinson, and, M.F. Stranc, The anatomy of the medial canthal ligament, *Br. J. Plast. Surg.* 23 (1970) 1–7.
- [127] S.C. Rhee, K.S. Woo, and, B. Kwon, Biometric study of eyelid shape and dimensions of different races with references to beauty, *Aesthetic Plast. Surg.* 36 (2012) 1236–1245.
- [128] S.N. Talamas, K.I. Mavor, J. Axelsson, T. Sundelin, D.I. Perrett, Eyelid-openness and mouth curvature influence perceived intelligence beyond attractiveness, *J. Exp. Psychol.: Gen.* 145 (5) (2016) 603.
- [129] X. Liu, S. Shan, and, X. Chen *Face recognition after plastic surgery: a comprehensive study* Springer Berlin Heidelberg, 11 In *Computer Vision-ACCV 2012: 11th Asian Conference on Computer Vision*, Daejeon, Korea, November 5-9, 2012, Revised Selected Papers, Part II 2013, In *Computer Vision-ACCV 2012: th Asian Conference on Computer Vision*, Daejeon, Korea, November 5-9, 2012, Revised Selected Papers, Part III 1, 565–576.
- [130] M. Nappi, S. Ricciardi, M. Tistarelli, Deceiving faces: when plastic surgery challenges face recognition, *Image Vis. Comput.* 54 (2016) 71–82.
- [131] Gerasimov, M.M. 1955. *The Reconstruction of the Face from the Basic Structure of the Skull*, translator W. Tshernetzky, 1975 Russia: Publishers unknown.
- [132] T.B. Balueva, E.V. Veselovskaya, E. Kobylansky, Craniofacial reconstruction by applying the ultrasound method in live human populations, *Int J. Anthropol.* 24 (2) (2009) 87–111.
- [133] J. Sadr, I. Jarudi, P. Sinha, The role of eyebrows in face recognition, *Perception* 32 (3) (2003) 285–293.
- [134] J. Peissig, T. Goode, P. Smith, The role of eyebrows in face recognition: with, without, and different, *J. Vis.* 9 (8) (2009), 554-554.
- [135] N. Abudarham, L. Shkiller, G. Yovel, Critical features for face recognition, *Cognition* 182 (2019) 73–83.
- [136] P. Sinha, B. Balas, Y. Ostrovsky, R. Russell, Face recognition by humans: nineteen results all computer vision researchers should know about, *Proc. IEEE* 94 (11) (2006) 1948–1962.
- [137] Kim, Y.S., Lee, W.J., Yun, J.S., Kim, D.H., Lozanoff, S., and Lee, U.Y. 2022. *Predicting the Eyebrow from the Orbit Using Three-dimensional CT Imaging: An Application in Forensic Facial Reconstruction and Identification*.
- [138] C.N. Stephan, Position of superciliare in relation to the lateral iris: testing a suggested facial approximation guideline, *Forensic Sci. Int.* 130 (1) (2002) 29–33.
- [139] C.A. Amodeo, The central role of the nose in the face and the psyche: review of the nose and the psyche, *Aesthetic Plast. Surg.* 31 (2007) 406–410.

- [140] N. Erdogmus, N. Kose, and J.L. Dugelay, Impact analysis of nose alterations on 2d and three-dimensional face recognition. In 2012 IEEE 14th Int. Workshop Multimed. Signal Process. (MMSP), 2012, September, 354–359.
- [141] S. Davy-Jow, The devil is in the details: a synthesis of psychology of facial perception and its applications in forensic facial reconstruction, *Sci. Justice* 53 (2) (2013) 230–235.
- [142] G. Chu, J.M. Zhao, M.Q. Han, Q.N. Mou, L.L. Ji, H. Zhou, T. Chen, S.Y. Du, Y. C. Guo, Three-dimensional prediction of nose morphology in Chinese young adults: a pilot study combining cone-beam computed tomography and three-dimensional MD photogrammetry system, *Int. J. Leg. Med.* 134 (2020) 1803–1816.
- [143] J.Y. Ryu, K.S. Park, M.J. Kim, J.S. Yun, U.Y. Lee, S.S. Lee, B.Y. Roh, J.U. Seo, C. U. Choi, W.J. Lee, Craniofacial anthropometric investigation of relationships between the nose and nasal aperture using three-dimensional computed tomography of Korean subjects, *Sci. Rep.* 10 (1) (2020) 16077.
- [144] A.F. Ridel, F. Demeter, J. Liebenberg, E.N. L'Abbé, D. Vandermeulen, A.C. Oettlé, Skeletal dimensions as predictors for the shape of the nose in a South African sample: a cone-beam computed tomography (CBCT) study, *Forensic Sci. Int.* 289 (2018) 18–26.
- [145] K.J. Anderson, M. Henneberg, R.M. Norris, Anatomy of the nasal profile, *J. Anat.* 213 (2) (2008) 210–216.
- [146] C. Rynn, C.M. Wilkinson, Appraisal of traditional and recently proposed relationships between the hard and soft dimensions of the nose in profile, *Am. J. Phys. Anthropol. Off. Publ. Am. Assoc. Phys. Anthropol.* 130 (3) (2006) 364–373.
- [147] O. Bulut, C.Y.J. Liu, S. Gurcan, B. Hekimoglu, Prediction of nasal morphology in facial reconstruction: validation and recalibration of the Rynn method, *Leg. Med.* 40 (2019) 26–31.
- [148] C. Rynn, C.M. Wilkinson, H.L. Peters, Prediction of nasal morphology from the skull, *Forensic Sci., Med., Pathol.* 6 (2010) 20–34.
- [149] L.G. Maltais, N. Lynnerup, R.D. Hoppa, Validation of the new interpretation of Gerasimov's nasal projection method for forensic facial approximation using CT data, *J. Forensic Sci.* 61 (2016) S193–S200.
- [150] C.N. Stephan, M. Henneberg, W. Sampson, Predicting nose projection and pronasale position in facial approximation: a test of published methods and proposal of new guidelines, *Am. J. Phys. Anthropol.: Off. Publ. Am. Assoc. Phys. Anthropol.* 122 (3) (2003) 240–250.
- [151] B. López, J. Schilling, I.S. Galdames, Evaluación de los métodos de localización del punto pronasale para la reconstrucción facial forense, *Int. J. Morphol.* 28 (4) (2010) 1181–1188.
- [152] Simon, E.L.B. 2015. Testing Gerasimov's two-tangent nose projection method in craniofacial approximations of children. MA thesis, Simon Fraser University.
- [153] P. Prokopec, D.H. Ubelaker, Reconstructing the shape of the nose according to the skull, *Forensic Sci. Commun.* 4 (2002) 1.
- [154] H. Ullrich, C.N. Stephan, On Gerasimov's plastic facial reconstruction technique: new insights to facilitate repeatability, *J. Forensic Sci.* 56 (2) (2011) 470–474.
- [155] P.Z. Mala, Pronasale position: an appraisal of two recently proposed methods for predicting nasal projection in facial reconstruction, *J. Forensic Sci.* 58 (4) (2013) 957–963.
- [156] E. Sarilita, C. Rynn, P.A. Mossey, S. Black, F. Oscandar, Nose profile morphology and accuracy study of nose profile estimation method in Scottish subadult and Indonesian adult populations, *Int. J. Leg. Med.* 132 (2018) 923–931.
- [157] Krogman, W.M. and Iscan, M.Y. 1986. *The human skeleton in forensic medicine*. 2nd ed. Springfield, IL: C.C. Thomas Publishers.
- [158] R.M. George, The lateral craniographic method of facial reconstruction, *J. Forensic Sci.* 32 (1987) 1305–1330.
- [159] G.A. Macho, An appraisal of plastic reconstruction of the external nose, *J. Forensic Sci.* 31 (1986) 1391–1403.
- [160] S.V. Tedeschi-Oliveira, T.L. Beaini, R.F.H. Melani, Forensic facial reconstruction: nasal projection in Brazilian adults, *Forensic Sci. Int.* 266 (2016) 123–129.
- [161] R.A.P. Strapasson, C. Costa, R.F.H. Melani, Forensic facial approximation: study of the nose in Brazilian subjects, *J. Forensic Sci.* 64 (6) (2019) 1640–1645.
- [162] R.A.P. Strapasson, and R.F.H. Melani, Facial reconstruction: validation of the Tedeschi-Oliveira method for estimating the pronasale point in Brazilians, *Braz. Oral. Res.* 34 (2020).
- [163] H. Utsuno, T. Kageyama, K. Uchida, K. Kibayashi, K. Sakurada, K. Uemura, Pilot study to establish a nasal tip prediction method from unknown human skeletal remains for facial reconstruction and skull photo superimposition as applied to a Japanese male population, *J. Forensic Leg. Med.* 38 (2016) 75–80. ISO 690.
- [164] S. Thitirol, P. Mahakkanukrauh, S. Prasitwattanaseree, K. Sitthiseripratip, A. Iamaroon, S. Na Lampang, S. Prapayatsok, Three-dimensional prediction of the nose for facial approximation in a Thai population, *J. Forensic Sci.* 65 (3) (2020) 707–714.
- [165] M.M. Diac, K. Earar, S.I. Damian, A. Knieling, T. Iov, S. Shrimpton, M. Castaneya-Ruiz, C.M. Wilkinson, I.D. Bulgaru, Facial reconstruction: anthropometric studies regarding the morphology of the nose for Romanian adult population I: nose width, *Appl. Sci.* 10 (18) (2020) 6479, <https://doi.org/10.3390/app10186479>.
- [166] Rynn, C. 2006. Craniofacial approximation and reconstruction: tissue depth patterning and the prediction of the nose. PhD thesis. University of Dundee, UK.
- [167] S. Thitirol, S. Prapayatsok, S. Na Lampang, S. Prasitwattanaseree, K. Sitthiseripratip, A. Iamaroon, P. Mahakkanukrauh, Nose width and mouth width predictions in a Thai population using cone-beam computed tomography data, *Aust. J. Forensic Sci.* 53 (4) (2021) 390–399.
- [168] V.L. Gomes, L.C. Gonçalves, M.M. Costa, B. de Lima Lucas, Interlar distance to estimate the combined width of the six maxillary anterior teeth in oral rehabilitation treatment, *J. Esthet. Restor. Dent.* 21 (1) (2009) 26–35.
- [169] W. Hoffman Jr, T.J. Bomberg, R.A. Hatch, Interlar width as a guide in denture tooth selection, *J. Prosthet. Dent.* 55 (2) (1986) 219–221.
- [170] H.M. Al-el-Sheikh, M.S. Al-Athel, The relationship of interlar width, interpylary width and maxillary anterior teeth width in Saudi population, *Trop. Dent. J.* (1998) 7–10.
- [171] S.C. Deogade, S.S. Mantri, K. Sumathi, S. Rajoriya, The relationship between intercanthal dimension and interalar width to the intercanine width of maxillary anterior teeth in central Indian population, *J. Indian Prosthodont. Soc.* 15 (2) (2015) 91.
- [172] A.S. Dharap, H. Tanuseputro, A comparison of interlar width and intercanine distance in Malay males and females, *Anthropol. Anz.* (1997) 63–68.
- [173] G.A. Miranda, M. D'Souza, Evaluating the reliability of the interlar width and intercommissural width as guides in selection of artificial maxillary anterior teeth: a clinical study, *J. Interdiscip. Dent.* 6 (2) (2016) 64.
- [174] J.R. Patel, R. Sethuraman, M.H. Shah, A comparative evaluation of the relationship of inner-canthal distance and inter-alar width to the inter-canine width amongst the Gujarati population, *J. Adv. Oral. Res.* 2 (3) (2011) 31–38.
- [175] R.A.P. Strapasson, L.M. Herrera, R.F.H. Melani, Forensic facial reconstruction: relationship between the alar cartilage and piriform aperture, *J. Forensic Sci.* 62 (6) (2017) 1460–1465.
- [176] S.L. Davy-Jow, S.J. Decker, J.M. Ford, A simple method of nose tip shape validation for facial approximation, *Forensic Sci. Int.* 214 (1–3) (2012) 208–e1.
- [177] I.D. Burton, C. Rynn, N. Thiemann-Freudenstein, A revised nose tip shape validation method for facial reconstruction based on CT data from a modern German population, *Leg. Med.* 49 (2021) 101833.
- [178] L.R. Rubin, Y. Mishriki, G. Lee, Anatomy of the nasolabial fold: the keystone of the smiling mechanism, *Plast. Reconstr. Surg.* 83 (1) (1989) 1–10.
- [179] J.E. Pessa, V.P. Zadoc, E.K. Jr Adrian, C. Yuan, Variability of the midfacial muscles: analysis of 50 hemifacial cadaver dissections, *J. Am. Soc. Plast. Surg.* 102 (6) (1998) 1888–1893.
- [180] J. Zufferey, Anatomic variations of the nasolabial fold, *Plast. Reconstr. Surg.* 89 (2) (1992) 225–231, discussion 232–223.
- [181] H. Hadi, C.M. Wilkinson, Estimation and reconstruction of facial creases based on skull crease morphology, *Aust. J. Forensic Sci.* 50 (1) (2016) 42–56.
- [182] R. Cabeza, T. Kato, Features are also important: contributions of featural and configural processing to face recognition, *Psychol. Sci.* 11 (5) (2000) 429–433.
- [183] R.A. Johnston, A.J. Edmonds, Familiar and unfamiliar face recognition: a review, *Memory* 17 (5) (2009) 577–596.
- [184] M. Tistarelli, M. Bicego, E. Grosso, Dynamic face recognition: from human to machine vision, *Image Vis. Comput.* 27 (3) (2009) 222–232.
- [185] J.W. Tanaka, J.A. Sengco, Features and their configuration in face recognition, *Mem. Cogn.* 25 (5) (1997) 583–592.
- [186] J.P. Finnøy, P.J. Wisth, O.E. Bøe, Changes in soft tissue profile during and after orthodontic treatment, *Eur. J. Orthod.* 9 (1) (1987) 68–78.
- [187] Z.Y. Liu, J. Yu, F.F. Dai, R.P. Jiang, T.M. Xu, Three-dimensional changes in lip vermilion morphology of adult female patients after extraction and non-extraction orthodontic treatment, *Korean J. Orthod.* 49 (4) (2019) 222–234.
- [188] Y. Stromboni, Facial aesthetics in orthodontic treatment with and without extractions, *Eur. J. Orthod.* 1 (3) (1979) 201–206.
- [189] R.M. Alkadhhi, M.D. Finkelman, C.A. Trotman, G. Kanavakis, The role of lip thickness in upper lip response to sagittal change of incisor position, *Orthod. Craniofacial Res.* 22 (1) (2019) 53–57.
- [190] T.M. Houlton, N. Jooste, M. Steyn, J. Hemingway, Visualising trends in dentition to lip mouth morphology using geometric morphometrics, *Plos One* 17 (9) (2022) e0274127.
- [191] C. Tanikawa, K. Nakamura, M. Yagi, K. Takada, Lip vermilion profile patterns and corresponding dentoskeletal forms in female adults, *Angle Orthod.* 79 (5) (2009) 849–858.
- [192] R. Islam, T. Kitahara, L. Naher, A. Hara, S. Nakata, Lip morphology changes following orthognathic surgery for class III malocclusion, *Angle Orthod.* 80 (2) (2010) 344–353.
- [193] R. Islam, T. Kitahara, L. Naher, A. Hara, A. Nakasima, Lip morphological changes in orthodontic treatment: class II division 1 malocclusion and normal occlusion at rest and on smiling, *Angle Orthod.* 79 (2) (2009) 256–264.
- [194] A. Chaudhary, J. Giri, R. Gyawali, and P.R. Pokharel, A retrospective study comparing nose, lip, and chin morphology in class I, class II, and class III skeletal relationships in patients visiting to the department of orthodontics, BPKIHS: a cephalometric study, *Int. J. Dent.* 2022 (2022).
- [195] K. Kasai, Soft tissue adaptability to hard tissues in facial profiles, *Am. J. Orthod. Dentofac. Orthop.* 113 (6) (1998) 674–684.
- [196] W.-C. Song, S.-H. Kim, D.-J. Paik, S.-H. Han, K.-S. Hu, H.-J. Kim, K.-S. Koh, Location of the infraorbital and mental foramen with reference to the soft-tissue landmarks, *Plast. Reconstr. Surg.* 120 (2007) 1343–1347.
- [197] C.N. Stephan, S.J. Murphy, Mouth width prediction in craniofacial identification: cadaver tests of four recent methods, including two techniques for edentulous skulls, *J. Forensic Odontostomatol.* 27 (1) (2008) 2–7.
- [198] C. Stephan, M. Henneberg, Predicting mouth width from inter-canine width—a 75% rule, *J. Forensic Sci.* 48 (4) (2003) 725–727.
- [199] A. Dharap, A.H. Salem, R. Fadel, M. Osman, M. Chakravarty, N. Abdul Latif, M. Abu-Hijleh, Facial anthropometry in an Arab population, *Bahrain Med. Bull.* 158 (695) (2013) 1–5.
- [200] T.M.R. Houlton, N. Jooste, and M. Steyn, Mouth width and Cupid's bow estimation in a southern African population, *J. Forensic Sci.* 65 (2) (2020) 372–379.
- [201] P.E. Dias, G.E. Miranda, T.L. Beaini, R.F. Melani, Practical application of anatomy of the oral cavity in forensic facial reconstruction, *PLoS One* 11 (2016) e0162732.

- [202] M.M.M. Hamid, A.I. Faragalla, W.S.A. Ibrahim, A.B.G. Eldin, Facial Anthropometry among Saudi Population, *Ann. Med. Health Sci. Res.* 11 (2021) 4.
- [203] J.M. Zhao, L.L. Ji, M.Q. Han, Q.N. Mou, G. Chu, T. Chen, S.Y. Du, Y.X. Hou, Y. C. Guo, Lip morphology estimation models based on three-dimensional images in a modern adult population from China, *Int. J. Leg. Med.* 135 (2021) 1887–1901 (Sep).
- [204] U.L. Uche, A.O. Oluseun, M.I. Nwachuku, L.B. Babatunde, J.O. Ikpa, Anthropometric study of interalar width and mouth width measurements among Nigerians of Delta State extraction, *Eur. J. Biomed.* 7 (8) (2020) 17–20.
- [205] Chavan, A.P., Yeshwante, B.J., and Mahale, K.M. A clinical study to evaluate the intercommissural width, the interalar width and the inner intercanthal distance as guides for the selection of maxillary anterior teeth width in complete denture. *Journal of Prosthodontics Dentistry* 17 (1) ISSN No:2582-0362.
- [206] C.M. Wilkinson, M. Motwani, E. Chiang, The relationship between the soft tissues and the skeletal detail of the mouth, *J. Forensic Sci.* 48 (4) (2003) 728–732.
- [207] T.M. Houlton, N. Jooste, A. Uys, M. Steyn, Lip height estimation in a southern African sample, *South African Dental Journal* 75 (8) (2020) 415–424.
- [208] P. Zednikova Mala, J. Velemínska, Vertical lip position and thickness in facial reconstruction: a validation of commonly used methods for predicting the position and size of lips, *J. Forensic Sci.* 61 (4) (2016) 1046–1054.
- [209] Lebedinskaya, G.B. 1998. Rekonstrukcia lica po cerepu (metodiceskoje rukovodstvo). Moskva, Russia: Staryj Sad.
- [210] G.T. McIntyre, D.T. Millett, Lip shape and position in class II division 2 malocclusion, *Angle Orthod.* 76 (5) (2006) 739–744.
- [211] E.J. Schmidlin, M. Steyn, T.M. Houlton, and, N. Briers, Facial ageing in South African adult males, *Forensic Sci. Int.* 289 (2018) 277–286.
- [212] M. De Menezes, R. Rosati, I. Baga, A. Mapelli, C. Sforza, Three-dimensional analysis of labial morphology: effect of sex and age, *Int. J. Oral. Maxillofac. Surg.* 40 (8) (2011) 856–861.
- [213] S. Samizadeh, Facial ageing in East Asians, *Non-Surg. Rejuvenation Asian Faces* (2022) 97–106.
- [214] S. Desai, M. Upadhyay, R. Nanda, Dynamic smile analysis: changes with age, *Am. J. Orthod. Dentofac. Orthop.* 136 (3) (2009) 310–e1.
- [215] A.M. Al-Drees, Oral and perioral physiological changes with ageing, *Pak. Oral. Dent. J.* 30 (2010) 1.
- [216] R.P. Baldasso, N.P. Damascena, A.R. Deitos, C.E.P. Machado, A. Franco, R.N. de Oliveira, Morphologic alterations ear, nose and lip detected with aging through facial photoanthropometric analysis, *J. Forensic Odonto-Stomatol.* 37 (2) (2019) 25.
- [217] H.S. Kim, T.H. Jin, J.K. Dong, A study on the relation between lip and teeth at smile in old aged Korean, *J. Korean Acad. Prosthodont.* 31 (4) (1993) 533–541.
- [218] M. Ushijima, Y. Kamashita, Y. Nishi, and, E. Nagaoka, Changes in lip forms on three-dimensional images with alteration of lip support and/or occlusal vertical dimension in complete denture wearers, *J. Prosthodont. Res.* 57 (2) (2013) 113–121.
- [219] Welcker, H. 1883. Schiller's schadel und todenmaske, nebst mittheilungen uber schadel und todenmaske kant's. Braunschweig: Viehweg F and Son.
- [220] M.F. Ashley-Montagu, Location of porion in the living, *Am. J. Phys. Anthr.* 25 (2) (1939) 281–295.
- [221] J.W. Choi, S.Y. Jung, H.J. Kim, S.H. Lee, Positional symmetry of porion and external auditory meatus in facial asymmetry, *Maxillofac. Plast. Reconstr. Surg.* 37 (2015) 1–9.
- [222] H. Pancherz, K. Gökbuget, The reliability of the Frankfort Horizontal in roentgenographic cephalometry, *Eur. J. Orthod.* Volume 18 (Issue 4) (1996) 367–372 (August).
- [223] V.F. Ferrario, C. Sforza, A. Anderbegani, C.E. Poggio, L.L. Dalloca, Relative position of porion and tragus in orthodontic patients, *Clin. Anat.: Off. J. Am. Assoc. Clin. Anat. Br. Assoc. Clin. Anat.* 8 (5) (1995) 352–358.
- [224] Jordanov, J. 2003. Head reconstruction by the skull. Sofia, Bulgaria: Marin Drinov Academic Publishing House.
- [225] L.G. Farkas, T.M. Hreczko, M. Katic, Craniofacial norms in North American Caucasians from birth (one year) to young adulthood, in: L.G. Farkas (Ed.), *Anthropometry of the Head and Face*, Raven Press, New York, NY, 1994, pp. 241–336.
- [226] L.G. Farkas, T.A. Hreczko, J.C. Kolar, I.R. Munro, Vertical and horizontal proportions of the face in young adult North American Caucasians: revision of neoclassical canons, *Plast. Reconstr. Surg.* 75 (3) (1985) 328–337.
- [227] P. Guyomarc'h, C.N. Stephan, The validity of ear prediction guidelines used in facial approximation, *J. Forensic Sci.* 57 (6) (2012) 1427–1441.
- [228] V.F. Ferrario, C. Sforza, V. Ciusa, G. Serrao, G. Tartaglia, Morphometry of the normal human ear: a cross-sectional study from adolescence to mid-adulthood, *J. Craniofac Genet Dev. Biol.* 19 (4) (1999) 226–233.
- [229] C. Sforza, G. Grandi, M. Binelli, D.G. Tommasi, R. Rosati, V.F. Ferrario, Age- and sex-related changes in the normal human ear, *Forensic Sci. Int.* 187 (1–3) (2009), 110.e1–7.
- [230] R. Purkait, P. Singh, Anthropometry of the normal human auricle: a study of adult Indian men, *Aesthetic Plast. Surg.* 31 (4) (2007) 372–379.
- [231] N. Renwick, Ear lobe morphology and its relationship to the mastoid process, *Cent. Anat. Hum. Identif., Univ. Dundee, Dundee AXIS: Online J. CAHID* 12 (2012).
- [232] T.R. Broadbent, V.L. Mathews, Artistic relationships in surface anatomy of the face: application to reconstructive surgery, *Plast. Reconstr. Surg.* 20 (1) (1957) 1–17.
- [233] L.G. Farkas, Discussion—the aesthetics of ear placement: an experimental study, *Plast. Reconstr. Surg.* 72 (2) (1983) 139–140.
- [234] M.S. Skiles, P. Randall, The aesthetics of ear placement: an experimental study, *Plast. Reconstr. Surg.* 72 (2) (1983) 133–140.
- [235] H. Tolleth, Artistic anatomy, dimensions, and proportions of the external ear, *Clin. Plast. Surg.* 5 (3) (1978) 337–345.
- [236] P. Singh, R. Purkait, Observations of external ear—an Indian study. *Homo* 60 (5) (2009) 461–472.
- [237] M.M. Madzharov, Anthropometric research of the lateral surface and the edge of the ears in grown-up Bulgarians, *Acta Chir. Plast.* 31 (2) (1989) 74–83.