



LJMU Research Online

Balreira, A, Boczonadi, V, Barca, E, Pyle, A, Bansagi, B, Appleton, M, Graham, C, Hargreaves, IP, Rasic, VM, Lochmueller, H, Griffin, H, Taylor, RW, Naini, A, Chinnery, PF, Hirano, M, Quinzii, CM and Horvath, R

ANO10 mutations cause ataxia and coenzyme Q(10) deficiency

<http://researchonline.ljmu.ac.uk/id/eprint/13685/>

Article

Citation (please note it is advisable to refer to the publisher's version if you intend to cite from this work)

Balreira, A, Boczonadi, V, Barca, E, Pyle, A, Bansagi, B, Appleton, M, Graham, C, Hargreaves, IP, Rasic, VM, Lochmueller, H, Griffin, H, Taylor, RW, Naini, A, Chinnery, PF, Hirano, M, Quinzii, CM and Horvath, R (2014) ANO10 mutations cause ataxia and coenzvme Q(10) deficiencv. Journal of

LJMU has developed [LJMU Research Online](#) for users to access the research output of the University more effectively. Copyright © and Moral Rights for the papers on this site are retained by the individual authors and/or other copyright owners. Users may download and/or print one copy of any article(s) in LJMU Research Online to facilitate their private study or for non-commercial research. You may not engage in further distribution of the material or use it for any profit-making activities or any commercial gain.

The version presented here may differ from the published version or from the version of the record. Please see the repository URL above for details on accessing the published version and note that access may require a subscription.

For more information please contact researchonline@ljmu.ac.uk

<http://researchonline.ljmu.ac.uk/>

ANO10 mutations cause ataxia and coenzyme Q₁₀ deficiency

Andrea Balreira · Veronika Boczonadi · Emanuele Barca · Angela Pyle · Boglarka Bansagi · Marie Appleton · Claire Graham · Iain P. Hargreaves · Vedrana Milic Rasic · Hanns Lochmüller · Helen Griffin · Robert W. Taylor · Ali Naini · Patrick F. Chinnery · Michio Hirano · Catarina M. Quinzii · Rita Horvath

Received: 11 June 2014/Revised: 14 August 2014/Accepted: 19 August 2014/Published online: 3 September 2014
© The Author(s) 2014. This article is published with open access at Springerlink.com

Abstract Inherited ataxias are heterogeneous disorders affecting both children and adults, with over 40 different causative genes, making molecular genetic diagnosis challenging. Although recent advances in next-generation sequencing have significantly improved mutation detection, few treatments exist for patients with inherited ataxia. In two patients with adult-onset cerebellar ataxia and coenzyme Q₁₀ (CoQ₁₀) deficiency in muscle, whole exome sequencing revealed mutations in *ANO10*, which encodes anoctamin 10, a member of a family of putative calcium-activated chloride channels, and the causative gene for autosomal recessive spinocerebellar ataxia-10 (SCAR10). Both patients presented with slowly progressive ataxia and dysarthria leading to severe disability in the sixth decade. Epilepsy and learning difficulties were also present in one patient, while retinal degeneration and cataract were

present in the other. The detection of mutations in *ANO10* in our patients indicate that *ANO10* defects cause secondary low CoQ₁₀ and SCAR10 patients may benefit from CoQ₁₀ supplementation.

Keywords Autosomal recessive ataxia · Mitochondrial · Coenzyme Q₁₀ (CoQ₁₀) deficiency · *ANO10*

Introduction

Despite major advances in understanding the genetic forms of ataxia, approximately half of the patients with recessive ataxia—in particular, adults—do not receive a molecular diagnosis [1]. Given the numerous etiologies, genetic diagnosis requires the performance of a wide range of analyses and consensus on the diagnostic value of these examinations is lacking. Recent advances in next-generation sequencing have significantly improved the mutation detection rate of inherited ataxias, but treatments for inherited ataxia remain inadequate. Clinical characterization and evaluation for

A. Balreira and V. Boczonadi joint as first authors.
C. M. Quinzii and R. Horvath contributed equally to this study.

Electronic supplementary material The online version of this article (doi:10.1007/s00415-014-7476-7) contains supplementary material, which is available to authorized users.

A. Balreira · E. Barca · M. Hirano · C. M. Quinzii (✉)
Department of Neurology, Columbia University Medical Center,
New York, NY, USA
e-mail: cmq2101@cumc.columbia.edu

V. Boczonadi · A. Pyle · B. Bansagi · C. Graham ·
H. Lochmüller · H. Griffin · P. F. Chinnery · R. Horvath (✉)
Institute of Genetic Medicine, Newcastle University,
Newcastle upon Tyne, UK
e-mail: rita.horvath@ncl.ac.uk

M. Appleton · R. W. Taylor · P. F. Chinnery
Wellcome Trust Centre for Mitochondrial Research, Institute of
Neuroscience, Newcastle University, Newcastle upon Tyne, UK

I. P. Hargreaves
Department of Molecular Neuroscience, UCL Institute of
Neurology, London, UK

V. M. Rasic
Clinic for Neurology and Psychiatry for Children and Youth,
Faculty of Medicine, University of Belgrade, Belgrade, Serbia

A. Naini
Department of Pathology and Cell Biology, Columbia University
Medical Center, New York, NY, USA

subtle additional features can provide clues to the precise diagnosis [2].

Coenzyme Q₁₀ (CoQ₁₀) deficiencies comprise a heterogeneous group of autosomal recessive conditions with primary deficiencies caused by mutations in genes encoding CoQ₁₀ biosynthesis enzymes and secondary forms caused by genetic defects not directly related to CoQ₁₀ biosynthesis [3]. Ataxia is the most common clinical phenotype associated with CoQ₁₀ deficiency [3]. The first causative mutations identified in the ataxic form of CoQ₁₀ deficiency were detected in *APTX*, which encodes aprataxin and is the causative gene for ataxia with oculomotor apraxia 1 (AOA1) [4]. Reduced CoQ₁₀ levels were reported in some but not all AOA1 patients with confirmed pathogenic *APTX* mutations [4]. Autosomal recessive mutations in *ADCK3*, which encodes a kinase involved in CoQ₁₀ biosynthesis, have been identified in several families with juvenile- or adult-onset ataxia, confirming the link between ataxia and CoQ₁₀ deficiencies [3, 5]. Some patients improved on CoQ₁₀ supplementation [3, 5]; the lack of improvement in some patients has been attributed to the reduced bioavailability of CoQ₁₀ and its limited ability to cross the blood brain barrier; however, worsening has been reported for one patient treated with Idebenone, a short-chain CoQ analog [6].

In our genetic characterization of a group of patients with unexplained recessive or sporadic cerebellar ataxia and low muscle CoQ₁₀, we identified pathogenic mutations in *ANO10* in two families.

Case series

This study had institutional and ethical review board approval and all the patients gave informed consent.

Patients and methods

We studied 40 unrelated patients with unexplained ataxia and low CoQ₁₀ in skeletal muscle biopsies without a dominant family history, in whom well-known genetic causes of spinocerebellar ataxias (SCA1,2,3,6,7,17, DRPLA and Friedreich ataxia) and other possible causes of a progressive ataxia were excluded by clinical and laboratory investigations (brain MRI, CSF analyses, normal routine biochemistry, blood cell counts, metabolic screening for acyl-carnitine profiles, urine organic acids, very long chain fatty acids, phytanic acid, vitamins E, A, B12, alpha-fetoprotein, serum protein electrophoresis, lipoproteins, lysosomal enzymes, copper, ceruloplasmin, ferritin, iron, and paraneoplastic antibodies).

CoQ₁₀ measurement in plasma, fibroblasts and skeletal muscle was performed as described [7].

Molecular genetics

Genetic analysis of mitochondrial DNA (mtDNA) for deletions, depletion, and point mutations in muscle DNA as well as direct sequencing of *POLG*, *PDSS1*, *PDSS2*, *COQ2*, *COQ9*, *CABC1/ADCK3* and *APTX* in blood DNA were normal in all patients [3]. In patient 1, whole exome sequencing was performed in genomic DNA, isolated from lymphocytes (DNeasy[®], Qiagen, Valencia, CA), fragmented and enriched by Illumina TruSeq[™] 62 Mb exome capture, and sequenced (Illumina HiSeq 2000, 100 bp paired-end reads). The in-house bioinformatics pipeline included alignment to the human reference genome (UCSC hg19), reformatting, and variant detection (Varscan v2.2, Dindel v1.01), as described previously [8]. On-target variant filtering excluded those with minor allele frequency greater >0.01 in several databases. Rare homozygous and compound heterozygous variants were defined, and protein altering and/or putative ‘disease causing’ mutations, along with their functional annotation, were identified using ANNOVAR [8]. Putative pathogenic variants were confirmed by Sanger sequencing, using custom-designed primers (<http://frodo.wi.mit.edu>) on an ABI 3130XL (Life Technologies, CA, USA), allowing segregation analyses (Fig. 1a). The primers used for genomic DNA (NG_028216.1) and cDNA (NM_018075.3) analysis of *ANO10* are listed in the Supplementary Materials (Supplemental Tables 1 and 2).

To measure *ANO10* mRNA expression level, skin fibroblasts from the patients were grown and total RNA was extracted using the Pure Link[™] RNA Mini Kit (Ambion, Life Technologies). RNA concentration was measured using a Nanodrop. Subsequently, 100 ng of RNA was converted into cDNA using SuperScript VILO cDNA Synthesis Kit (Invitrogen). Quantitative RT-PCR (qRT-PCR) was performed using TaqMan Assays for *ANO10* and *GAPDH* (Applied Biosystems).

Results

Patient 1 is a 57-year-old English woman who is the second child of healthy, non-consanguineous parents and has a healthy brother. After normal early development she developed generalized epilepsy and learning difficulties at 7 years of age. Her epilepsy was well-controlled, but at age 45 years, she developed gait disturbance, ataxia and slurred speech. She became wheelchair-bound from age 50 years. On examination she had slow saccades but no nystagmus, dysarthria, bilateral dysmetria and a severe trunk ataxia. Although she had no weakness and deep tendon reflexes were

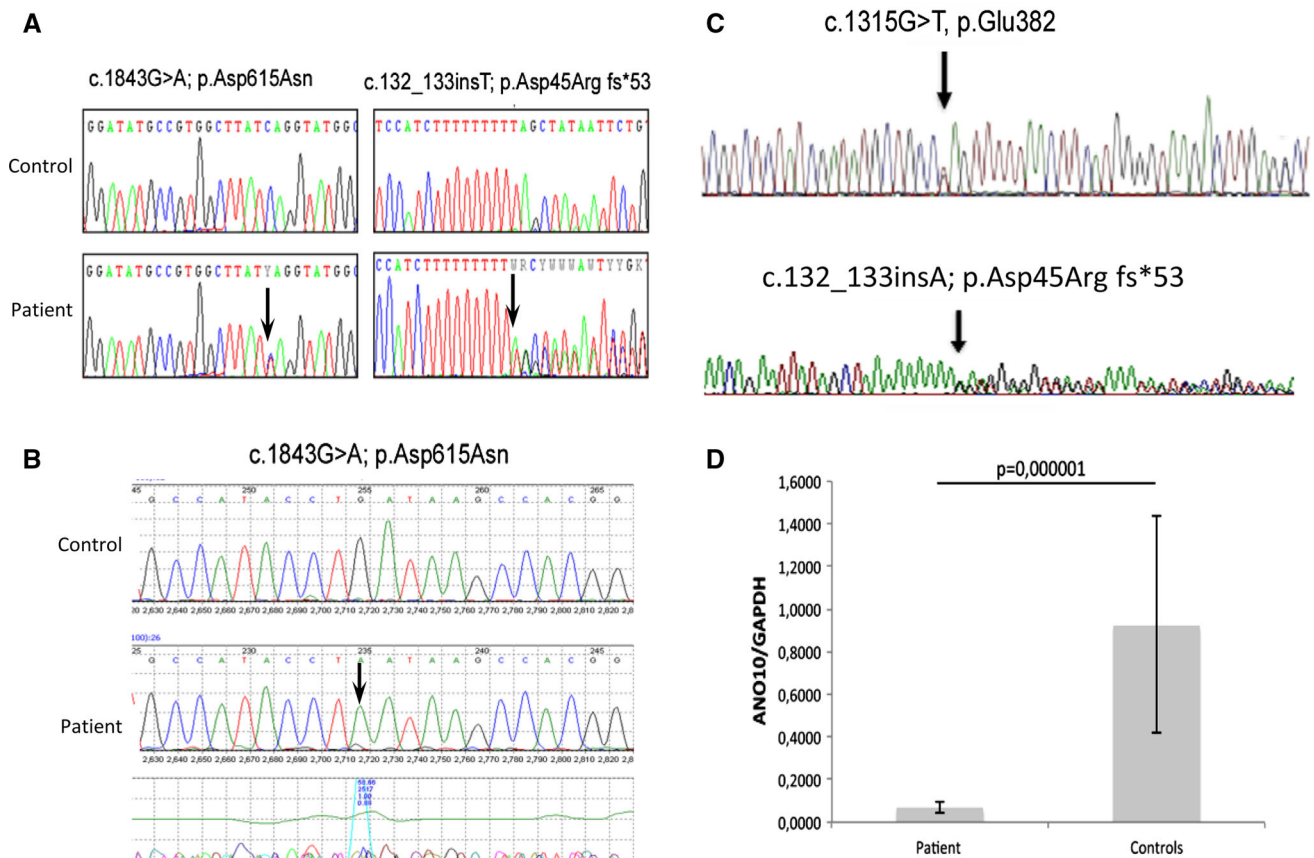


Fig. 1 Detection of heterozygous *ANO10* variants in genomic DNA of patient 1 (a). cDNA analysis of patient 1 detected the c.1843G>A, p.Asp615Asn mutation in hemizygous form, confirming compound heterozygosity (b). Compound heterozygous mutations were detected

normal, she was permanently wheelchair-bound and could not stand or walk due to severe trunk ataxia and had some cognitive dysfunction. Brain MRI revealed marked parieto-occipital and cerebellar atrophy. Nerve conduction studies and electromyography were normal. Skeletal muscle biopsy was performed at age 53 years and showed normal histology, but an isolated complex III deficiency (158 normalize to citrate synthase, normal mean \pm standard deviation 554 ± 345) and low CoQ₁₀ (104 pmol/mg protein, normal range 140–580). CoQ₁₀ in fibroblasts was normal (147 pmol/mg protein, normal range 75–190 pmol/mg protein).

Supplementation with 1,000 mg/day CoQ₁₀ had beneficial effects on the patient's fatigue and mobility within 3–4 months. She was able to stand up and do a few steps and her cognition has slightly improved. She had no seizures and no epileptic activity on her follow-up EEG, therefore, antiepileptic medication was slowly withdrawn.

Genetic analysis

Whole exome sequencing detected potentially disease causing variants in nine genes, but only the variants in

in patient 2 (c), Q-RT-PCR showed significantly decreased *ANO10* mRNA levels in patient 2's fibroblast, compared with controls (d). Values are expressed as mean \pm SD of patient and controls ($N = 3$)

ANO10 segregated with the disease and alter a known disease gene. Two potentially disease causing variants (c.132_133insT; p.Asp45Arg fs*53 and c.1843G>A; p.Asp615Asn) were detected in *ANO10* (Fig. 1a), which were not present in her healthy brother. Unfortunately, both parents of patient 1 had died and she did not have any children. One of the detected mutations was a frame-shift mutation leading to a premature stop codon. The other mutation c.1843G>A; p.Asp615Asn is a missense change of a conserved amino acid that has been detected extremely rarely (rs138000380—1,000 genomes shows only 1 heterozygous) and both mutation taster (0.999) and PolyPhen (0.559) predicted that it is disease causing. cDNA analysis for *ANO10* detected only one allele, which was supported by the hemizygous state of the c.1843G>A; p.Asp615Asn change (Fig. 1b).

The detection of pathogenic *ANO10* mutations in our patient with the ataxic form of CoQ₁₀ deficiency prompted us to perform sequencing of *ANO10* in 36 further patients with low CoQ₁₀ in muscle, fibroblasts, or CSF [3], and we detected pathogenic mutations in one additional patient.

Patient 2 is a 52-year-old woman with neurologically normal non-consanguineous parents, and two healthy siblings. At the age of 30 years, she presented with walking difficulties, slurred speech, and oscillopsia. The walking instability progressed slowly and she developed retinal detachments that were treated with multiple surgeries. At age 50, because of frequent falls, she started to use a walker to ambulate long distance. Other ocular problems include: retinal fibrosis, cataracts, vitreous fluid opacity and possible macular degeneration. Neurological examination revealed a stiff-legged wide-based gait with scissoring, slight eyelid ptosis, primary gaze down-beat nystagmus, and brisk tendon reflexes with ankle clonus, crossed hip adductors, and bilateral Hoffmann signs but Babinski signs were absent. Dysmetria and intention tremor on finger-nose-finger and heel-to-shin test were present. Brain MRI revealed marked cerebellar atrophy involving both lobes and the vermis. Muscle biopsy showed fiber type 2 atrophy. Respiratory chain complex activities measured in muscle tissue were normal.

CoQ₁₀ level in the fibroblasts of the patient (50.6 ± 7.3 nmol/ μ g protein) was normal (concurrent controls 48.3 ± 27.8 nmol/ μ g protein); however, levels of CoQ₁₀ were decreased in plasma (0.41 μ g/ml, normal range 0.8 ± 0.35 μ g/ml) and CSF (410 μ g/l, normal range 450 – 1420 μ g/l); and borderline in muscle (21.2 μ g/g, normal range 32 ± 6 μ g/g).

CoQ₁₀ supplementation (120–180 mg/day) led to an initial mild improvement of the ataxia and gait. Evaluation by the international co-operative ataxia rating scale (ICAR), showed an improvement in the oculomotor movement score (from 4/6 to 3/6) and in the dysarthria score (from 6/8 to 5/8).

Genetic analysis

Direct sequencing of *ANO10* in genomic DNA from patient 2 revealed two heterozygous variants, c.132_133insT; p.Asp45Argfs*53 in exon 2, also present in patient 1, and c.1315G>T, p.Glu382*, in exon 6 (Fig. 1d). Both variants generate premature stop codons with truncated protein of 53 aa and 382 aa, respectively (wild-type protein: 660 aa).

The 2 mutations segregated with the disease in the family (the mother was heterozygous for the c.132_133insT; p.Asp45Argfs*53 variant, both healthy siblings were homozygous wild type; and the father's DNA was not available) and were not detected in 124 ethnically-matched control alleles. cDNA analysis showed a significant reduction of *ANO10* expression level in cultured skin fibroblast from patient 2 compared to controls (Fig. 1d).

Measurement of CoQ₁₀ in fibroblasts of a previously published patient (family B, II:5) [9] in carrying pathogenic *ANO10* mutations was normal result (156 pmol/mg protein, normal range 75–190 pmol/mg protein), however, muscle was not available for CoQ₁₀ analysis.

Discussion

Anoctamin 10 (ANO10), also known as TMEM16 K, is a member of the human anoctamin (ANO) family of proteins, which consists of at least nine other proteins, all containing eight transmembrane domains and a DUF590 domain [9, 10]. It has been suggested that the anoctamin genes encode cell- and tissue-specific calcium-activated chloride channels, however, experimental data are limited [10]. The clinical presentations of mutations in the various

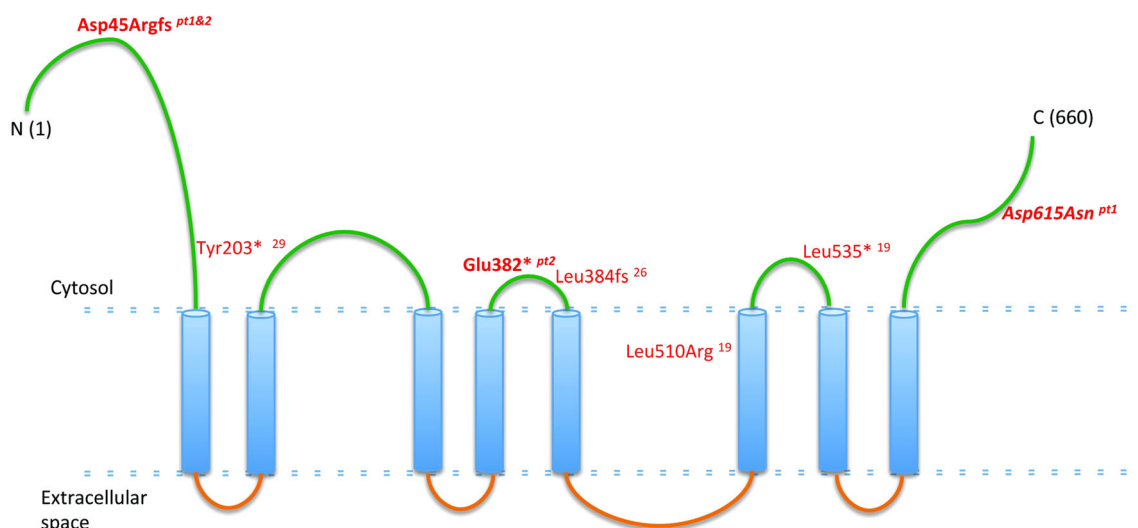


Fig. 2 Schematic representation of ANO10. In *green*: putative intra-cytoplasmic region, in *blue*: putative transmembrane domains, in *orange*: putative extracellular domains. Text in *red*: previously reported mutations; in *bold italic*: mutations found in our patients

Table 1 Clinical summary of patients 1 and 2 reported in this study and the previously reported patients carrying pathogenic *ANO10* mutations

Ref	Age of onset (years)	Country of origin	Genotype	Gait ataxia	Dysarthria	Limb ataxia	Corticospinal tract	MRI	Ophthalmologic features	EMG	Mental retardation	Other features
6	25	Netherlands	c.1529T>G; p.Leu510Arg	++	++	++	↑DTR	EPR CA	Downbeat nys	II MU involvement	-	Cold and blue toes
6	20	Netherlands	c.1529T>G; p.Leu510Arg	++	++	++	↑DTR	CA	Downbeat nys	II MU involvement	-	Wasting and fasciculations proximal leg muscles
6	32	Netherlands	c.1529T>G; p.Leu510Arg	+	+	+	↑DTR	CA	Downbeat nys	NP	-	Cold and blue toes
6	15	Serbia	c.1150_1151del; p.Leu384 fs	++	++	+	↑DTR	CA	Hor and ver nys	NP	+	Inspiratory stridor
6	15	Serbia	c.1150_1151del; p.Leu384 fs	++	+	+	↑DTR	CA	Hor and ver nys	NP	+	Pes cavus
6	13	Serbia	c.1150_1151del; p.Leu384 fs	++	++	+	↑DTR	CA	Hor nys	II MU involvement	-	Fasciculations proximal leg muscles, inspiratory stridor, vocal cord paresis
6	45	France	c.1476 + 1G>T c.1640del; p.Leu535*	+++	++	++	↑DTR	NP	Saccadic pursuit, nys	NP	-	Rest tremor, pes cavus
6	25	France	c.1476 + 1G>T c.1640del; p.Leu535*	++	++	++	↑DTR	CA	Multi-dir nys	Normal	-	Episodic diplopia, pes cavus
8	16	Bulgaria	c.1150_1151del; p.Leu384 fs	+++	++	+	↑DTR	NP	Hor and ver nys	NP	-	NR
8	17	Bulgaria	c.1150_1151del; p.Leu384 fs	++	++	+	↑DTR	EPR CA	Downbeat nys	II MU involvement	+	NR
8	17	Bulgaria	c.1150_1151del; p.Leu384 fs	++	++	+	↑DTR	NP	Downbeat nys	Normal	+	NR
9	46	Japan	c.609C>G; p.Tyr203*	++	++	NA	↑DTR	Mild CA	Saccadic pursuit	Normal	-	Seizures, constipation
P1 (this paper)	7	United Kingdom	c.132_133insT; p.Asp45Argfs c.1843G>A; p.Asp615Asn	+++	++	++	Normal	Parieto-occipital, CA	Saccadic pursuit	Normal	+	Seizures, Low CoQ10 in muscle
P2 (this paper)	30	United States	c.132_133insT; p.Asp45Argfs c.1315G>T; p.Glu382*	++	++	++	↑DTR Hoffman sign	Marked CA	Downbeat nys	Normal	-	Retinal degen, cataract, low CoQ10 in blood and CSF

Ref reference, Age of onset (years), MRI magnetic resonance imaging, + Mild, ++ Moderate, +++ Severe, ↑ increased, DTR deep tendon reflexes, EPR extension plantar reflex, NP not performed, hor horizontal, ver vertical, nys nystagmus, Multi-dir multi-directional, MU motor unit, NA not available, CoQ10 coenzyme Q10, CSF cerebral spinal fluid

anoctamin genes are very heterogeneous, and include limb-girdle muscular dystrophy (*ANO5*), skeletal abnormalities (Gnathodiaphyseal dysplasia due to *ANO5* mutations), blood cell disorders (Scott syndrome caused by *ANO6* defects), as well as progressive neurological presentations of autosomal dominant dystonia (*DYT24* due to *ANO3* mutations) and cerebellar ataxia and atrophy (*ANO10* defects) [10].

Mutations in *ANO10* (Fig. 2) has been associated with autosomal recessive cerebellar ataxia in only five families [9, 11, 12]. The clinical presentation of the previously reported patients showed cerebellar ataxia and atrophy with variable age-at-onset between 13 and 45 years, brisk reflexes, and eye movement abnormalities. Additional features included: intellectual deficit, motor neuron involvement and epilepsy in some but not all patients, illustrating the significant clinical variability (Table 1). Although the clinical presentation of our patients resembles the previously reported cases, and confirms the clinical phenotype of *ANO10* deficiency, muscle biopsies and measurement of CoQ₁₀ have never been assessed before in this condition. Because 2 out of 40 patients (5 %) from our cohort carried mutations in *ANO10*, we suggest that defects in this gene should be considered in patients with unexplained ataxia and low CoQ₁₀ in skeletal muscle.

The low CoQ₁₀ levels and the beneficial effect of CoQ₁₀ supplementation in our patients carrying *ANO10* mutations are unexpected findings and raise the question whether low CoQ₁₀ contributes to the disease pathomechanism, potentially by affecting CoQ₁₀ dependent functions, which was supported by slightly low CoQ₁₀ in fibroblasts of a previously reported patient [9]. Interestingly, in one of our patients, seizures disappeared after CoQ₁₀ supplementation, as previously reported in a patient with CoQ₁₀ deficiency and cerebellar ataxia due to *APTX* mutations [4]. It has been postulated that cerebellar ataxia in patients with *ANO10* deficiency may be due to abnormal calcium signaling in Purkinje cells [10]. Calcium signaling has been shown to be important for mitochondria, and this year, mutations in the gene encoding for the mitochondrial calcium uptake 1 (*MICU1*) protein have been identified in some families with proximal myopathy, learning difficulties and a progressive extrapyramidal movement disorder [13]. The role of *ANO10* and CoQ₁₀ in calcium signaling need to be further investigated. Functional studies in additional patients or animal models will be helpful to characterize the pathomechanism of *ANO10* mutations and will define the role of CoQ₁₀ deficiency in *ANO10*-related disease. The observations of low CoQ₁₀ levels and the beneficial effect of high-dose CoQ₁₀ supplementation in our patients suggest that CoQ₁₀ should be considered in the therapy of *ANO10* deficiency.

Acknowledgments RH was supported by the Medical Research Council (UK) (G1000848) and the European Research Council (309548). PFC is a Wellcome Trust Senior Fellow in Clinical Science and an NIHR Senior Investigator who also receives funding from the Medical Research Council (UK), the UK Parkinson's Disease Society, and the UK NIHR Biomedical Research Centre for Ageing and Age-related disease award to the Newcastle upon Tyne Foundation Hospitals NHS Trust. RWT receives support from the Wellcome Trust Centre for Mitochondrial Research (096919Z/11/Z) and the UK NHS Highly Specialized “Rare Mitochondrial Disorders of Adults and Children” Service. MA is funded by an NIHR CSO Healthcare Scientist research fellowship. VMR was supported by a grant from the Ministry of Science and Technology, Republic of Serbia (Project No. 17 3016; 17 508). HL was supported by the European Union Seventh Framework Programme (FP7/2007-2013) under grant agreement No. 305444 (RD-Connect) and 305121 (Neuromics). We are grateful for the Medical Research Council (MRC) Centre for Neuromuscular Diseases Biobank Newcastle for providing patient cell lines for this project. CMQ is supported by K23HD065871 from the Eunice Kennedy Shriver National Institute of Child Health & Human Development (NICHD), and from a Muscular Dystrophy Association (MDA) grant. MH is supported by NIH Grants R01HD057543, R01HD056103 and U54 NS078059, a MDA grant, and by the Marriott Mitochondrial Disorder Clinical Research Fund (MMDCRF).

Conflicts of interest The authors declare that they have no conflict of interest.

Open Access This article is distributed under the terms of the Creative Commons Attribution License which permits any use, distribution, and reproduction in any medium, provided the original author(s) and the source are credited.

References

1. Anheim M, Tranchant C, Koenig M (2012) The autosomal recessive cerebellar ataxias. *N Engl J Med* 366(7):636–646
2. Németh AH, Kwasniewska AC, Lise S et al (2013) Next generation sequencing for molecular diagnosis of neurological disorders using ataxias as a model. *Brain* 136(Pt 10):3106–3118
3. Emmanuele V, López LC, Berardo A et al (2012) Heterogeneity of coenzyme Q10 deficiency: patient study and literature review. *Arch Neurol* 69(8):978–983
4. Quinzii CM, Kattah AG, Naini A et al (2005) Coenzyme Q deficiency and cerebellar ataxia associated with an aprataxin mutation. *Neurology* 64(3):539–541
5. Mignot C, Apartis E, Durr A et al (2013) Phenotypic variability in *ARCA2* and identification of a core ataxic phenotype with slow progression. *Orphanet J Rare Dis* 8:173
6. Auré K, Benoist JF, Ogier de Baulny H et al (2004) Progression despite replacement of a myopathic form of coenzyme Q10 defect. *Neurology* 63(4):727–729
7. López LC, Schuelke M, Quinzii CM et al (2006) Leigh syndrome with nephropathy and CoQ10 deficiency due to decaprenyl diphosphate synthase subunit 2 (*PDSS2*) mutations. *Am J Hum Genet* 79(6):1125–1129
8. Pfeffer G, Elliott HR, Griffin H et al (2012) Titin mutation segregates with hereditary myopathy with early respiratory failure. *Brain* 135(Pt6):1695–1713
9. Vermeer S, Hoischen A, Meijer RP et al (2010) Targeted next-generation sequencing of a 12.5 Mb homozygous region reveals

- ANO10 mutations in patients with autosomal-recessive cerebellar ataxia. *Am J Hum Genet* 87(6):813–819
10. Duran C, Hartzell HC (2011) Physiological roles and diseases of Tmem16/Anoctamin proteins: are they all chloride channels? *Acta Pharmacol Sin* 32(6):685–692
 11. Chamova T, Florez L, Guergueltcheva V et al (2012) ANO10 c.1150_1151del is a founder mutation causing autosomal recessive cerebellar ataxia in Roma/Gypsies. *J Neurol* 259(5):906–911
 12. Maruyama H, Morino H, Miyamoto R et al (2014) Exome sequencing reveals a novel ANO10 mutation in a Japanese patient with autosomal recessive spinocerebellar ataxia. *Clin Genet* 85(3):296–297
 13. Logan CV, Szabadkai G, Sharpe JA et al (2014) UK10 K Consortium. Loss-of-function mutations in MICU1 cause a brain and muscle disorder linked to primary alterations in mitochondrial calcium signaling. *Nat Genet* 46(2):188–193