

Whiting, R, Phillips, ELW, O'Flynn, D and Antoine, D

Early evidence for cancer in Sudan: an advanced example of bone metastases from ancient Nubia (circa 2500–2050 BCE)

<https://researchonline.ljmu.ac.uk/id/eprint/17645/>

Article

Citation (please note it is advisable to refer to the publisher's version if you intend to cite from this work)

Whiting, R, Phillips, ELW ORCID logoORCID: <https://orcid.org/0000-0001-9989-2536>, O'Flynn, D and Antoine, D (2022) Early evidence for cancer in Sudan: an advanced example of bone metastases from ancient Nubia (circa 2500–2050 BCE). *The Lancet Oncology*. 23 (8). pp. 992-994. ISSN 1470-2045

LJMU has developed [LJMU Research Online](#) for users to access the research output of the University more effectively. Copyright © and Moral Rights for the papers on this site are retained by the individual authors and/or other copyright owners. Users may download and/or print one copy of any article(s) in LJMU Research Online to facilitate their private study or for non-commercial research. You may not engage in further distribution of the material or use it for any profit-making activities or any commercial gain.

The version presented here may differ from the published version or from the version of the record. Please see the repository URL above for details on accessing the published version and note that access may require a subscription.

For more information please contact researchonline@ljmu.ac.uk

Early evidence for cancer in Sudan: an advanced example of bone metastases from ancient Nubia (circa 2500–2050 BCE)

Rebecca Whiting¹, Emma L W Phillips^{1,3}, Daniel O'Flynn², Daniel Antoine¹

¹ Department of Egypt and Sudan, The British Museum; ² Department of Scientific Research, The British Museum; ³ Department of Anthropology and Archaeology, Liverpool John Moores University.

WHO reports that cancer is currently a leading cause of death worldwide. An increasing body of bioarchaeological research offers new insights into the past prevalence, epidemiology, and evolution of cancer.^{1,2,3} An archaeological example from the Northern Dongola Reach in Upper Nubia, Sudan, is presented in this Perspectives piece. In most ancient examples, only the skeleton remains, restricting the body of evidence to individuals with characteristic osseous changes. Such lesions can be primary (originating in the skeleton) or secondary (metastasising from bone or soft tissues).^{3,4} Each new archaeological case adds to this important body of evidence.

Excavated from a Kerma Ancien cemetery (site O16) dated to circa 2500–2050 BCE,⁵ only 30% of the skeleton is preserved and is a probable male (figure). Establishing an approximate age-at-death was not possible due to the poor skeletal preservation, although the original excavation report⁵ suggests that the individual might have been older than 50 years. Various axial lesions described in the excavation report were re-examined using modern clinical^{6–9} and palaeopathological standards,^{3,4} including radiographical analysis. Computed radiography was conducted at the facilities of the Department of Scientific Research of the British Museum (London, UK), using an Y.TU450-D11 x-ray tube (Yxlon International, Hamburg, Germany) with settings of 70 kV and 40 mA, and an exposure time of 300 s.

Osteolytic, osteoblastic, and mixed lesions were recorded in the ribs, spine, and pelvis (figure). Overall, 27 lesion clusters could be identified: eight

osteolytic, five osteoblastic, and 14 mixed lesions. The diverse appearance of these lesions is described according to palaeopathological and clinical guidelines.⁴ In some of the ribs, focal osteolytic lesions appear radiographically to have a defined sclerotic rim (lesion type 1A;⁴ figure 1E). Some of these lesions involve the cortical surface with thinning patches of bone, spicules of new bone, or holes that are linked to larger cavitations below the surface on radiographs. Osteolytic lesions in the vertebrae also have thinning patches of cortical bone, spicules of new bone, or holes communicating with the surface. Radiographically, these lesions differ from those in the ribs in that they have poorly defined margins (lesion type 1C;⁴ figure 1A). Other rib lesions, such as those found on the left sixth rib, are osteoblastic and have a combined radiographic appearance with divergent spicules and lamellated new bone⁸ that extend both out from the periosteum and into the trabecular bone (37 mm by 13 mm in size and extending away from the bone surface by 2 mm; figure 1D). The os coxae, particularly the iliac portions, show extensive osteolytic and osteoblastic changes. These changes include proliferative multilamellated periosteal new bone with areas of macroporosity and microporosity. Where post-mortem fragmentation allowed for a cross-sectional examination, both dense and disorganised new bone is seen filling the trabecular spaces (figure 1C). Osteolytic lesions in the left os coxa have moth-eaten and permeative margins, with multiple small areas of osteolysis intersected by normal bone and diffuse periosteal reaction (lesion types 2 and 3;⁴ figure 1B and 1C). Unfortunately, due to

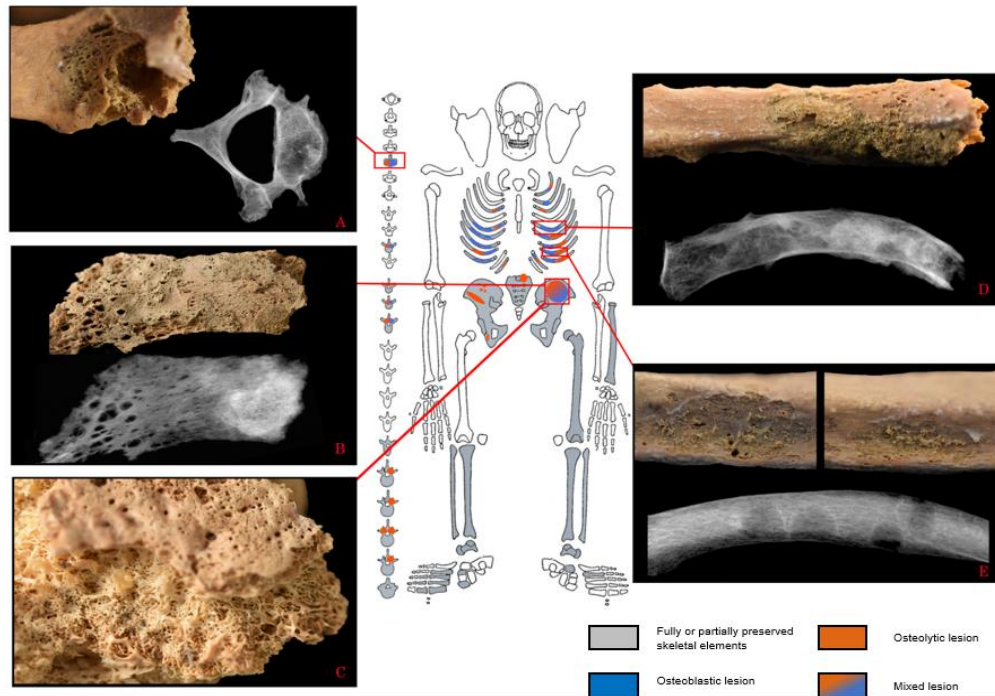


Figure: Skeleton from ancient Nubia with bone metastases

(A) Fifth cervical vertebrae: mixed lesion. Radiograph shows an osteolytic lesion in the vertebral body that is undetectable without radiographic analysis. (B) Left iliac blade fragment (ventral view): a web-like osteolytic lesion is adjacent to and overlaid by reactive new bone and radiodensity is visible on the right. (C) Left iliac blade fragment (dorsal view): new bone formation visible between the trabecular structure, which corresponds to the radiodense area in (B). (D) Left sixth rib (ventral view): osteoblastic lesion visible on the outer surface and osteolytic lesions visible via radiography. (E) Two areas of the left ninth rib (ventral view), with osteolytic thinning of the cortical bone and spicules of new bone visible on the surface: radiography shows corresponding internal osteolytic lesions with clearly defined sclerotic rims. Two further internal osteolytic lesions are also visible. Images are courtesy of the Trustees of the British Museum; skeletal outline was adapted from Michael Schultz, Zentrum Anatomie Göttingen EBV (Göttingen, Germany).

the poor preservation of the os coxae, the full extent of the pathological changes could not be evaluated.

The combined presence of osteolytic, osteoblastic, and mixed lesions in this individual allows solely osteoblastic (eg, osteoid osteoma and osteoblastoma) or osteolytic conditions (eg, chondroblastoma, non-ossifying fibroma, and mycotic infection)⁹ to be excluded from a differential diagnosis.^{3,4} Additionally, some pathological changes tend to primarily affect long bones (eg, giant cell tumour, bone cysts, and osteofibrous dysplasia).³ These changes can also be excluded because radiography showed no such lesions in the long bones. However, several conditions can cause the mixed changes observed here, including various forms of neoplastic disease, osteomyelitis,³ and possibly brucellosis. The dispersed nature of the lesions, a scarcity of proliferative periosteal new bone around many

lesions, and an absence of cloaca precludes osteomyelitis. Although osteolytic lesions in the vertebrae are common in brucellosis, extravertebral lesions are more often found around joints than in the os coxae or ribs.¹⁰ Osteosarcoma is a primary bone tumour that can metastasise to the axial skeleton (particularly the ribs)³ as described. However, osteosarcoma commonly originates in the metaphyses of long bones, which is not the case in this skeleton. Plasma cell myeloma (or multiple myeloma) usually results in the formation of small, regular lesions and is unlikely to have caused the changes seen here, due to the presence of both mixed and osteoblastic lesions.^{11,12} The changes described here are also not suggestive of post-mortem modifications, particularly owing to the presence of clear sclerotic margins and new bone. The irregularly distributed osteolytic and osteoblastic lesions of differing shapes and sizes in the ribs, spine, and pelvis of this skeleton are common in metastatic carcinoma.^{3,6,13,14} Several primary tumour locations

have a propensity to metastasise to the skeleton. Among these locations, breast, prostate, and lung cancers account for 80% of cases with skeletal metastatic lesions.^{15,16} Some of the osteoblastic changes observed in this individual are similar to clinical examples found in prostate cancer, including the infilling and thickening of the trabecular bone observed in the vertebrae.¹⁷ However, without knowing the age and sex of the skeleton, and with an absence of soft tissue evidence, the location of the primary tumour cannot be ascertained. The differential diagnosis suggests that the presence of numerous irregular osteolytic and osteoblastic lesions are most in keeping with a metastatic cancer-induced bone response, probably resulting from a carcinoma, although other malignant neoplasms could cause similar lesions.^{3,4,18} The cemetery from which this individual came consisted of 22 adults and no children or adolescents. Of these 22 adults, there were seven adults of undetermined age. In addition to one example of a button osteoma, no further visible signs of pathological changes suggestive of neoplastic disease were observed in this relatively small cemetery.⁵ Unfortunately, contextualising these findings remains a challenge, because the skeletal remains and the graves they were recovered from were severely damaged by wind erosion leading to varying levels of

preservation. The disturbed nature of the burials has also resulted in a broad date range for when the cemetery was in use.⁵ Further assessment of Kerma period collections will hopefully increase our understanding of the prevalence of neoplastic diseases in these early agropastoral populations, and how they compare to other groups regionally and worldwide.

Several previous archaeological examples of metastatic carcinomas have been reported from Ancient Nubia, including at Wadi Halfa¹⁹ and Sai Island²⁰ (350 BCE to 350 CE), with the oldest confirmed example found at Amara West (1187–1064 BCE).²⁰ As such, the individual described here pushes back the history of metastatic neoplastic disease in Sudan, and most probably in Nubia, by more than 1000 years, and adds to our understanding of the epidemiology of cancer in Nile Valley populations. This remains a complex task that is compounded by differing exposures to risk factors (eg, carcinogens), shorter life expectancies limiting the time available for a soft tissue lesion to spread to the skeleton,³ and the difficulty in identifying cancerous lesions in dry bone.²⁻⁴ This early example adds to a steadily increasing body of evidence and provides further insights into cancer's considerable antiquity.

Bibliography

- Hunt KJ, Roberts C, Kirkpatrick C. Taking stock: A systematic review of archaeological evidence of cancers in human and early hominin remains. *International Journal of Paleopathology* 2018; **21**:12-26.
- Marques C, Roberts C, Matos VM, Buikstra JE. Cancers as rare diseases: Terminological, theoretical, and methodological biases. *International Journal of Paleopathology* 2021; **32**:111-22.
- Waldron T. *Paleopathology*. 2nd ed. Cambridge: Cambridge University Press; 2021. (Cambridge Manuals in Archaeology). 235-254.
- Marques C. Tumors of bone. In: Buikstra JE (ed.) *Ortner's identification of pathological conditions in human skeletal remains*. Academic Press 2019. 639-717.
- Judd MA. The Human Remains. In: Welsby DA (ed.) *Life on the Desert Edge. Seven thousand years of settlement in the Northern Dongola Reach, Sudan*. London: Sudan Archaeological Research Society. 2001. 458-534.
- Greenspan A, Remagen W. Metastases. Differential diagnoses of tumors and tumor-like lesions of bones and joints. Philadelphia: Lippincott-Raven. 1998. :367-87.
- O'Sullivan GJ, Carty FL, Cronin CG. Imaging of bone metastasis: an update. *World journal of radiology*. 2015; **7**(8):202.
- Ragsdale BD, Campbell RA, Kirkpatrick CL. Neoplasm or not? General principles of morphologic analysis of dry bone specimens. *International Journal of Paleopathology*. 2018; **21**(1):27-40.
- Hershkovitz I, Rothschild BM, Dutour O, Greenwald C. Clues to recognition of fungal origin of lytic skeletal lesions. *American Journal of Physical Anthropology*. 1998; **6**(1):47-60.
- Al-Shahed MS, Sharif HS, Haddad MC, Aabed MY, Sammak BM, Mutairi MA. Imaging features of musculoskeletal brucellosis. *Radiographics*. 1994; **14**(2):333-48.
- Yaccoby S. Advances in the understanding of myeloma bone disease and tumour growth. *British journal of haematology*. 2010; **49**(3):311-21.
- Sezer O. Myeloma bone disease: recent advances in biology, diagnosis, and treatment. *The Oncologist*. 2009; **14**(3):276-83.
- Resnick D. *Diagnosis of Bone and Joint Disorders*. St. Louis, MO: W. B. Saunders 1995.
- Rothschild BM, Hershkovitz I, Dutour O. Clues Potentially Distinguishing Lytic Lesions of Multiple Myeloma From Those of Metastatic Carcinoma. *American Journal of Physical Anthropology*. 1998. **105**: 241–250.
- Coleman RE. Skeletal complications of malignancy. *Cancer: Interdisciplinary International Journal of the American Cancer Society*. 1997; **80**(S8):1588-94.
- Macedo F, Ladeira K, Pinho F, Saraiva N, Bonito N, Pinto L, Gonçalves F. Bone metastases: an overview. *Oncology Reviews*. 2017; **11**(1). Available from: <https://www.oncologyreviews.org/site/article/view/321>
- Messiou C, Cook G, Desouza NM. Imaging metastatic bone disease from carcinoma of the prostate. *British journal of cancer*. 2009; **101**(8):1225-32.
- Disler DG, Miklic D. Imaging findings in tumours of the sacrum. *American Journal of Roentgenology*. 1999; **173**(6):1699-1706.
- Esche E, Mummert A, Robinson J, Armelagos GJ. Cancer in Egypt and Nubia. *Anthropologie* (1962-). 2010; **48**(2):133-40.
- Binder M, Roberts C, Spencer N, Antoine D, Cartwright C. On the antiquity of cancer: Evidence for metastatic carcinoma in a young man from Ancient Nubia (c. 1200BC). *PloS one* 2014; **9**(3):e90924