



LJMU Research Online

Jabbar, AAJ, Abdul-Aziz Ahmed, K, Abdulla, MA, Abdullah, FO, Salehen, NA, Mothana, RA, Houssaini, J, Hassan, RR, Hawwal, MF, Fantoukh, OI and Hasson, S

Sinomenine accelerate wound healing in rats by augmentation of antioxidant, anti-inflammatory, immunohistochemical pathways

<http://researchonline.ljmu.ac.uk/id/eprint/23335/>

Article

Citation (please note it is advisable to refer to the publisher's version if you intend to cite from this work)


Jabbar, AAJ, Abdul-Aziz Ahmed, K, Abdulla, MA, Abdullah, FO, Salehen, NA, Mothana, RA, Houssaini, J, Hassan, RR, Hawwal, MF, Fantoukh, OI and Hasson, S (2023) Sinomenine accelerate wound healing in rats by augmentation of antioxidant. anti-inflammatory. immunohistochemical

LJMU has developed **LJMU Research Online** for users to access the research output of the University more effectively. Copyright © and Moral Rights for the papers on this site are retained by the individual authors and/or other copyright owners. Users may download and/or print one copy of any article(s) in LJMU Research Online to facilitate their private study or for non-commercial research. You may not engage in further distribution of the material or use it for any profit-making activities or any commercial gain.

The version presented here may differ from the published version or from the version of the record. Please see the repository URL above for details on accessing the published version and note that access may require a subscription.

For more information please contact researchonline@ljmu.ac.uk

<http://researchonline.ljmu.ac.uk/>



Sinomenine accelerate wound healing in rats by augmentation of antioxidant, anti-inflammatory, immunohistochemical pathways

Ahmed A.j. Jabbar^{a,*}, Khaled Abdul-Aziz Ahmed^b, Mahmood Ameen Abdulla^c,
Fuad Othman Abdulla^{d,e}, Nur Ain Salehen^f, Ramzi A. Mothana^g,
Jamal Houssaini^{h,i}, Rawaz Rizgar Hassan^j, Mohammed F. Hawwal^g,
Omer I. Fantoukh^g, Sidgi Hasson^k

^a Department of Medical Laboratory Technology, Erbil Technical Health and Medical College, Erbil Polytechnic University, Erbil, 44001, Iraq

^b Department of Medical Laboratory Sciences, Faculty of Allied Medical Sciences, Al-Ahliyya Amman University, Amman, Jordan

^c Department of Medical Microbiology, College of Science, Cihan University-Erbil, Erbil, Kurdistan Region, Iraq

^d Department of Chemistry, College of Science, Salahaddin University-Erbil, Kurdistan Region, Erbil, 44001, Iraq

^e Department of Pharmacognosy, Faculty of Pharmacy, Tishk International University, Erbil, 44001, Iraq

^f Department of Biomedical Sciences, Faculty of Medicine, University of Malaya, Kuala Lumpur, 50603, Malaysia

^g Department of Pharmacognosy, College of Pharmacy, King Saud University, Riyadh, 11451, Saudi Arabia

^h Department of Laboratory and Forensic Medicine (I-PPerForM), Institute of Pathology, Universiti Teknologi MARA (UiTM), 47000, Sungai Buloh, Selangor, Malaysia

ⁱ Department of Medical Microbiology and Parasitology, Faculty of Medicine, Sungai Buloh Campus, Universiti Teknologi MARA (UiTM), 47000, Sungai Buloh, Selangor, Malaysia

^j Department of Medical Laboratory Science, College of Science, Knowledge University, Kirkuk Road, Erbil, 44001, Iraq

^k School of Pharmacy and Biomolecular Sciences, Liverpool John Moores University, Liverpool, L3 5UG, UK

ARTICLE INFO

Keywords:

Sinomenine

Wound

Histology

Antioxidants

Immunohistochemicals

Inflammatory cytokines

ABSTRACT

Sinomenine (SN) is a well-documented unique plant alkaloid extracted from many herbal medicines. The present study evaluates the wound healing potentials of SN on dorsal neck injury in rats. A uniform cut was created on Sprague Dawley rats (24) which were arbitrarily aligned into 4 groups receiving two daily topical treatments for 14 days as follows: A, rats had gum acacia; B, rats addressed with intrasite gel; C and D, rats had 30 and 60 mg/ml of SN, respectively. The acute toxicity trial revealed the absence of any toxic signs in rats after two weeks of ingestion of 30 and 300 mg/kg of SN. SN-treated rats showed smaller wound areas and higher wound closure percentages compared to vehicle rats after 5, 10, and 15 days of skin excision. Histological evaluation of recovered wound tissues showed increased collagen deposition, fibroblast content, and decreased inflammatory cells in granulated tissues in SN-addressed rats, which were statistically different from that of gum acacia-treated rats. SN treatment caused positive augmentation of Transforming Growth Factor Beta 1 (angiogenetic factor) in wound tissues, denoting a higher conversion rate of fibroblast into myofibroblast (angiogenesis) that results in faster wound healing action. Increased antioxidant enzymes (SOD and CAT), as well as decreased MDA contents in recovered wound tissues of SN-treated rats, suggest the antioxidant potentials of SN that

* Corresponding author.

E-mail addresses: ahmed.abuljabbar@epu.edu.iq (A.A.j. Jabbar), k.ahmed@ammanu.edu.jo (K. Abdul-Aziz Ahmed), mahmood.ameen@cihanuniversity.edu.iq (M.A. Abdulla), fuad.abdullah@su.edu.krd (F.O. Abdulla), nurain36@um.edu.my (N.A. Salehen), rmothana@ksu.edu.sa (R.A. Mothana), jamalh@uitm.edu.my (J. Houssaini), rawaz.hassan@knu.edu.iq (R.R. Hassan), mhawwal@ksu.edu.sa (M.F. Hawwal), ofantoukh@ksu.edu.sa (O.I. Fantoukh), s.s.hasson@ljmu.ac.uk (S. Hasson).

<https://doi.org/10.1016/j.heliyon.2023.e23581>

Received 15 September 2023; Received in revised form 6 December 2023; Accepted 6 December 2023

Available online 11 December 2023

2405-8440/© 2023 The Authors. Published by Elsevier Ltd. This is an open access article under the CC BY-NC-ND license (<http://creativecommons.org/licenses/by-nc-nd/4.0/>).

aid in faster wound recovery. Wound tissue homogenates showed higher hydroxyproline amino acid (collagen content) values in SN-treated rats than in vehicle rats. SN treatment suppressed the production of pro-inflammatory cytokines and increased anti-inflammatory cytokines in the serum of wounded rats. The outcomes present SN as a viable pharmaceutical agent for wound healing evidenced by its positive modulation of the antioxidant, immunohistochemically proteins, hydroxyproline, and anti-inflammatory cytokines.

1. Introduction

The skin injury is an abrasion of epidermal layer of skin that initiates a dynamic, intricate, and complex process called wound healing to establish the integrity, structure, and function of damaged tissues. Wound recovery is crucial to avoid the penetration of injured tissues by microbes and to partially or completely reform the damaged tissues. This biological cascade began at the time of tissue injury and continue to various periods based on the wounding type [1]. Wound healing is an intricate recovery process that can be categorized into three biological stages: the inflammatory phase, which includes oxidative stress, inflammation, and blood clotting along with new tissue formation (regeneration); proliferation phase, in which granulation of tissues and epithelialization takes place; remodeling phase, includes migration of keratinocytes of the damaged upper skin layer (epidermis) and hair follicles, followed by cellular proliferation around areas of the wound. After that, keratinocytes and other skin tissues were Re-differentiated to regain the barrier function. Fibroblasts can play a major role in the wound healing process by participating in the curing stages of the damaged skin layers (dermis) [2]. The proliferation of fibroblasts allows them to reach areas where skin penetration occurred and can enhance the formation of a new extracellular matrix, as well as provide thick myofibroblast bundles aiding in faster wound closure [3]. The UK's National Health Service (NHS) recorded 3.8 million wound cases including, chronic and acute wounds, in 2017/2018. The wound recovery percentage was higher (59 %) in patients with chronic wounds not related to infection compared to that (45 %) of cured wounds related to clear or suspected infection [4]. Wound management immediately after skin injury can avoid pathogenic infection and hence faster wound-healing process. Therefore, emergency aids are of great importance to be made available in every corner as personal preparedness for unexpected natural and human accidents. Nowadays, many wound therapeutics have been utilized for curing wounds including growth factors, plasma, gene, and cell therapies. Medicinal Plants and their natural products can accelerate the wound healing process and reduce the wound closure time [5,6].

Medicinal plants and their chemicals represent a substantial part of the global therapeutic market. Ethnobotanical studies revealed that herbal medicine has been utilized for treating many human diseases by different nations for thousands of years [7,8]. Though literature data provide their therapeutic benefits, a precise technique for quality measurement of herbal products concerning their characterization (pharmacological, biological, phytochemical, and therapeutic actions) is absent. Standardization of herbal medicine validates their safety, consistency, and therapeutic effectiveness [9]. Natural resources and Plants are investigated for their phyto-chemical content, toxicity, and quality of their extract to validate their use as medicinal (pharmaceutical) agents against human disorders [10–12]. Medicinal plants and their chemical contents can have great therapeutic potentials to cure numerous skin disorders including wound healing, skin infection, inflammation, skin rash and bruises, ulcers, scabies, venereal disease, and leprosy. Medicinal plants can have antioxidant, anti-inflammatory, disinfection, and debridement properties, which all aid in a faster wound-healing process [13,14]. Moreover, natural products may provide a moisturized environment for skin that helps in the natural recovery of damaged tissues. Mankind has utilized numerous plant species as folkloric remedies for managing wounds, skin cuts, and burns, most of which have no phytochemical and pharmacological records [15].

Sinomenium acutum is a deciduous evergreen climbing plant that has been utilized as Chinese herbal medicine for treating arrhythmia, neuralgia, and rheumatoid arthritis [16]. The *sinomenium acutum* root was the original source of an alkaloid called sinomenine, a chemical that can exhibit numerous pharmacological potentials including anti-angiogenic, anti-rheumatic, and immunomodulatory actions [17]. Recent *in vitro* and *in vivo* clinical trials have shown numerous biological potentials of this alkaloid (sinomenine), including antioxidant [18], anti-microbial [19], anti-inflammation [20], anticancer [21], antiviral [22], antidiabetic [23], anti-hypertensive [24], and anti-nociceptive (analgesia) actions [25]. Sinomenine has shown effective therapeutic actions against cardiovascular disease in rats [26]. SN treatment had attenuated effects on the cardiac hypertrophy by positive modulation of Nrf2/ARE signaling pathway as previously explained by *in vivo* and *in vitro* trials [27]. SN ingestion can have a protective effect against cerebral ischemia–reperfusion in rats, which was correlated with its anti-inflammatory property that can inhibit acidosis (Acid-sensing ion channel) and improve energy metabolism [28]. Moreover, SN has been postulated as an active ingredient that can enhance drug pharmacokinetics mainly by improving drug absorption and decreasing drug metabolism [29]. Despite the pharmacological importance of this alkaloid (sinomenine), its therapeutic potential on the skin disorders and wound healing process has yet to be discussed.

Here, the present investigation targets whether the sinomenine, purchased commercially, can accelerate the process of wound healing in the dorsal neck-injured rats, if so, the molecular mechanism behind this action was investigated by histopathological, immunohistochemical, and biochemical assay.

2. Material and methods

2.1. Acute toxicity

The acute toxicity test was followed to evaluate the safety of oral ingestion of SN in rats at 30 and 300 mg/kg doses based on OECD-423 standards [30]. Briefly, Sprague Dawley rats (18 males and 18 females) aged 7–8 weeks and weighted between 180 and 200 g were distributed randomly into 3 groups: vehicle, rats fed on a normal diet; low dose group, rats supplemented with 30 mg/mg of SN; high dose group, rats dieted with 300 mg/kg of NS. Before the oral supplementation, rats were fasting overnight fasting and After supplementation, rats were not allowed to had food and water for another 3–4 h. The observational process started at 30 min after treatment and following the 24 h to detect toxic signs and symptoms (shortness of breath, Mild tremor, frightened, and eye color). Physiological changes such as changes in the respiration, locomotion, exophthalmus, skin piloerection, and salivation between experimental rats were continuously checked. After 14 days of trial, on the 15th day, rats were given an overdose of anesthesia injection containing 0.04 ml of xylazine (3 mg/kg) and 0.36 ml of ketamine (300 mg/kg) and sacrificed to evaluate serum content and histology of liver and kidney based on the previously detailed procedure [31].

2.2. Wound healing experiment

2.2.1. Chemicals for wound experiment

The intrasite gel (reference) bought from the pharmacy, which is a skin therapeutic consists of carboxymethyl cellulose (CMC) polymer (2.3 %) and propylene (20 %). Gum acacia (vehicle) were purchased from a local shop [32]. Sinomenine was bought commercially from an American brand company (Sigma-Aldrich Chemical, USA). SN was poured into a standard solution (10 % Tween 20) for dissolving and then stored in dark vials for later use.

2.2.2. Excision wound healing in rats

Sprague Dawley rats were randomly distributed into four clusters (6 rats each) weighted from 180 to 200 mg. Rats were kept in standard mesh wire cages and provided with tap water and a standard diet (rat pellet). For cutting surgery, at first, all rats were given a small dose of anesthesia injection of xylazine (12.5 mg/kg) and ketamine (87.5 mg/kg). The dorsal neck skin was cleaned by an electrical shaver and wiped with 70 % alcohol. A precise equal cut of about 2.00 cm in diameter was created on the dorsal neck (from the nape) in all experimental groups by using an even and round seal as seen in Fig. 1 [11]. After that rats received twice daily topical treatment as follows:

Group A, rats were addressed with 0.2 ml of gum acacia (vehicle).

Group B, rats treated with 0.2 ml of intrasite gel (reference).

Group C, rats received 0.2 ml of 30 mg/ml of SN (low dose).

Group D, rats received 0.2 ml of 60 mg/ml of SN (high dose).

The wound area contraction was measured manually by highlighting it in square millimeters. The areas near the closure of wounds were detected at days 0, 5, 10, and 15 after excision. The percentage of wound closure was determined by utilizing a transparency paper and a marker after a partial rat anesthetization by an anesthesia injections containing 0.02 ml of xylazine (3 mg/kg) and 0.18 ml of ketamine (300 mg/kg) [33]. The graph paper (1 mm²) was relied on to find the wound size, and the transparent paper was important to trace the wound area and area of epithelized tissues. The paper squares and the wound area on a particular day after surgery are determined, and the closure percentage of wounds is calculated by the following equations:

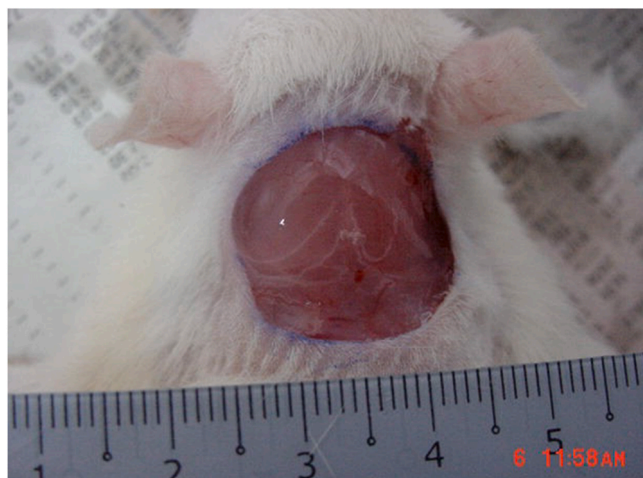

Fig. 1. Excisional view of wound area on dorsal neck was created in all rats on day 0, before treatment.

Closure percentage % = [(area of wound at day 0 – wound area at particular day X)/(wound area at day 0)] × 100 [34].

After final wound closure measurement at day 15, rats were anesthetized and a piece of skin from healed area was excised for the preparation of a homogenous tissue for histopathological examination. Moreover, the blood samples were obtained from intracardiac puncture for different laboratory investigations.

2.2.3. Histology of wound tissues

The histopathological evaluations of the recovered wound tissues were possible by utilizing different staining procedures. At first, the precise amount of skin obtained from wound healed areas and transferred into 10 % phosphate-buffered formalin. After that, skin tissue samples were processed by an automated machine for paraffinization, followed by fixation on slides for staining by using hematoxylin and eosin and Masson's trichrome stains. After that, the slides were examined under a light microscope (Nikon). The histological estimation included several tissue characteristics: epithelialization, deposition of collagen, infiltration of inflammatory cells, fibroblast proliferation, and neovascularization [35,36].

2.2.4. Immunohistochemistry

The immunohistochemical investigation was based on the streptavidin-biotin technique, as explained previously [37]. Briefly, the endogenous peroxidase was blocked by mixing 3 % hydrogen peroxide and ethanol solutions for 10 min. The mixed solution was incubated for overnight at room temperature along with the primary antibodies: TGF - β (Clone sc-146) diluted antibody 1:50. The slides were incubated again with the biotinylated second antibody and streptavidin-peroxidase for 45 min. Finally, Mayer's hematoxylin was poured as counterstain on tissue samples.

2.2.5. Wound tissue homogenate

The skin tissue samples from recovered wound areas on day 15 were obtained and homogenized using a Teflon homogenizer (Polytron, Germany) at 4 °C. After that, the tissue mixture was centrifuged at 4500 rpm for 15 min at 4 °C. The supernatant was

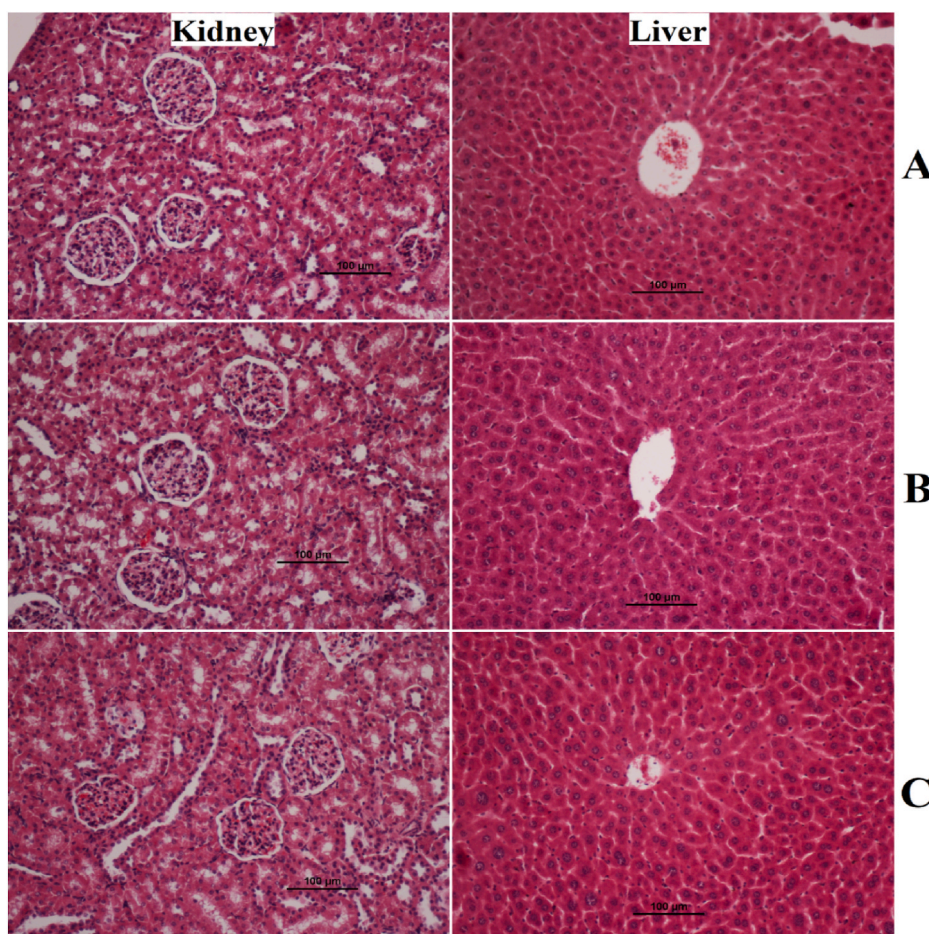


Fig. 2. Histology Effects of SN on rats in acute toxicity trial. A, normal control; B, low dose (30 mg/kg) of SN extract; C, high dose (300 mg/kg) of SN.

transferred into different tubes and evaluated for the amount of SOD, CAT, and MDA contents by utilizing enzyme-linked immunosorbent assay (ELISA) kits following the company's instructions. The antioxidant kits were purchased from a China company (CUSABIO Biotech Co., Ltd, Wuhan) [11,38].

2.2.6. Hydroxyproline

The recovered skin tissues were homogenized at 4 °C by a Teflon homogenizer (Polytron, Germany). The tissue mixture was centrifuged at 4500 rpm for 15 min at 4 °C, the supernatant was analyzed for hydroxyproline (HXP) concentrations. The HXP assay was in accordance with instructions given by the producer company (Sigma Aldrich, USA) [39].

2.2.7. Inflammatory cytokine estimation

The collected blood samples from intracardiac puncture of rats were readily obtained at day 15 and centrifuged to obtain the supernatant (serum). The serum sample investigation for the inflammatory cytokines (TNF- α , IL-6, and IL-10) contents was possible through commercial kits in an ELISA machine (Elabscience, Wuhan, China) based on the instructions mentioned in the leaflets [40].

3. Results

3.1. Acute toxicity

The current study revealed the safety of SN ingestion (30 and 300 mg/kg) in a 14-day rat trial. The observation process showed absence of toxic signs or physiological changes in rats. The present data revealed that topical application of sinomenine did cause any abnormalities and symptoms (restlessness, wound area bite, irritation, and pain) in rats. Moreover, physical activity and feed intake were very comparable between supplemented rats and normal control rats. Histological examination of experimental rats showed comparable tissue structure of kidney and liver tissues without any noticeable changes (Fig. 2A–C). The current study expects that the toxic dosage of SN exceeds 300 mg/kg. Moreover, biochemical results of liver and functional parameters were also very similar between normal control and plant-treated rats (data not shown but can be provided on request).

3.2. Wound experiment

3.2.1. Wound size and closure percentage

The topical application of SN (30 and 60 mg/ml) lead to noticeable wound healing compared to vehicle rats. Experimental rats experienced different wound healing rates based on histological and epidermal evaluations at 5, 10, and 15 days after injury. Vehicle rats had the highest wound area during all three periods of measurements. Rats received intrasite gel or sinomenine (30 and 60 mg/ml) showed significant wound tissue recovery represented by noticeably lower wound area and higher wound closure percentages compared to that of vehicle rats. After 15 days of treatment, the closure percentages of wound area were significantly higher (93.02 %) in SN-treated rats than that (79.77 %) of vehicle rats. However, the wound area and the closure percentages of sinomenine-treated rats were very similar and statistically non-significant compared to that of intrasite-treated rats at day 15 after surgery as shown in Table 1 and Fig. 5.

Gross morphology analysis revealed the lowest wound closure percentage in gum acacia-treated rats at day 5 (Fig. 3A–D), day 10 (Fig. 4A–D), and day 15 (Fig. 5A–D) after injury, compared to all treated rats. The closure percentage of wounds gradually increased in all treated rats as the time passed. The closure % was almost the same on 5 days of the procedure in rats that received intrasite gel or sinomenine (Fig. 3B–D). While, after 10 and 15 days of treatment, rats in group D (0.2 ml of 60 mg/ml) had a larger percentage of wound closure (93.02 %) than that (79.77 and 89.93 %) of vehicle and 30 mg/ml SN-treated rats, respectively, but the values of group D were very similar to that (94.28 %) of intrasite gel-treated rats (Table 1 and Figs. 4 and 5).

3.2.2. Histopathological effect of SN in wound tissues

Histopathological examination of wound tissues after the surgery on day 15 took place by applying hematoxyline and eosin (H & E) and Masson Trichrome staining assays. As shown in Fig. 6 (A–D), skin tissues stained with H & E revealed areas in 0.2 ml of 30 and 60 mg/ml sinomenine or intrasite gel-treated rats, which were less than that of gum acacia-treated rats (vehicle). Rats received 60 mg/ml

Table 1

Effect of SN on wound area and wound closure % in rats at different periods after skin injury.

Clusters	Wound area mm ²		Day 5 Closure %	Wound area mm ²		Day 15 Closure %
	Day 0	Day 5		Day 10	Day 15	
A	235 ± 0.56	163.5 ± 3.2 ^c	30.42	93.44 ± 0.34	60.23 ^b	79.77 ^b
B	235 ± 0.46	90.32 ± 2.43 ^a	61.56	38.54 ± 1.8 ^a	83.60 ^a	94.28 ^a
C	235 ± 0.44	94.5 ± 2.32 ^b	59.78	48.20 ± 2.2 ^b	79.48 ^a	89.93 ^a
D	235 ± 0.66	92.43 ± 2.24 ^b	60.66	41.20 ± 2.3 ^b	82.46 ^a	93.02 ^a

Data are shown as Mean values ± SEM (n = 6). Different letters on values within the same column were statistically significant at $P < 0.05$. A, Vehicle rats had Gum acacia solution; B, rats received Intrasite gel (reference); C, rats received topically 0.2 ml of 30 mg/ml of SN on their wound area; D, rats treated with 0.2 ml of 300 mg/ml of SN.

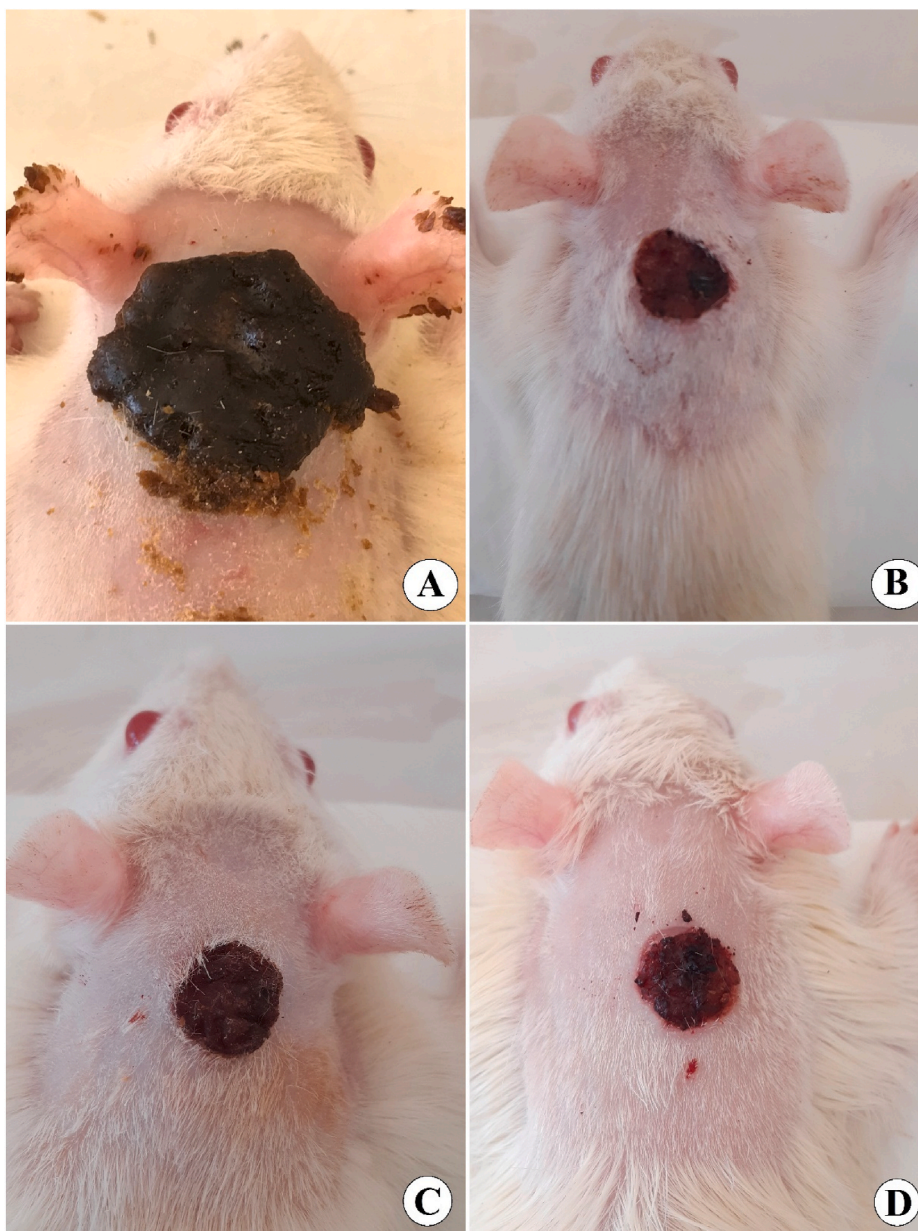
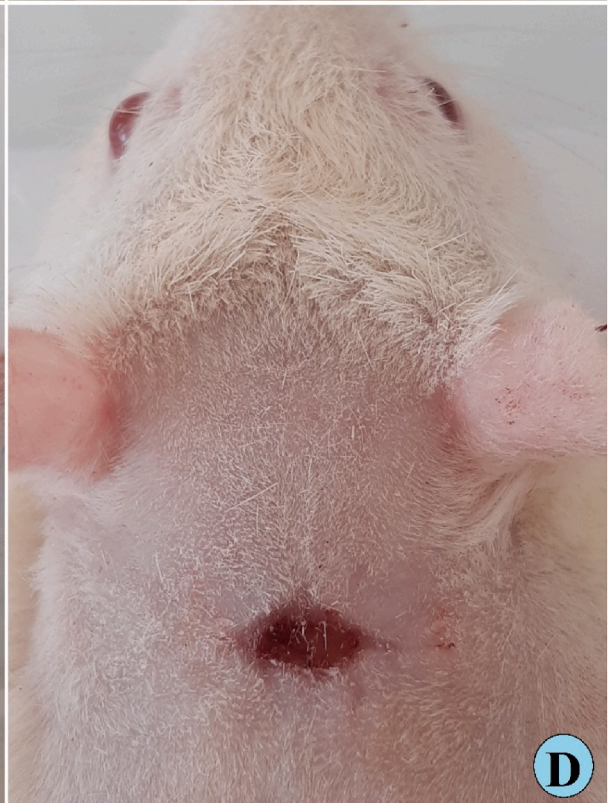
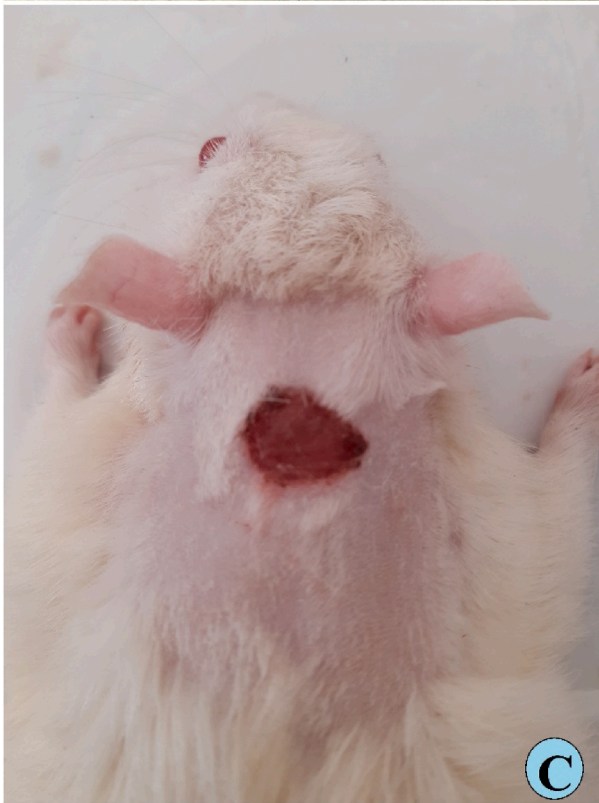
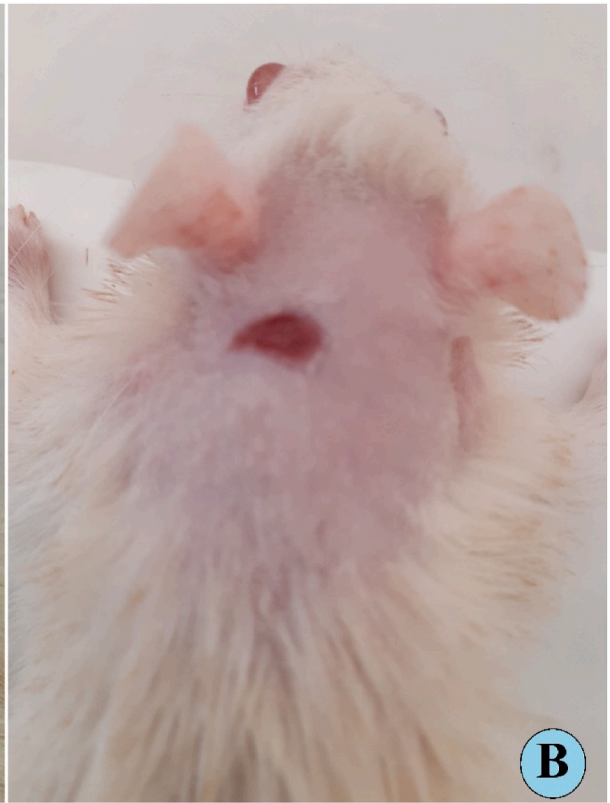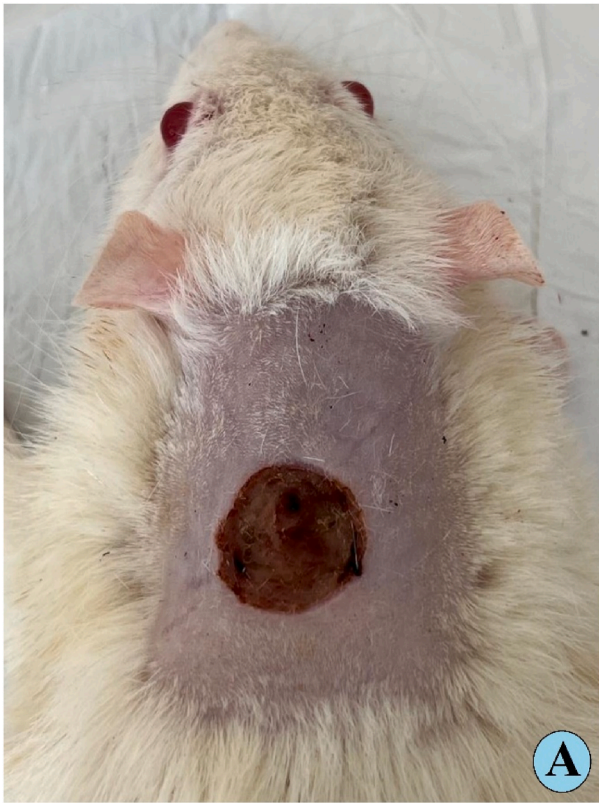Fig. 3. Gross appearance of wound curing on day five after wounding. A, vehicle rats had 0.2 ml of Gum acacia solution on their skin; B, rats received 0.2 ml of intrasite gel (reference) showed much small wound size compared to vehicle rats; C, rats received 0.2 ml of 30 mg/ml of SN revealed significant moderate wound healing; D, rats treated with 0.2 ml of 60 mg/ml SN showed noticeably smaller wound area (mm^2) and elevated percentages of wound closure compared to that of the vehicle and 30 mg/ml SN-treated rats.

sinomenine demonstrated very similar wound area appearance compared to that of intrasite gel-treated rats. Sinomenine treatment caused some serious positive augmentation in wound tissues, including reduced inflammatory cells, more collagen formation, and more blood capillaries (angiogenesis) in the granulated tissues (Fig. 6 (A-D) and 7 (A-D)). The histological evaluation of tissues stained by Masson Trichrome revealed significant differences in the levels of dermis growth and collagen fiber formation in the experimental rats. Vehicle (gum acacia) rats had poor organization of collagen fibers and reduced skin tissue growth based on Masson's trichrome staining technique. Moreover, inflammatory cells involved in the wound healing process are markedly scattered in the wound area with less granulated cells, indicating remarkable immaturities of skin tissues. However, rats treated with sinomenine showed elevated formation and deposition of collagen fibers in the more organized form, which were similar to that of intrasite gel-treated rats (reference) as shown in Fig. 8(A-D) and 9 (A-D) (see Fig. 9) (see Fig. 7).



(caption on next page)

Fig. 4. Gross morphology of wound healing on day ten after wounding in rats. A, vehicle rats had 0.2 ml of Gum acacia solution on their skin; B, rats received 0.2 ml of intrasite gel (reference) showed reduced wound area and higher percentage of wound curing than that of vehicle rats; C, rats received 0.2 ml of 30 mg/ml SN showed moderately recovered wounded skin; D, rats treated with 0.2 ml of 60 mg/ml SN had significantly smaller wound area (mm^2) and increased percentages of wound closure compared to that of the vehicle and 30 mg/ml SN-treated rats.

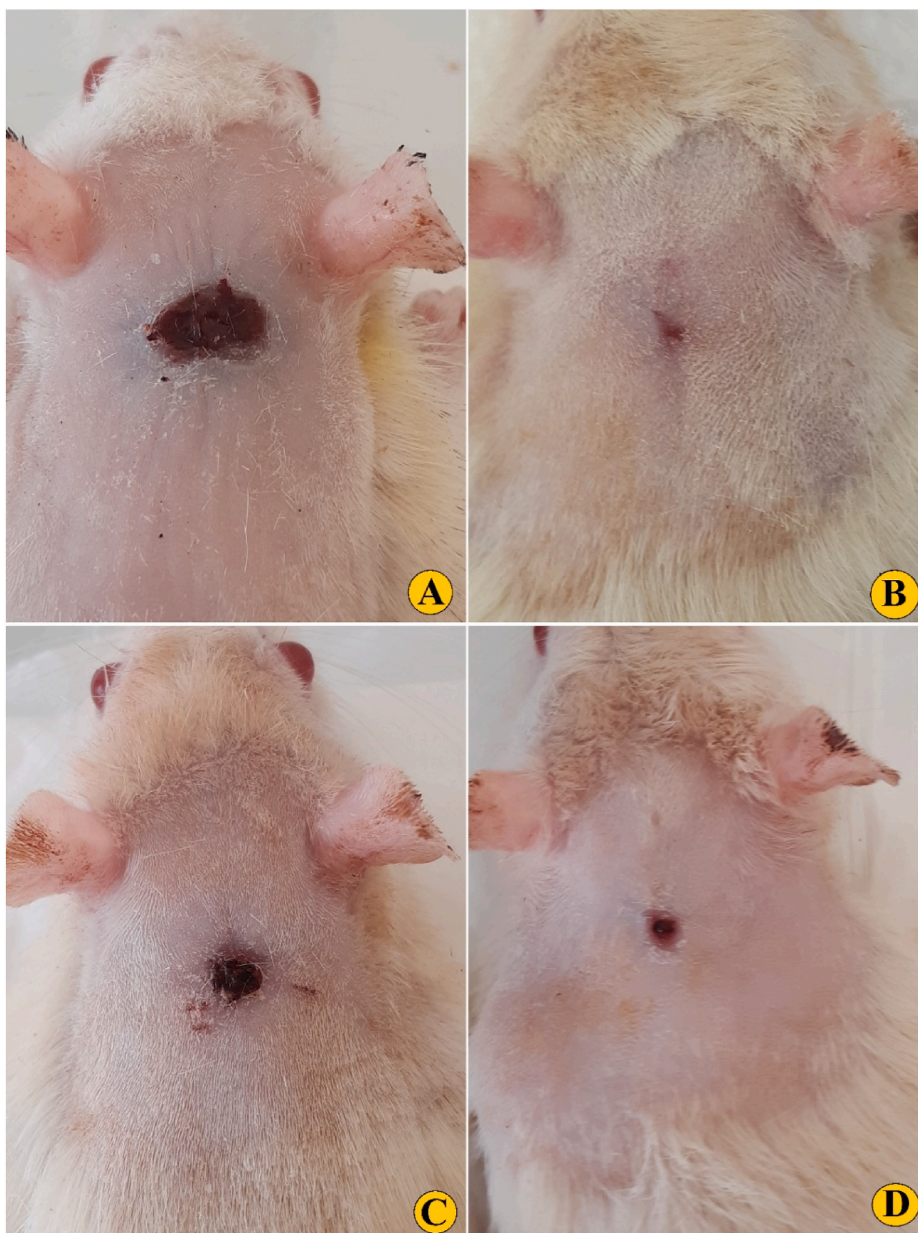


Fig. 5. Gross morphology of wound healing on day 15 after surgery, A, vehicle rats had 0.2 ml of Gum acacia solution on their skin; B, rats received 0.2 ml of intrasite gel (reference) showed reduced wound area and higher percentage of wound curing than that of vehicle rats; C, rats received 0.2 ml of 30 mg/ml SN showed moderately recovered wounded skin; D, rats treated with 0.2 ml of 60 mg/ml SN had significantly smaller wound area (mm^2) and increased percentages of wound closure compared to that of the vehicle and 30 mg/ml SN-treated rats.

3.2.3. Effect of SN induced increased expression of TGF- β 1 protein in wound tissues

Histopathological results showed different levels of TGF- β 1 expressions in wound tissues at day 15 after skin wounding in rats (Fig. 10A–D). In the vehicle (gum acacia) rats, the expression of TGF- β 1 was found much lower compared to that of all rat groups. Contrarily, the appearance of TGF- β 1 immunoreactive cells in the newly forming granulation tissue was remarkably higher in the 30 and 60 mg/ml SN-treated rats than that of the vehicle rats (Fig. 10C and D). These results denote significant prompting effects of SN on

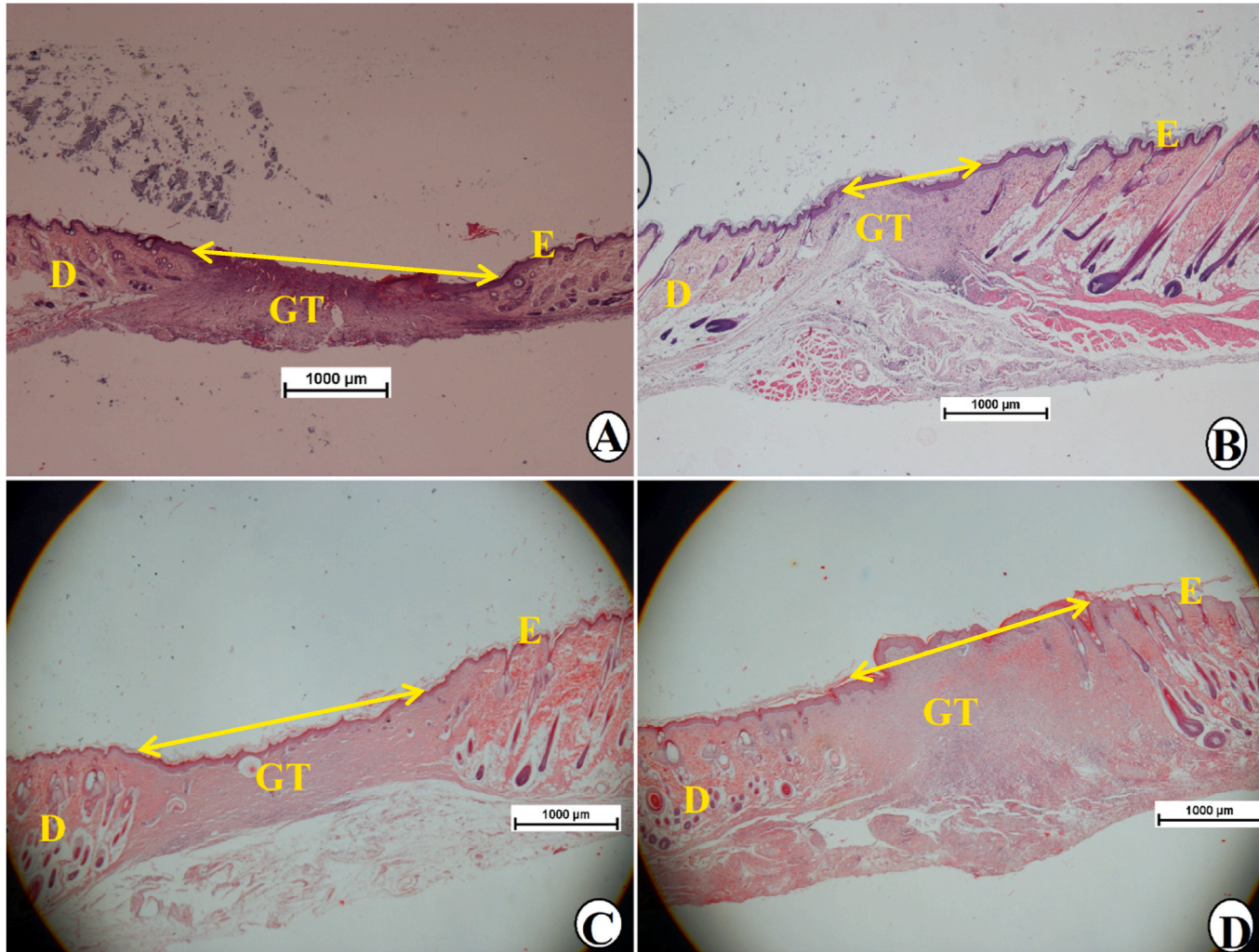


Fig. 6. Low magnification of microscopic views of wounded tissue by using Hematoxylin and Eosin stains on day 15 after surgery. A, skin tissues from rats addressed with 0.2 ml of gum acacia (vehicle) showed a very wide wound area; B, rats treated 0.2 ml of intrasite gel with revealed significantly smallest wound area compared to all experimental rats; C, rats treated with 0.2 ml of 30 mg/ml of SN, moderate closure of wound area; D, rats treated with 0.2 ml of 60 mg/ml of SN, showed a very small area of wounded skin compared to that of vehicle. D, dermis; E, epidermis; GT, granulation tissue; yellow arrow, wound closure area (H&E stains, 2 \times).

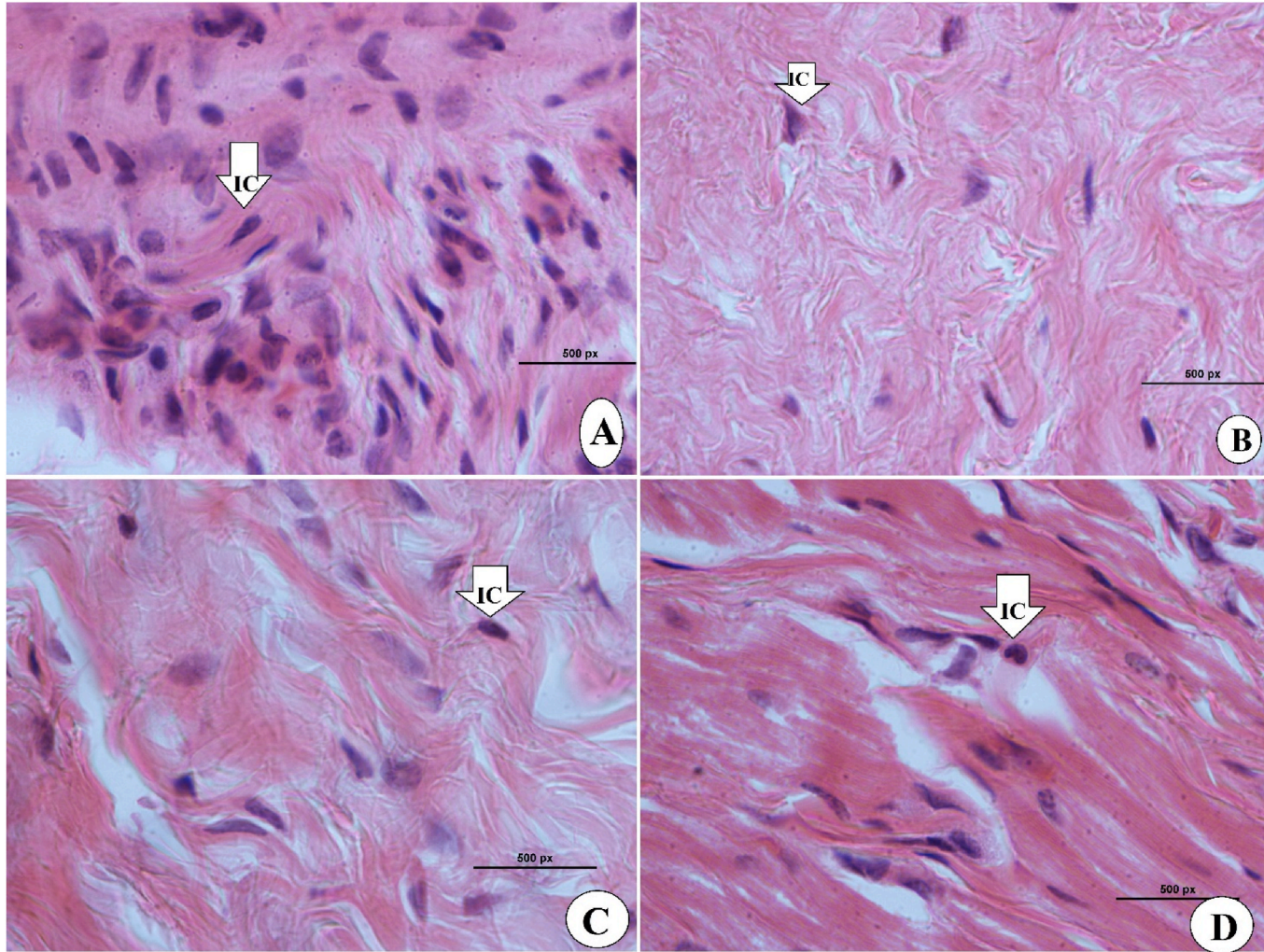


Fig. 7. High magnification of microscopic views of wounded tissue on day 15 after surgery. A, rats addressed with 0.2 ml of gum acacia (vehicle) showed more inflammatory cells and less fibroblast and collagen fibers; B, rats treated with 0.2 ml of intrasite gel revealed significant increase in the tissue granulations with higher collagen fibers and fibroblasts contents and fewer inflammatory cells; C, rats treated with 0.2 ml of 30 mg/ml of SN, moderate tissue recovery represented by increased amount of fibroblast and collagen fibers and reduced inflammatory cells; D, rats treated with 0.2 ml of 60 mg/ml of SN, showed significantly higher tissue collagen and fibroblasts and noticeably fewer inflammatory cells than that of vehicle (H&E stains, 100 \times).

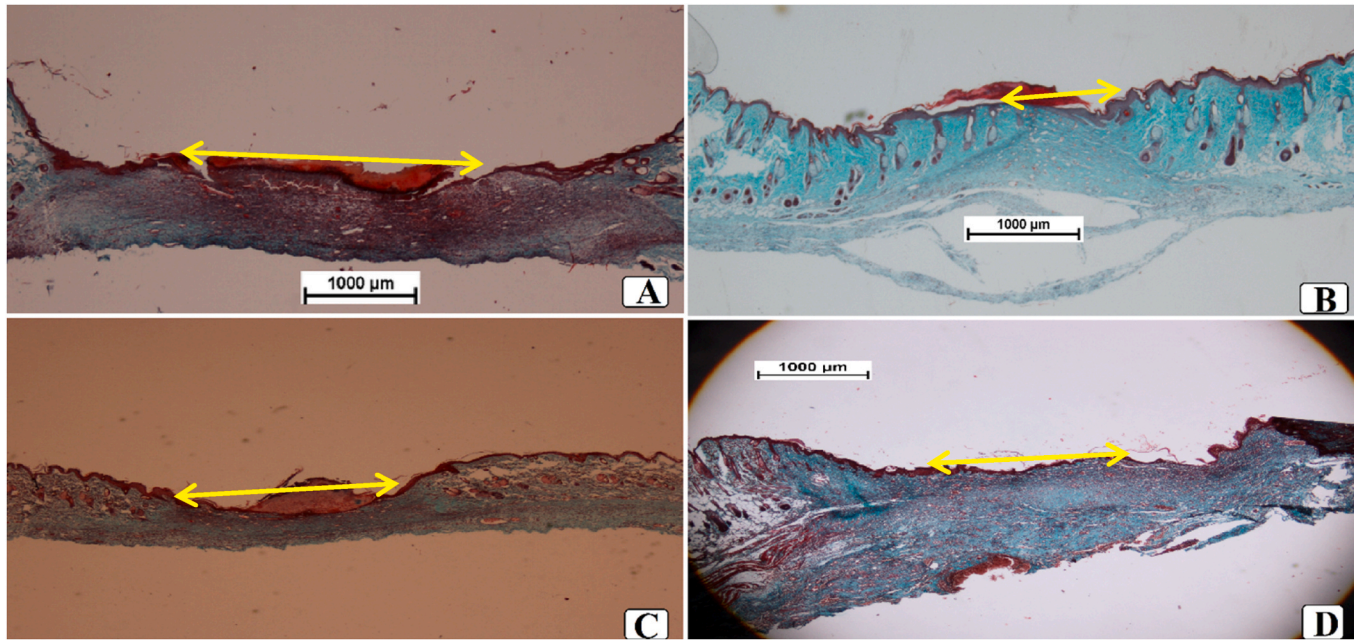


Fig. 8. Microscopic views of wound tissue colored with Masson's trichrome at day 15 after surgery in rats; A, rats treated with 0.2 mL of gum acacia (vehicle), showed wide wound closure area and reduced fibroblast and lowest collagens in their granulation tissue (GT). B, rats addressed with 0.2 mL of intrasite gel (100 mg/mL) had significantly higher wound closure and collagen deposition (deep green color) in their GT compared to all experimental rats. C, rats received topically 0.2 ml of 30 mg/ml of SN revealed smaller area wound closing and thin epidermis and significantly higher collagen deposition (moderate green color) in their GT than in the vehicle group. D, rats addressed with 0.2 ml of 60 mg/ml of SN showed higher wound closure area and more fibroblast and intense collagens (very deep green color) in their GT than in the vehicle group. E, epidermis; GT, granulation tissue, S, scab (Magnification 2 \times).

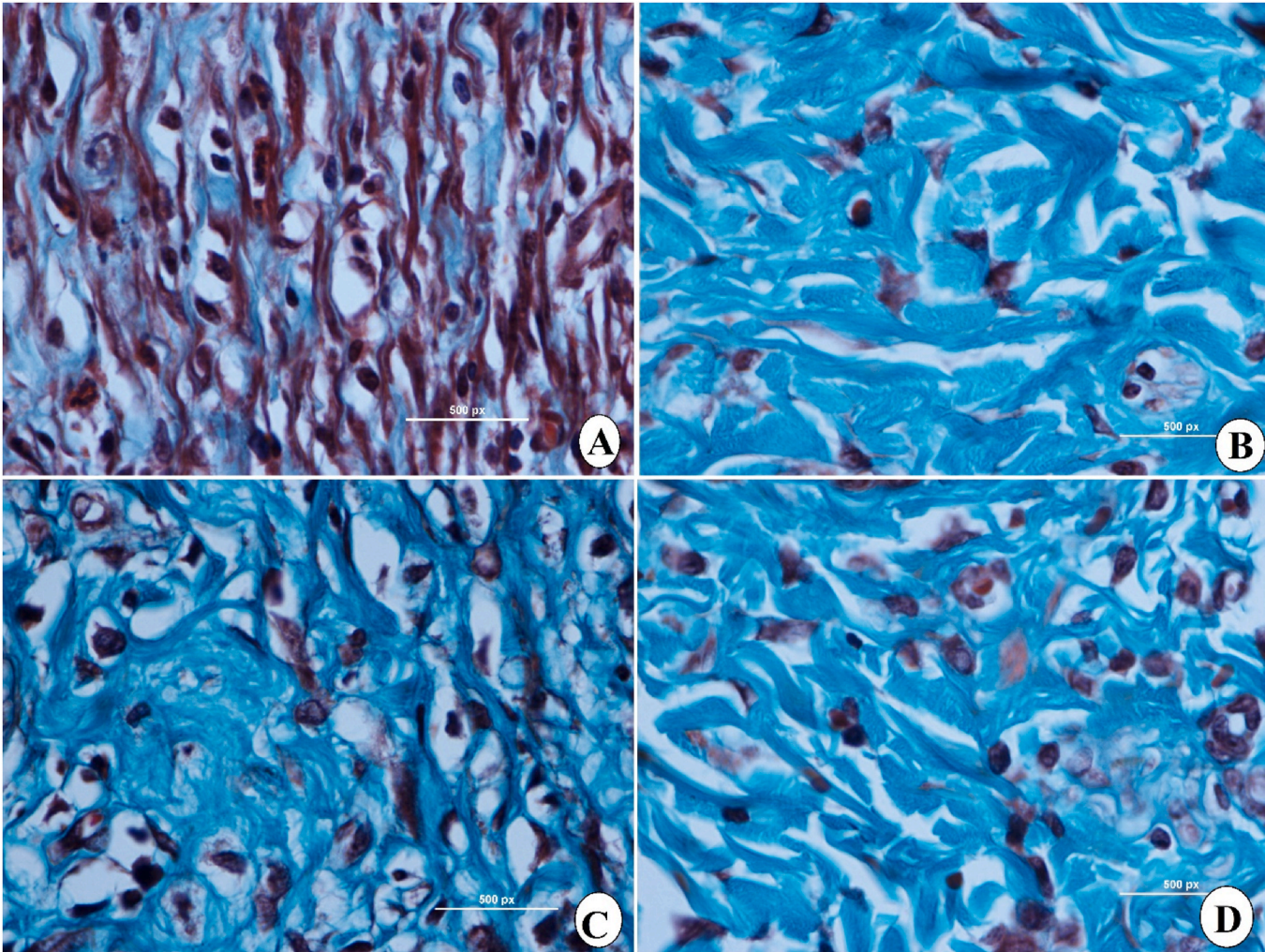


Fig. 9. Microscopic view of granulated wound tissue at high magnification by using Masson's Trichrome on day 15 after wounding in rats dressed with; A, rats addressed with 0.2 ml of gum acacia (vehicle) showed more inflammatory cells (IC) and less fibroblast and collagen fibers (CF); B, rats treated with 0.2 ml of intrasite gel revealed significant increase in the tissue granulations with higher CF and fibroblasts contents and fewer IC; C, rats treated with 0.2 ml of 30 mg/ml of SN showed moderate tissue recovery represented by increased amount of fibroblast and elevated CF and reduced IC; D, rats treated with 0.2 ml of 60 mg/ml of SN, showed significantly higher CF and fibroblasts in granulated tissues and noticeably fewer IC than that of vehicle (Magnification 100 \times).

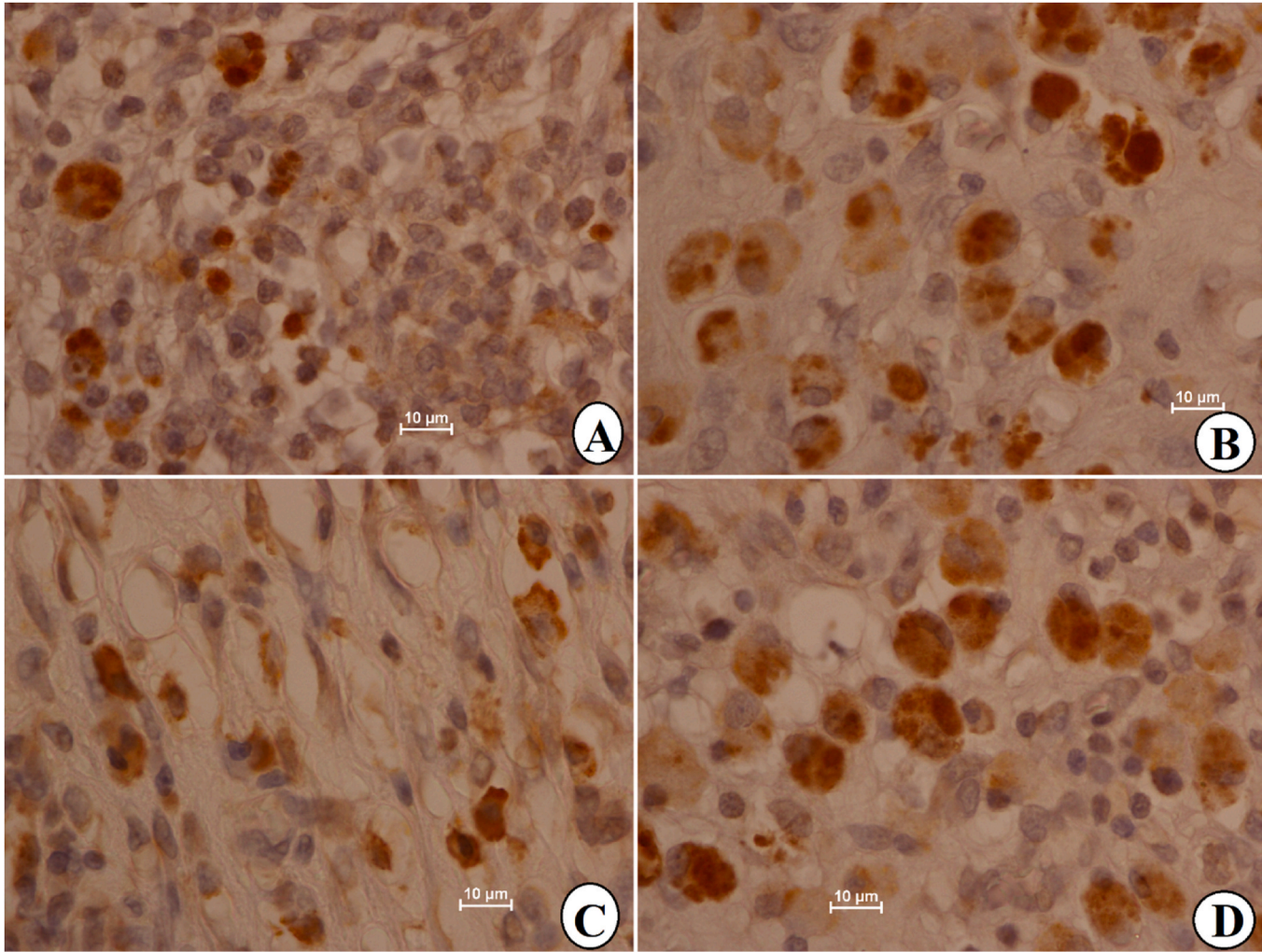


Fig. 10. Microscopic views of wound granulation tissue expressing different intensity of TGF- β 1 cytokines at day 15 after surgery in wound tissues in rats; A, Vehicle rats had 0.2 ml of Gum acacia showed decreased TGF- β 1 expression (very light brown color); B, rats received 0.2 ml of intrasite gel (reference) expressed significantly TGF- β 1 cytokines (intense brown color); C, rats received 0.2 ml of 30 mg/ml of SN revealed moderate intensity of TGF- β 1 cytokines (light brown color); D, rats treated with 0.2 ml of 60 mg/ml SN had intense brown color tissues indicating higher expression of TGF- β 1 in wound tissues compared to vehicle rats (Magnification 100 \times).

the proliferation of fibroblasts to myofibroblasts (aiding in angiogenesis and wound healing).

3.2.4. Sinomenine effects on antioxidants and MDA levels in wound tissues

The current study shows that different skin applications can modulate the activity of tissue antioxidants, which were significantly ($P < 0.05$) higher in intrasite gel or SN-treated rats compared to that of vehicle rats. Vehicle rats who addressed topically with gum acacia (vehicle) showed significantly ($P < 0.05$) reduced antioxidant enzymes (SOD and CAT), indicating increased ROS levels and severe oxidative stress. While, intrasite gel or SN treatment caused up-regulation of wound tissue antioxidants, which were statistically ($P < 0.05$) higher than in the vehicle rats. Rats receiving topically sinomenine (60 mg/ml) on their wound area had significantly higher values of SOD (8.51 U/mg) and CAT (39.30 $\mu\text{mol}/\text{min}/\text{mg}$), which were statistically ($P < 0.05$) higher than that (3.48 U/mg and 23.39 $\mu\text{mol}/\text{min}/\text{mg}$, respectively) of the vehicle group. This antiradical quenching activity of SN possibly led to less oxidative stress and more wound tissue recovery. MDA level was estimated as an indicator of lipid peroxidation, which was statistically higher ($P < 0.05$) in vehicle rats, resulting in more oxidative stress-related tissue damage that consequently delay the wound tissue recovery. While, SN-treated rats experienced decreased MDA values (2.63 nmol/mg) in their wound tissues, which was statistically lower than that 8.32, and 3.41 nmol/mg of vehicle and 30 mg/ml SN-treated rats. Moreover, the antioxidant enzymes and the MDA contents of wound tissues obtained intrasite gel (reference) and 60 mg/ml SN-treated rats were found very comparable and statistically non-significant. The outcome suggests SN as effective antioxidant agent that can reduce oxidative stress damages, thereby helping in faster wound tissue recovery in rats (Table 2).

3.2.5. Effect of sinomenine on hydroxyprolyne in wound tissues

The statistical results revealed different levels of hydroxyprolyne (the main amino acid constituting collagen) between rat groups as presented in Fig. 11. Vehicle (gum acacia) rats had the minimum value (35.70 mg/g) of hydroxyprolyne, denoting decreased collagen content in their granulation tissues. Addressed wounds with 0.2 ml of intrasite gel led to noticeable up-regulation (84.31 mg/g) of hydroxyprolyne in rats, which was conventional because of its inducing impact on cellular proliferation and collagen formation. Sinomenine (30 and 60 mg/ml)-treated rats had statistically ($P < 0.05$) higher values (49.80 and 73.20 mg/g, respectively) of hydroxyprolyne than that (35.7 mg/g) of vehicle rats. Moreover, hydroxyprolyne was statistically non-significant ($P > 0.05$) between intrasite gel or 60 mg/ml SN-treated rats. Such results denote significant ability of SN in the up-regulation of collagen fibers that consequently accelerated the wound healing process.

3.2.6. Effect of sinomenine on inflammatory cytokines

The inflammatory cytokines detected in serum samples were significantly variant between vehicle and treated rats (Fig. 12). Gum-acacia treatment caused negative modulation of inflammatory cytokines represented by elevated TNF- α (135.41 pg/ml) and IL-6 (53.85 pg/ml) cytokines and reduced decreased IL-10 (235.3 pg/ml) cytokine in rats. Contrarily, intrasite gel-treated rats had the lowest pro-inflammatory cytokines and the highest anti-inflammatory cytokines in their serum. Sinomenine treatment produced an immunomodulatory effect in wound tissues shown by statistically ($P < 0.05$) down-regulation of TNF- α (73.93 and 54.39 pg/ml for D and E group, respectively) and IL-6 (34.22 and 17.34 pg/ml for D and E group) and a significant ($P < 0.05$) up-regulation of IL-10 (389.2 and 475.4 pg/ml for D and E, respectively), which were higher than that of gum acacia-treated rats. Moreover, intrasite gel and 60 mg/ml-treated rats had close values of TNF- α and IL-10 and a non-significant difference in the IL-6 values (Fig. 12).

4. Discussion

Natural products can be a source of toxicity, morbidity, or even mortality if they are given in high amounts, which are considered as main drawbacks associated with applying them as therapeutics for human disorders. Therefore, to validate their safety usage, an acute toxicity test is a well-known technique applied to those compounds that are of medicinal interest [41,42]. Our study showed that oral ingestion of 30 and 300 mg/kg of SN did not cause any observable behavioral or physical changes in rats with zero mortality after a two-week acute toxicity trial. Moreover, serum biochemistry and histopathology of the kidney and liver were very comparable between normal control and SN-treated rats. Accordingly, oral ingestion of 175 mg/kg sinomenine hydrochloride in mice was found to be not toxic without animal death even after 14 days of the experimental period. Moreover, researchers have shown that the oral lethal dose of sinomenine hydrochloride (LD50) is 453.54–456.56 mg/kg based on iUDP (improved up and down) and mKM (modified karbar) methods [43]. Moreover, in vitro investigation reported the safety of 50 and 100 $\mu\text{g}/\text{mL}$ SN on BRL-3A cells as the compound maintained cell viability without any observable toxic effects of SN on these cells [44].

Table 2

Effect of SN on antioxidants and MDA level in homogenized skin tissues.

Animal groups	SOD (U/mg protein)	CAT ($\mu\text{mol}/\text{min}/\text{mg}$ protein)	MDA (nmol/mg protein)
A	3.48 \pm 0.35 ^c	23.39 \pm 1.60 ^c	8.32 \pm 1.24 ^c
B	9.20 \pm 0.29 ^a	46.30 \pm 1.45 ^a	2.50 \pm 0.32 ^a
C	6.35 \pm 0.11 ^b	38.50 \pm 1.38 ^b	3.41 \pm 0.34 ^b
D	8.51 \pm 0.25 ^a	39.30 \pm 2.73 ^b	2.63 \pm 0.20 ^a

Data is shown as mean \pm SEM (n = 6). Numbers shared letters within each column are non-significant at $P < 0.05$. A, Vehicle rats had topically Gum acacia; B, rats received Intrasite gel (reference); C and D, rats received topically 0.2 ml of 30 and 60 mg/ml of SN, respectively.

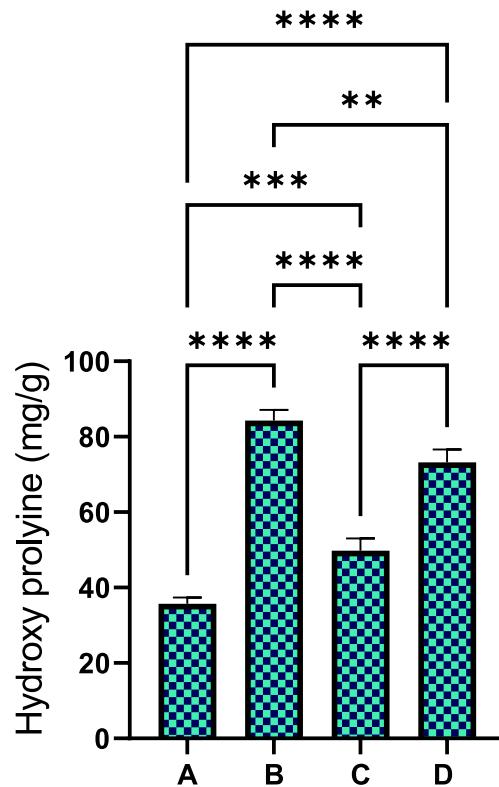


Fig. 11. Effect of sinomenine on the hydroxyprolyline in wound tissue homogenates. A, vehicle rats received topically 0.2 ml of gum acacia; B, rats addressed with 0.2 ml of intrasite gel (reference); C and D, rats received topically 0.2 ml of 30 and 60 mg/ml of SN, respectively. Values indicating statistically higher HXP contents in wound tissues obtained from intrasite gel or 0.2 ml of 60 mg/ml SN-treated compared to that of vehicle rats, which means more collagen fibers and faster wound tissue recovery.

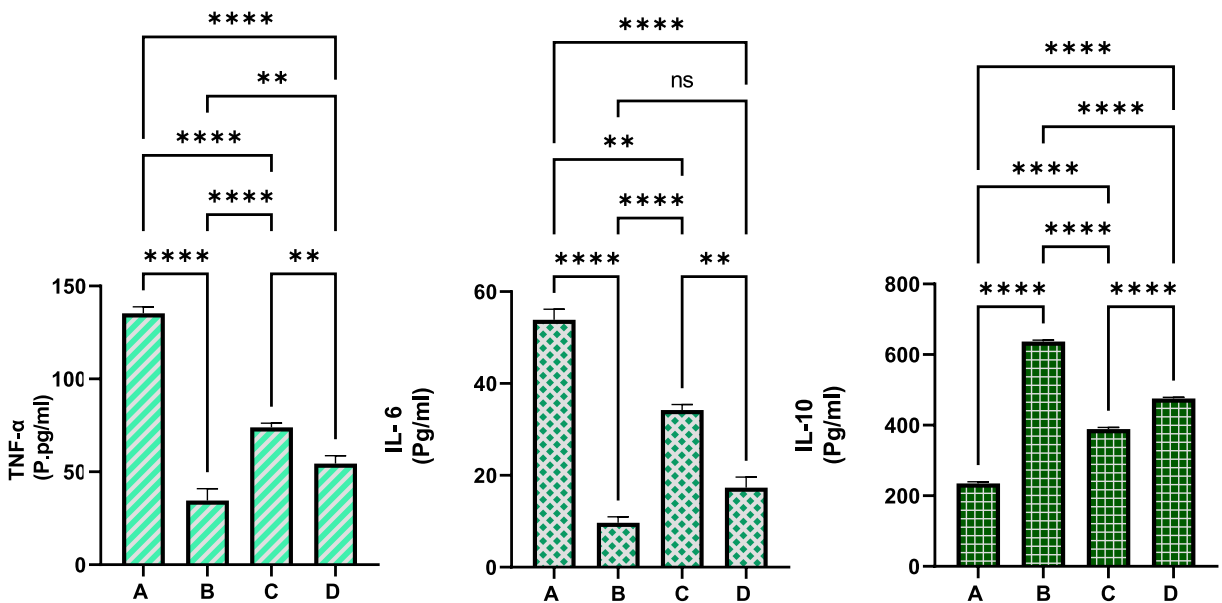


Fig. 12. Effect of SN application on serum inflammatory cytokines in rats A, Vehicle (gum acacia) rats received topically Gum acacia; B, rats received 0.2 ml of Intrasite gel (reference); C, rats received topically 30 mg/ml of SN; D, rats treated topically with 60 mg/ml of SN. Data showed significantly lower levels of pro-inflammatory cytokines and higher values of anti-inflammatory cytokines in rats received intrasite gel or 60 mg/ml of SN than that in vehicle rats, denoting lower inflammation rate and faster wound healing action.

The pharmaceutical revolution provided humans with numerous therapeutic choices for managing skin injury and wound healing, however, a novel medicine capable of accelerating the wound healing process without any drawbacks is still missing [45,46]. The current skin pharmaceuticals used for wound healing constitute only 1–3% of the medicines present in Western pharmacopeias; by comparison, the same amount of herbal medicine has been utilized for wound healing [47]. In recent decades, scientists have shown the curing potentials of numerous medicinal plants and natural products in skin injury and in accelerating wound curing process without any obvious side effects on animal models ingesting them [11,33,35,48].

In the production of chemical synthetics for promoting wound healing usually two wound techniques are applied, incisional and excisional [49]. In light of the previous studies on the wound-healing potentials of natural products, the current study applied the excisional wound procedure (full thickness) to estimate the wound-healing efficacy of SN. Rats treated topically with gum acacia had stiff wounds with dark brown scabs, recognized by huge wound area, early epithelialization, and decreased wound closure percentages on days 5, 10, and 15 after excision. Reference rats receiving intrasite gel and SN-treated rats showed smaller wound areas and higher wound closure percentages than in the vehicle rats, denoting the enhancing effect of these materials on the wound healing process. Sinomenine treatment caused the formation of clear coats around wound areas that thicken the skin epidermis near the wound area which led to less tissue damage than that of vehicle rats. The histological examination of recovered wound tissues from SN-treated rats showed a well-arranged granulation of skin tissues and bundles of newly synthesized blood vessels with statistically lower inflammatory cells compared to that of gum acacia (vehicle) rats. SN treatment caused higher tissue regeneration and collagen deposition than that of vehicle rats based on the microscopic appearance of cured wound tissues stained with H&E and Mason Trichoma. Accordingly, researchers have shown the sinomenine potential in the protection of human tissues by correlating it with different anti-inflammatory and antioxidant (Nrf2) signaling pathways in those tissues [50]. Similarly, *in vitro* study on sinomenine (25, 50, and 100 $\mu\text{mol/L}$) have shown significant wound healing and inhibitory actions on the invasion potentials of retinoblastoma cell through regulating PI3K/AKT mechanisms by utilizing the wound healing scratch and *trans*-well assays [50].

Transforming growth factor β 1 (TGF- β 1) is a well-known multifunctional cytokine that has been associated with the progression of wound healing and tissue regeneration due to its effect on the proliferation and regeneration of the extracellular matrix by regulating the mesenchymal cell growth. The molecular mechanism of TGF- β 1 has been explained by numerous researchers in recent decades [51], which can be modulated by numerous receptor-ligand bindings and intracellular pathways [52]. Moreover, scientists revealed that TGF- β 1 cytokine can have a suppressing effect on the proliferation of some cells (epithelial cells), while, in other cells, it may stimulate the proliferation actions and ECM deposition (mesenchymal cells) [53]. During skin injury and wound healing process, the production and secretion of TGF β 1 proteins are usually elevated to compensate for the inflammatory process and to enhance the wound healing process [54]. Therefore, any factors (compounds) that can regulate the mechanisms of TGF- β 1 protein can produce a significant impact on the wound healing process. By increasing the expression of these proteins near the wound bed, the cell survival and tissue regeneration rates increase around wound areas [55]. In the current study, immunohistochemically evaluation showed reduced expression of TGF- β 1 in vehicle rats as tissue sections appeared as under microscopic. While, sinomenine-treated rats had the intensity of TGF- β 1 in their recovered wound tissues, which were significantly higher than in the vehicle rats, but very comparable to that of intrasite gel-addressed rats. These outcomes indicate clear regulator potentials of SN on the immunohistochemical proteins (TGF- β 1) associated with wound healing acceleration. Accordingly, Researchers have shown significant potentials of SN in the positive augmentation of immunohistochemically (increasing Bax and decreasing Bcl-2) proteins, regulatory of oxidative stress and inflammation, which were considered as molecular mechanisms behind SN efficacy in the inhibition of growth and migration of retinoblastoma cells in an *in vitro* experiment [56]. Similarly, *in vitro* and *in vivo* studies have correlated the ameliorative effect of sinomenine on cardiac hypertrophy with its positive regulation of immunohistochemically (Bax/Bcl-2) proteins [27,57].

The wound healing occurred alongside skin ischemia, which enhances the formation of reactive oxygen species by stimulating the leukocyte proliferation near the wound side. As the process continues, the accumulation of free radicals in the wound tissues activates a cascade of inflammatory responses, including inflammatory cytokine release, leukocyte infiltration (chemotaxis), and oxidative stress in those tissues. As a defense mechanism, our body generates antioxidant enzymes to eliminate those free radicals before causing further tissue damage. However, in certain disease and non-disease cases, these endogenous antioxidants (CAT, SOD, and GPx) cannot keep up with the enormous amount of produced reactive oxygen species, which will cause more structure and functional damage around wound areas. Cells produce a range of endogenous antioxidants that play a major part in the antioxidant defense mechanism of cells that can quench free radicals and avoid oxidative stress-related damages [58]. The SOD enzyme is a well-known metalloenzyme that can reduce free radicals and oxidative damage by the dismutation of O $_2$ - to H $_2$ O $_2$ and O $_2$. The catalase (CAT) enzyme is another cellular antioxidant enzyme that lowers oxidative stress by converting H $_2$ O $_2$ to H $_2$ O and oxygen. Accumulation of H $_2$ O $_2$ molecules inside the cell can generate a Fenton reaction, which leads to the production of more reactive oxygen and higher oxidative stress-related cellular damage. In the present work, SN treatment caused augmentation of antioxidant enzymes, which were shown by higher SOD and CAT contents in wound tissue homogenates, thereby resulting in faster wound healing process and higher wound closure percentages. Similarly, investigators have shown significant antioxidant potential of SN, which was considered one of the protective mechanisms of SN against alcohol-liver injury in rats [59]. Moreover, scientists have associated the regulatory potentials of SN (100 mg/kg) on antioxidant enzymes and antioxidant mechanisms (Nrf2-Keap1) with its ameliorative effect on septic-associated lung injury in mice [60].

Free radical accumulation can initiate a destructive process of unsaturated fatty acid breakdown called lipid peroxidation. Free radicals can interact with hydrogen atoms in the lipid bilayer of the cell membrane, creating lipid radicals and a cascade of oxygen-induced chain reaction that makes the membrane filled with lipid hydroperoxides (intermediates of lipid peroxidation). The final peroxide molecule severely damages membrane functionality, altering permeability, increasing rigidity, ion leakage (calcium), fibroblast accumulation, and keratinocyte accessibilities. Moreover, the increased lipid peroxidation in tissues around the wound area

can suppress the activation of vascular endothelial growth factor, thereby halting the wound-curing process. As an indicator of lipid peroxidation and oxidative stress, MDA is considered a highly reactive compound resulting from the oxidation of polyunsaturated fatty acids. In the present study, vehicle rats had significant oxidative stress and lipid peroxidation rates represented by elevated MDA levels in their recovered wound tissues. Contrarily, rats addressed with SN (30 and 60 mg/ml) had significantly lower MDA values, indicating antioxidant potentials of this alkaloid against oxidative stress, which positively affected the time taken for wound closure in those groups. and thus faster wound-healing actions. Similarly, numerous studies have shown the inhibitory potentials of SN in different animal models exposed to different oxidative stress conditions [27,57,61].

Collagen protein is considered a valuable molecule to finalize the last two stages of wound healing and closure. 4-Hydroxyproline (HXP) has been known as a major constituent of collagen, comprising nearly 13.5 % of its amino acid composition that maintains its integrity and structural stability. Therefore, the estimation of HXP content in wound tissues can be a good indicator of the amount of collagen produced in those tissues. In other words, higher HXP levels in wound areas will result in a faster wound-healing process and wound closure. The present data showed that gum acacia-treated rats had the lowest HXP content in their recovered wound tissues. On the other side, SN-treated rats showed significantly increased HXP levels in their cured wound tissue, indicating higher collagen content that might be correlated with its higher wound closure percentages. Our results were following previous results, which showed SN efficacy in positive regulation of subepithelial collagen deposition, and other tissue proteins that helped in relieving Airway remodeling in mice with asthma [62]. Similar effects of SN on the positive regulation of hydroxyproline and collagen proteins have been found in a nanofiber study for wound healing [63].

The pro-inflammatory cytokines (NF- κ B, IL-1 β , IL-6, and TNF- α) are known to participate in the early stages of wound curing process (inflammatory phase). Adequate production of pro-inflammatory cytokines is necessary to recruit immune cells (neutrophils) and eliminate bacteria and pathogens from the wound area [64]. Besides that, pro-inflammatory cytokines stimulate the production of metalloproteinase (MP) enzymes in inflammatory and fibroblast cells. During wound tissue recovery, MP can degrade and eliminate injured extracellular matrixes to compensate for wound restoration. However, excessive production of pro-inflammatory cytokines and prolonged inflammatory phase will halt the wound healing process resulting in a delay of wound closure. Because these cytokines and proteinase enzymes will degrade wound tissues leading to the initiation of chronic wounds. On the other hand, Interleukin 10 is an anti-inflammatory mediator that has inhibitory action on the inflammation and autoimmune process. Increased production of IL-10 can suppress cellular response to pathogens and avoid hemodynamic disturbance, and further wound tissue damage. Our study has shown significant immunomodulatory actions of sinomenine on excision wounds in rats represented by decreased TNF- α , IL-6, and increased IL-10 cytokines in serum samples, which could be one of the mechanisms that lead to lower wound area and higher wound closure percentages in those rats. Accordingly, numerous studies have shown the anti-inflammatory potentials of SN in different rat trials, represented by down-regulation of TNF- α , IL-6, and IL-1 β and up-regulation of IL-10 cytokines [25,65–67].

The present finding strongly validates the therapeutic potentials of SN on wound healing, possibly through its positive augmentation on the antioxidant, immunohistochemical, and hydroxyproline contents of wound tissues.

5. Conclusion

The wound healing effects of sinomenine, on dorsal neck skin injuries in rats were evaluated. The acute toxicity evaluation of SN showed a lack of any physiological abnormalities or death in rats, even after ingestion of 300 mg/kg of SN for two weeks. SN treatment enhanced wound healing actions, resulting in higher wound closure percentages, which could be correlated with its positive modulation of the immunohistochemical protein (TGF-1), tissue antioxidants, and inflammatory cytokines. The present research had many obstacles, including a shortage of animal houses, poor laboratory facilities, and a low budget. Therefore, further investigations are recommended on larger scales to determine the exact molecular mechanism responsible for the wound curing potentials of SN.

Data availability statement

Data associated with the study has not been deposited into a publicly available repository. Data will be made available on request.

Ethic approval for the animal experiment

The present animal study protocol agreed by the ethical board in Medical Microbiology dep., Cihan University-Erbil [ethic. No. form: 295; 22-11-2022]. Animal handling was according to guidelines set by Iraqi animal rights and National scientific recommendations for laboratory animal experiments [68].

CRedit authorship contribution statement

Ahmed A.j. Jabbar: Writing - original draft, Software, Investigation, Data curation, Conceptualization. **Khaled Abdul-Aziz Ahmed:** Writing - review & editing, Resources. **Mahmood Ameen Abdulla:** Investigation, Conceptualization. **Fuad Othman Abdullah:** Software, Formal analysis. **Nur Ain Salehen:** Validation, Resources. **Ramzi A. Mothana:** Writing - review & editing, Software, Formal analysis. **Jamal Houssaini:** Validation, Resources, Formal analysis. **Rawaz Rizgar Hassan:** Validation, Software, Resources. **Mohammed F. Hawwal:** Validation, Software, Resources. **Omer I. Fantoukh:** Software, Formal analysis. **Sidgi Hasson:** Validation, Resources, Formal analysis.

Declaration of competing interest

The authors declare that they have no known competing financial interests or personal relationships that could have appeared to influence the work reported in this paper.

Acknowledgement

The authors extend their appreciation to Researchers Supporting Project number (RSP2023R119), King Saud University, Riyadh, Saudi Arabia for funding this work.

References

- [1] Z. Xu, S. Han, Z. Gu, J. Wu, Advances and impact of antioxidant hydrogel in chronic wound healing, *Adv. Healthcare Mater.* 9 (2020), 1901502.
- [2] R. Dong, B. Guo, Smart wound dressings for wound healing, *Nano Today* 41 (2021), 101290.
- [3] A. Amirsadeghi, A. Jafari, S.S. Hashemi, A. Kazemi, Y. Ghasemi, A. Derakhshanfar, M.A. Shahbazi, S.V. Niknezhad, Sprayable antibacterial Persian gum-silver nanoparticle dressing for wound healing acceleration, *Mater. Today Commun.* 27 (2021), <https://doi.org/10.1016/j.mtcomm.2021.102225>.
- [4] J.F. Guest, G.W. Fuller, P. Vowden, Cohort study evaluating the burden of wounds to the UK's National Health Service in 2017/2018: update from 2012/2013, *BMJ Open* 10 (2020), e045253, <https://doi.org/10.1136/bmjopen-2020-045253>.
- [5] S.K. Dubey, S. Parab, A. Alexander, M. Agrawal, V.P.K. Achalla, U.N. Pal, M.M. Pandey, P. Kesharwani, Cold atmospheric plasma therapy in wound healing, *Process Biochem.* 112 (2022) 112–123.
- [6] S. Osman Mahmud, S. Hamad Shareef, A.A.J. Jabbar, R.R. Hassan, H.K. Jalal, M.A. Abdulla, Green synthesis of silver nanoparticles from aqueous extract of *tinospora crispa* stems accelerate wound healing in rats, *Int. J. Low. Extrem. Wounds* (2022), 15347346221133628, <https://doi.org/10.1177/15347346221133627>.
- [7] A.K. Shakya, Medicinal plants: future source of new drugs, *Int J Herb Med* 4 (2016) 59–64.
- [8] A.A. Jabbar, F.O. Abdullah, A.O. Hassan, Y. Galali, R.R. Hassan, E.Q. Rashid, M.I. Salih, K.F. Aziz, Ethnobotanical, phytochemistry, and pharmacological activity of *onosma* (boraginaceae): an updated review, *Molecules* 27 (2022) 8687.
- [9] Y. Haririan, A. Asefnejad, H. Hamishehkar, M.R. Farahpour, Carboxymethyl chitosan-gelatin-mesoporous silica nanoparticles containing *Myrtus communis* L. extract as a novel transparent film wound dressing, *Int. J. Biol. Macromol.* 253 (2023), 127081, <https://doi.org/10.1016/j.jbiomac.2023.127081>.
- [10] V.M. Mayekar, A. Ali, H. Alim, N. Patel, A review: antimicrobial activity of the medicinal spice plants to cure human disease, *Plant Sci Today* 8 (2021) 629–646.
- [11] E. Bagheri, K. Saremi, F. Hajiaghaalipour, F.L. Faraj, H.M. Ali, M.A. Abdulla, S.L. Khaing, N. Salehen, Synthesis of novel derivatives of quinazoline schiff base compound promotes epithelial wound healing, *Curr. Pharmaceut. Des.* 24 (2018), <https://doi.org/10.2174/1381612824666180130124308>.
- [12] A.A.J. Jabbar, Z.Z. Alamri, M.A. Abdulla, N.A. Salehen, Z. Salim Amur Al Sinawi, S.M. Alfaihi, Hepatoprotective effects of *Gynura procumbens* against thioacetamide-induced cirrhosis in rats: targeting inflammatory and oxidative stress signalling pathways, *Heliyon* 9 (2023), e19418, <https://doi.org/10.1016/j.heliyon.2023.e19418>.
- [13] M. Ajjoun, L. Kharchoufa, I.A. Merrouni, M. Elachouri, Moroccan medicinal plants traditionally used for the treatment of skin diseases: from ethnobotany to clinical trials, *J. Ethnopharmacol.* (2022), 115532.
- [14] A.A.J. Jabbar, Z.Z. Alamri, M.A. Abdulla, A.S. AlRashdi, S.K. Najmaldin, M.A. Zainel, Sinapic acid attenuate liver injury by modulating antioxidant activity and inflammatory cytokines in thioacetamide-induced liver cirrhosis in rats, *Biomedicines* 11 (2023) 1447, <https://doi.org/10.3390/biomedicines11051447>.
- [15] S. Jarić, O. Kostić, Z. Mataruga, D. Pavlović, M. Pavlović, M. Mitrović, P. Pavlović, Traditional wound-healing plants used in the Balkan region (Southeast Europe), *J. Ethnopharmacol.* 211 (2018) 311–328.
- [16] H. Yamasaki, Pharmacology of sinomenine, an anti-rheumatic alkaloid from *Sinomenium acutum*, *Acta Med. Okayama* 30 (1976).
- [17] S. Wang, L. Zhang, Y. Zhou, J. Huang, Z. Zhou, Z. Liu, A review on pharmacokinetics of sinomenine and its anti-inflammatory and immunomodulatory effects, *Int. Immunopharm.* 119 (2023), 110227.
- [18] H. Song, J. Wen, H. Li, Y. Meng, Y. Zhang, N. Zhang, W. Zheng, Enhanced transdermal permeability and drug deposition of rheumatoid arthritis via sinomenine hydrochloride-loaded antioxidant surface transthesosome, *Int. J. Nanomed.* (2019) 3177–3188.
- [19] S. Liu, Q. Chen, J. Liu, X. Yang, Y. Zhang, F. Huang, Sinomenine protects against *E. coli*-induced acute lung injury in mice through Nrf2-NF- κ B pathway, *Biomed. Pharmacother.* 107 (2018) 696–702.
- [20] R.-L. Zhu, Y.-K. Zhi, L. Yi, J.-F. Luo, J. Li, S.-S. Bai, L. Liu, P.-X. Wang, H. Zhou, Y. Dong, Sinomenine regulates CD14/TLR4, JAK2/STAT3 pathway and calcium signal via α nAChR to inhibit inflammation in LPS-stimulated macrophages, *Immunopharmacol. Immunotoxicol.* 41 (2019) 172–177.
- [21] S.-P. Chen, J. Sun, Y.-Q. Zhou, F. Cao, C. Braun, F. Luo, D.-W. Ye, Y.-K. Tian, Sinomenine attenuates cancer-induced bone pain via suppressing microglial JAK2/STAT3 and neuronal CAMKII/CREB cascades in rat models, *Mol. Pain* 14 (2018), 1744806918793232.
- [22] F.H. Shah, K.H. Lim, S.J. Kim, Bioinformatic analysis of antiviral medicinal compounds against Sars Cov-2 proteases, *Kuwait J. Sci. Special Issue on COVID* (2021) 1–12.
- [23] M. Zhu, H. Wang, J. Chen, H. Zhu, Sinomenine improve diabetic nephropathy by inhibiting fibrosis and regulating the JAK2/STAT3/SOCS1 pathway in streptozotocin-induced diabetic rats, *Life Sci.* 265 (2021), 118855.
- [24] P. Lee, W. Chen, I. Liu, J. Cheng, Vasodilatation induced by sinomenine lowers blood pressure in spontaneously hypertensive rats, *Clin. Exp. Pharmacol. Physiol.* 34 (2007) 979–984.
- [25] W. Jiang, W. Fan, T. Gao, T. Li, Z. Yin, H. Guo, L. Wang, Y. Han, J.-D. Jiang, Analgesic mechanism of sinomenine against chronic pain, *Pain Res. Manag.* (2020) 2020.
- [26] M.-W. Zhang, X.-H. Wang, J. Shi, J.-G. Yu, Sinomenine in cardio-cerebrovascular diseases: potential therapeutic effects and pharmacological evidences, *Front Cardiovasc Med* 8 (2021), 749113.
- [27] M. Yuan, B. Zhao, H. Jia, C. Zhang, X. Zuo, Sinomenine ameliorates cardiac hypertrophy by activating Nrf2/ARE signaling pathway, *Bioengineered* 12 (2021) 12778–12788.
- [28] S. Yang, F. Ning, J. Li, D. Guo, L. Zhang, R. Cui, Y. Liu, Therapeutic effect analysis of Sinomenine on rat cerebral ischemia-Reperfusion injury, *J. Stroke Cerebrovasc. Dis.* 25 (2016) 1263–1269.
- [29] R.A. Patil, K.H. Pardeshi, H.P. Chavan, S. V Amrutkar, Pharmacotherapeutics and Pharmacokinetics of Herbal Bioenhancers, *Drug Deliv Technol Herb Bioenhancers Pharm.*, 2022, p. 149.
- [30] O. Guideline, Acute Oral Toxicity-Acute Toxic Class Method. OECD Guidelines for the Testing of Chemicals, OECD Publishing, Paris, 2001, 423.
- [31] A.A. Mariod, A.A.J. Jabbar, Z.Z. Alamri, A.S. Al Rashdi, M.A. Abdulla, Gastroprotective effects of *Polygonatum odoratum* in rodents by regulation of apoptotic proteins and inflammatory cytokines, *Saudi J. Biol. Sci.* 30 (2023), 103678.
- [32] F.M. Fathi, H. Harita, A.A. Mahmood, S.M. Suzy, I. Salmah, A.A. Zahra, K. Kamal, Acceleration of wound healing activity by *Polygonatum odoratum* leaf extract in rats, *J. Med. Plants Res.* 8 (2014) 523–528.
- [33] S. Osman, Z. Amin, The effect of vitamin K on the wound healing process in rat skin achieved by common wound dressing agents, *Zanco J Med Sci* 24 (2020), <https://doi.org/10.15218/zjms.2020.014>.
- [34] M. Rahnama, N.S. Gwaram, I. Abdel, A. Ibrahim, N. Shahzad, S.S. Al-ghamdi, N. Ayoub, Wound curing prospective of copper (II) bis [(5-Chloro-1H-Indol-3-yl)methylene nicotinohydrazide] on experimentation provoke cutting out injury in rats, *Int. J. Drug Dev. Res.* 10 (2018) 1–9.

- [35] W.N. Abood, N.A. Al-Henhena, A.N. Abood, M.M. Jamil Al-Obaidi, S. Ismail, M.A. Abdulla, R. Al Batran, Wound-healing potential of the fruit extract of phaleria macrocarpa, *Bosn. J. Basic Med. Sci.* 15 (2015), <https://doi.org/10.17305/bjbm.2015.39>.
- [36] F.F. Mughrabi, H.M. Ali, H. Khaledi, M. Ameen, H. Hashim, Acceleration of wound healing potential of Benzyl N'-(Indol-3-Ylinethylidene)-Hydrazinecarbodithioate derivatives in experimental rats, *Res. J. Appl. Sci.* 5 (2010) 131–136.
- [37] B.A.W. Ali, N.A. Salehen, M.A. Abdulla, A.A. Jabbar, I. Ibrahim, A. Abdel, G. Almainani, M. AbdulMonam Z, G.A. Bamagous, R.A. Almainani, H.A. Almasmoum, Pinostrobin attenuates azoxymethane-induced colorectal cytotoxicity in rats through augmentation of apoptotic Bax/Bcl-2 proteins and antioxidants, *SAGE Open Med.* 11 (2023), 20503121231216584.
- [38] M.R. Mustafa, A.A. Mahmood, I. Salmah, Effects of *Trigonella foenum-graecum* seed extract in combination with honey on experimental wound healing in rats, *Int. J. Mol. Med. Adv. Sci.* 1 (2005) 29–33.
- [39] R.R. Hama Amin, T.A. Aziz, Gastroprotective effect of azilsartan through ameliorating oxidative stress, inflammation, and restoring hydroxyproline, and gastrin levels in ethanol-induced gastric ulcer, *J. Inflamm. Res.* 15 (2022) 2911–2923, <https://doi.org/10.2147/JIR.S365090>.
- [40] S.H. Shareef, M.H. Al-Medhtui, I.A. Ibrahim, A.R. Alzahrani, A.A. Jabbar, Y. Galali, N.F. Agha, P.Y. Aziz, M.A. Thabit, D.N.F. Agha, N.A. Salehen, Z.M. Ameen, M.A. Abdulla, Gastroprophylactic effects of p-cymene in ethanol-induced gastric ulcer in rats, *Process* 10 (2022), <https://doi.org/10.3390/pr10071314>.
- [41] A.A. Jabbar, F.O. Abdullah, K. Abdoulrahman, Y. Galali, I.A. Ibrahim, A.R. Alzahrani, R.R. Hassan, Gastroprotective, biochemical, and acute toxicity effects of papaver decasnei against ethanol-induced gastric ulcers in rats, *Processes* 10 (2022) (1985), <https://doi.org/10.3390/pr10101985>.
- [42] B.A.A. Wahab, Z.Z. Alamri, A.A.J. Jabbar, I.A.A. Ibrahim, R.A. Almainani, H.A. Almasmoum, M.M. Ghaith, W.F. Farrash, Y.A. Almutawif, K.A. Ageeli, S. M. Alfafifi, R.F. Alharthi, Phytochemistry, antioxidant, anticancer, and acute toxicity of traditional medicinal food *Biarum bovei* (Kardec), *BMC Complement Med Ther* 23 (2023) 283, <https://doi.org/10.1186/s12906-023-04080-y>.
- [43] Y.-Y. Zhang, Y.-F. Huang, J. Liang, H. Zhou, Improved up-and-down procedure for acute toxicity measurement with reliable LD50 verified by typical toxic alkaloids and modified Karber method, *BMC Pharmacol Toxicol* 23 (2022) 3, <https://doi.org/10.1186/s40360-021-00541-7>.
- [44] H. Chen, Y. Wang, F.-Z. Jiao, F. Yang, X. Li, L.-W. Wang, Sinomenine attenuates acetaminophen-induced acute liver injury by decreasing oxidative stress and inflammatory response via regulating TGF- β /Smad pathway in vitro and in vivo, *Drug Des. Dev. Ther.* (2020) 2393–2403.
- [45] A. Ebrahimi, M. Reza Farahpour, S. Amjadi, M. Mohammadi, H. Hamishehkar, Nanoliposomal peptides derived from *Spirulina platensis* protein accelerate full-thickness wound healing, *Int. J. Pharm.* 630 (2023), 122457, <https://doi.org/10.1016/j.ijpharm.2022.122457>.
- [46] L.F.S. Gushiken, F.P. Beserra, J.K. Bastos, C.J. Jackson, C.H. Pellizzon, Cutaneous wound healing: an update from physiopathology to current therapies, *Life* 11 (2021) 665.
- [47] U. Anand, C.K. Tudu, S. Nandy, K. Sunita, V. Tripathi, G.J. Loake, A. Dey, J. Proćkó, Ethnodermatological use of medicinal plants in India: from ayurvedic formulations to clinical perspectives—A review, *J. Ethnopharmacol.* 284 (2022), 114744.
- [48] Z.A. Amin, H.M. Ali, M.A. Alshawsh, P.H. Darvish, M.A. Abdulla, Application of *Antrodia camphorata* promotes rat's wound healing in vivo and facilitates fibroblast cell proliferation in vitro, *Evidence-Based Complement Altern Med* 2015 (2015), 317693, <https://doi.org/10.1155/2015/317693>.
- [49] B. Nagoba, M. Davane, Studies on wound healing potential of topical herbal formulations—do we need to strengthen study protocol? *J. Ayurveda Integr. Med.* 10 (2019) 316–318.
- [50] F. Bi, Y. Zhang, W. Liu, K. Xie, Sinomenine activation of Nrf2 signaling prevents inflammation and cerebral injury in a mouse model of ischemic stroke, *Exp. Ther. Med.* 21 (2021) 1–9.
- [51] M. Lodyga, B. Hinz, TGF- β 1—a truly transforming growth factor in fibrosis and immunity, in: *Semin Cell Dev Biol*, Elsevier, 2020, pp. 123–139.
- [52] J.A. Turner, E. Stephen-Victor, S. Wang, M.N. Rivas, A. Abdel-Gadir, H. Harb, Y. Cui, M. Fanny, L.-M. Charbonnier, J.J.H. Fong, Regulatory T cell-derived TGF- β 1 controls multiple checkpoints governing allergy and autoimmunity, *Immunity* 53 (2020) 1202–1214.
- [53] S.M. Zhu, Y.R. Park, S.Y. Seo, L.H. Kim, S.T. Lee, S.W. Kim, Parthenolide inhibits transforming growth factor β 1-induced epithelial-mesenchymal transition in colorectal cancer cells, *Int. Res.* 17 (2019) 527–536.
- [54] B.G. Eid, N.A. Alhakamy, U.A. Fahmy, O.A.A. Ahmed, S. Md, A.B. Abdel-Naim, G. Caruso, F. Caraci, Melittin and diclofenac synergistically promote wound healing in a pathway involving TGF- β 1, *Pharmacol. Res.* 175 (2022), 105993.
- [55] Q. Zhang, W. Ye, Y. Liu, D. Niu, X. Zhao, G. Li, Y. Qu, Z. Zhao, S-allylmercapto-N-acetylcysteine ameliorates pulmonary fibrosis in mice via Nrf2 pathway activation and NF- κ B, TGF- β 1/Smad2/3 pathway suppression, *Biomed. Pharmacother.* 157 (2023), 114018.
- [56] Q. Zheng, Q. Zhu, C. Li, S. Hao, J. Li, X. Yu, D. Qi, Y. Pan, Sinomenine can inhibit the growth and invasion ability of retinoblastoma cell through regulating PI3K/AKT signaling pathway, *Biol. Pharm. Bull.* 43 (2020) 1551–1555.
- [57] Y. Li, W. Cai, Z. Ai, C. Xue, R. Cao, N. Dong, Protective effects of sinomenine hydrochloride on lead-induced oxidative stress, inflammation, and apoptosis in mouse liver, *Environ. Sci. Pollut. Res.* 30 (2023) 7510–7521.
- [58] A.A. Jabbar, I.A.A. Ibrahim, F.O. Abdullah, K.F. Aziz, A.R. Alzahrani, M.A. Abdulla, Chemopreventive effects of *onosma mutabilis* against azoxymethane-induced colon cancer in rats via amendment of bax/bcl-2 and NF- κ B signaling pathways, *Curr. Issues Mol. Biol.* 45 (2023) 885–902.
- [59] H. Fan, T. Tu, X. Zhang, Q. Yang, G. Liu, T. Zhang, Y. Bao, Y. Lu, Z. Dong, J. Dong, Sinomenine attenuates alcohol-induced acute liver injury via inhibiting oxidative stress, inflammation and apoptosis in mice, *Food Chem. Toxicol.* 159 (2022), 112759.
- [60] W. Wang, X. Yang, Q. Chen, M. Guo, S. Liu, J. Liu, J. Wang, F. Huang, Sinomenine attenuates septic-associated lung injury through the Nrf2-Keap1 and autophagy, *J. Pharm. Pharmacol.* 72 (2020) 259–270.
- [61] S. Ramazi, J. Fahanik-Babaei, S.-M. Mohamadi-Zarch, M. Tashakori-Miyanroudi, D. Nourabadi, M. Nazari-Serenjeh, M. Roghani, T. Baluchnejadmojarad, Neuroprotective and anticonvulsant effects of sinomenine in kainate rat model of temporal lobe epilepsy: involvement of oxidative stress, inflammation and pyroptosis, *J. Chem. Neuroanat.* 108 (2020), 101800.
- [62] H. He, L. Cao, Z. Wang, Z. Wang, J. Miao, X.-M. Li, M. Miao, Sinomenine relieves Airway remodeling by inhibiting epithelial-mesenchymal transition through downregulating TGF- β 1 and Smad3 expression in vitro and in vivo, *Front. Immunol.* 12 (2021), 736479.
- [63] S. Selvaraj, C. Inbasekar, S. Pandurangan, N.F. Nishter, Collagen-coated silk fibroin nanofibers with antioxidants for enhanced wound healing, *J. Biomater. Sci. Polym. Ed.* 34 (2023) 35–52.
- [64] S.M. Salama, N.S. Gwaram, A.S. AlRashdi, S.A.M. Khalifa, M.A. Abdulla, H.M. Ali, H.R. El-Seedi, A zinc morpholine complex prevents HCl/Ethanol-Induced gastric ulcers in a rat model, *Sci. Rep.* 6 (2016), <https://doi.org/10.1038/srep29646>.
- [65] Y. Li, H. Xie, H. Zhang, Protective effect of sinomenine against inflammation and oxidative stress in gestational diabetes mellitus in female rats via TLR4/MyD88/NF- κ B signaling pathway, *J. Food Biochem.* 45 (2021), e13952.
- [66] R. Sharma, S.P. Kambhampati, Z. Zhang, A. Sharma, S. Chen, E.I. Duh, S. Kannan, M.O.M. Tso, R.M. Kannan, Dendrimer mediated targeted delivery of sinomenine for the treatment of acute neuroinflammation in traumatic brain injury, *J. Contr. Release* 323 (2020) 361–375.
- [67] J. Qiu, M. Wang, J. Zhang, Q. Cai, D. Lu, Y. Li, Y. Dong, T. Zhao, H. Chen, The neuroprotection of Sinomenine against ischemic stroke in mice by suppressing NLRP3 inflammasome via AMPK signaling, *Int. Immunopharm.* 40 (2016) 492–500, <https://doi.org/10.1016/j.intimp.2016.09.024>.
- [68] J. Garber, R. Barbee, J. Bielitzki, L. Clayton, J. Donovan, *Guide for the Care and Use of Laboratory Animals*, Washington (DC), 2011, <https://doi.org/10.17226/12910>.