

ORIGINAL ARTICLE OPEN ACCESS

Double Teeth and Coexistent Anomalies: Examples From Continental Africa

Joel D. Irish 

Research Centre in Evolutionary Anthropology and Palaeoecology, School of Biological and Environmental Sciences, Liverpool John Moores University, Liverpool, UK

Correspondence: Joel D. Irish (j.d.irish@ljmu.ac.uk)

Received: 5 July 2024 | **Revised:** 17 August 2024 | **Accepted:** 19 August 2024

Funding: This work was supported by Graduate College, Arizona State University, American Museum of Natural History, Friends of Nekhen, Institute of Archaeology and Ethnology-Polish Academy of Sciences, National Science Foundation (BNS-9013942, BNS-0104731, BCS-0840674, BCS-0119754), Institute for Bioarchaeology, National Science Centre (2017/25/B/HS3/03928).

Keywords: dens evaginatus | double teeth | fusion | gemination | talon cusp

ABSTRACT

Objectives: Whether gemination or fusion, double teeth are rare worldwide, including Africa based on few published data. New cases from the continent are tallied, and anomalies potentially associated with double teeth are identified. These findings should interest a range of dental researchers.

Methods: The presence of double teeth was recorded in 97 modern and premodern North and sub-Saharan African samples (5631 inds.). They and coexistent anomalies are described relative to published examples. Prevalence was estimated as possible, using a Poisson model for 95% confidence intervals (CI).

Results: Three maxillary double teeth were identified: a primary left lateral incisor in a Nubian child (1938–1756 BC), permanent left central incisor in an adult Egyptian (3650–3500 BC), and permanent right central incisor in a modern (19th century) adult from Guinea. Each co-occurs, respectively, with a talon cusp, peg lateral incisor and, in the latter individual, second premolar crown variation with rotation, and third molar dens evaginatus. Double tooth prevalence is 0.048% (CI 0.001%–0.270%), with regional variation, in premodern, and 0.000% in modern North Africans. It is 0.000% for premodern and 0.048% for modern sub-Saharan Africans (0.008%–1.714%).

Conclusions: The double incisors are comparable to other global examples, indicative of common developmental processes during odontogenesis. Prevalence is lower than published modern rates, to suggest some exceptionality in Africans as reported earlier for other dental variants. Finally, though circumstantial, double teeth and accompanying anomalies may share an etiology. Continuing research overall, and in Africa specifically, will promote an improved understanding of double teeth formation and expression.

1 | Introduction

Gemination, the partial splitting of one tooth germ, and fusion, the joining of two germs, both yield a similar range of phenotypes, from an abnormally wide crown and root to two partially fused crowns and roots. Thus, identification of cause and effect can be difficult, especially if a supernumerary tooth is involved

(Beltrán et al. 2013; Benazzi et al. 2010; Collina et al. 2021; Hillson 2023; Knežević et al. 2002; Rajashekhara et al. 2010). This prompts common use of the generic term “double tooth” for any such expression (Beltrán et al. 2013; Brook 1970; Collina et al. 2021; Marra et al. 2020; Sperduti et al. 2021). Other processes exist (e.g., concrescence, twinning; Pindborg 1970; Tannenbaum and Alling 1963) but are not discussed here.

This is an open access article under the terms of the [Creative Commons Attribution](https://creativecommons.org/licenses/by/4.0/) License, which permits use, distribution and reproduction in any medium, provided the original work is properly cited.

© 2024 The Author(s). *American Journal of Human Biology* published by Wiley Periodicals LLC.

The etiology of double teeth is open for debate (Knežević et al. 2002; Marra et al. 2020; Ramamurthy, Satish, and Priya 2014), with potential factors ranging from heredity to local trauma and even ionizing radiation (Hunasgi et al. 2017). In any event, gemination and fusion occur during the morphodifferentiation stage of odontogenesis (Beltrán et al. 2013; Knežević et al. 2002). Beyond an interesting phenomenon, double teeth are of clinical import concerning crowding, esthetics, and prospective caries sites (Hunasgi et al. 2017; Knežević et al. 2002; Marra et al. 2020; Ramamurthy, Satish, and Priya 2014). Primary and, to a lesser extent, permanent dentitions can be affected, notably incisors and canines. Teeth may exhibit one or two pulp cavities and/or canals, with either uni- or bilateral expression in the maxilla or, more so, the mandible. With exception (Knežević et al. 2002) insignificant sex differences are reported by type, expression, and rate (Aguiló et al. 1999; Beltrán et al. 2013; Benazzi et al. 2010; Hillson 2023; Knežević et al. 2002; Marra et al. 2020; Pindborg 1970; Ramamurthy, Satish, and Priya 2014; Santos, Forte, and Rocha 2003; Šarkić et al. 2022; Tannenbaum and Alling 1963).

Though copiously documented, double teeth are rare worldwide, reportedly 0.5%–4.1% in primary and 0.1%–1.0% in permanent teeth (Beltrán et al. 2013; Castelino, Babu, and Shetty 2015; Guttal et al. 2010; Marra et al. 2020; Pindborg 1970; Ramamurthy, Satish, and Priya 2014; Scheid 2007; Wu et al. 2019). Hunasgi et al. (2017) present an excellent summary table of known clinical studies, with the primary and permanent teeth involved and world regions. The table does not include data from Africa, which as noted in prior dental anomaly research is understudied historically (Irish 2020, 2022, 2024). The only clinical data come from Nigeria, with rates of 0.4%–1.9% for double teeth in primary and 0.0% in permanent dentitions (Folayan et al. 2019; Onyeaso and Onyeaso 2006; Temilola et al. 2014).

Archeological evidence is also known globally, but an apparent equal rarity in ancient times limits publications to case studies of individuals dated thousands to a few hundred years ago (Benazzi et al. 2010; Collina et al. 2021; Forshaw 2021; Halcrow and Tayles 2010; Mays 2005; Padgett 2010; Phillips, Irish, and Antoine 2021; Ruffer 1920; Šarkić et al. 2022; Silva and Subtil 2009; Sperduti et al. 2021). Collina et al. (2021) and Sperduti et al. (2021) provide recent literature reviews documenting ~40 cases of double teeth, mostly in the primary dentition, along with two adults from continental Africa: one dates 1900–1800 BC from Egypt (Forshaw 2021) and the other AD 500–1500 from Upper Nubia/Central Sudan (Phillips, Irish, and Antoine 2021).

The present report augments the existing African data by describing double incisors in three more individuals from the continent. In line with the reported rarity, these are the only examples in >5600 North and sub-Saharan African dentitions examined. Thus, the presence, expression, and potential developmental processes for each can be presented in detail, to contrast with findings from other world regions. Comparisons are also made against the full African database to calculate prevalence by period and geographic area. Other rare dental anomalies in each individual are identified and evaluated as well.

2 | Materials and Methods

Ninety-seven samples comprising 5631 late Pleistocene through modern (considered as 19th–20th century) dentitions were screened for double teeth presence. All were recorded originally to estimate biological affinities (Irish 1997, 1998, 2000, 2006, 2013, 2016) using 36 heritable morphological traits in the Arizona State University Dental Anthropology System (ASUDAS; Scott and Irish 2017). As standard protocol other data were also collected, including a range of anomalies (Irish 2020, 2022, 2024). Traits were mostly recorded in skeletal dentitions, along with ~200 hardstone casts. Affinity estimates are based on permanent teeth, but individuals aged 6 years and younger were included if at least one permanent tooth was present—erupted or recordable in its alveolus. As little or no sexual dimorphism is reported for double teeth, the sexes are pooled for analysis. Forty-five samples with 2689 dentitions derive from six North African countries, and 52 comprised of 2942 dentitions come from 20 sub-Saharan countries (Figure 1). Sample details can be accessed in the above references.

Of these, just the three abovementioned individuals have germination or fusion: a premodern child and adult from Egypt, and a modern adult from Guinea. As only permanent teeth were the focus, prevalence calculations are restricted to the adults. For both, only spatiotemporally relevant dentitions (below) with matching teeth and/or alveoli are included for comparison. A Poisson model was applied to provide 95% confidence intervals (CI), within which the true prevalence should be contained (Rothman, Greenland, and Lash 2008). The other dental anomalies, which may or may not be linked with double teeth formation, are then described.

3 | Results

3.1 | The Premodern Child From Egypt

The partially complete skeleton of a 4–5-year-old child, based on primary tooth eruption and permanent tooth formation (AlQahtani 2009), was recovered in site HK27C—a cemetery at the ancient Egyptian city of Hierakonpolis (Figure 1). Tomb 37, in which the child was interred, dates to the 12th Dynasty (1938–1756 BC). Interestingly, those buried in the cemetery were not Egyptians, but C-Group Nubians who traditionally lived south of present-day Aswan—113 km south. For unknown reasons they lived with Egyptians at Hierakonpolis for several hundred years, from the 11th Dynasty into the Second Intermediate period (Friedman 2007).

The primary left lateral maxillary incisor has two incompletely fused crowns with more complete root union (Figure 2). The maxilla is missing, but the normal complement of primary incisors and canines was recovered. The undamaged mandible (not shown) retains nine of 10 primary teeth and all first and second permanent molars partially formed within their crypts. The double tooth appears to have two pulp cavities and canals, but radiography was not available to confirm. Thus, interpretation of the process responsible in this and the other two individuals must be based on surface morphology (see Section 4).

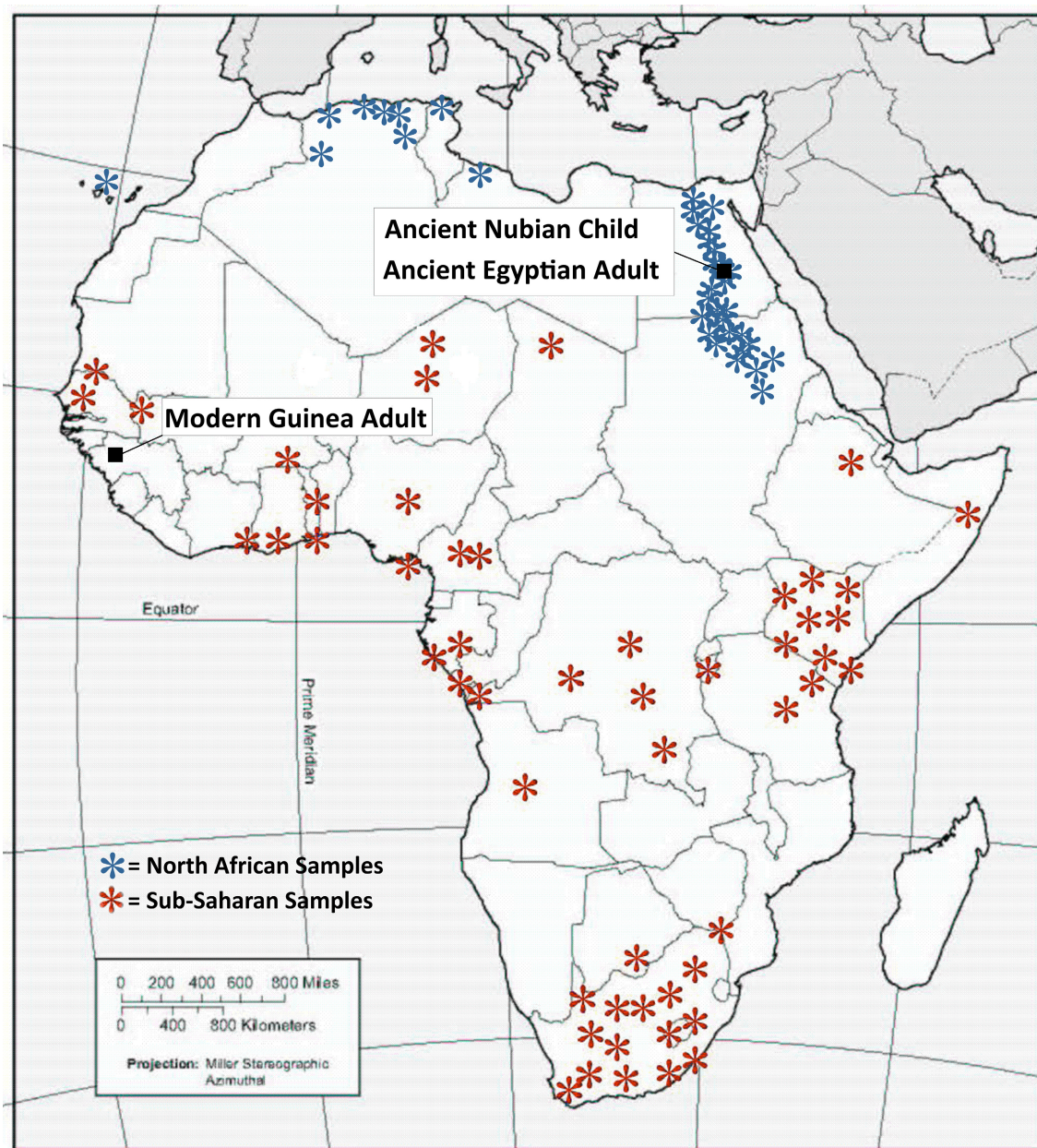


FIGURE 1 | General distribution of North and sub-Saharan African samples in present study. Geographic origins of the three individuals with double teeth noted. See text for more information. Africa map from Arizona Geographic Alliance, Arizona State University.

A second anomaly, a talon cusp, is centrally positioned on the tooth, emanating from the most mesial crown. Like gemination and fusion, this cusp forms early in odontogenesis (Halcrow and Tayles 2010; Hattab et al. 1995). According to Hattab et al. (1995:372), it is a “Type 1 (true talon): An anatomically well delineated additional cusp that prominently projects from the palatal surface of a primary or permanent anterior tooth and extends at least half the distance from the cemento-enamel junction to the incisal edge.”

3.2 | The Premodern Egyptian Adult

This elderly male, based on skeletal morphometric features (e.g., Buikstra and Ubelaker 1994), is also from Hierakonpolis. However, unlike the Nubian child he was culturally Egyptian.

He also lived much earlier, based on recovery (Burial 421) from a predynastic cemetery (HK43) used c. 3650–3500 BC in the Naqada II period (Friedman et al. 1999; Friedman 2008; Hierakonpolis-online 2012–2024).

His teeth are heavily worn, but the left central maxillary incisor clearly manifests as a double tooth (Figure 3). Wear removed evidence of whether a furrow was present on the buccal or lingual surfaces (Beltrán et al. 2013), but union of the crowns might have been complete. Again, radiography was unavailable, so pulp cavity and canal number are unknown. The tooth was not extracted, but the surrounding alveolar bone implies a single wide root. The mandible (not shown) retains a normal set of equally worn permanent teeth.

Given the antiquity of this individual and the significant biological distance between populations north and south of the

Sahara (Irish 1998), 2557 other premodern North African dentitions, c. 11 000 BC–AD 1400, in 41 samples (of total 2689 in 45 samples) were examined to calculate prevalence (sample details in Irish 2000). The 132 modern individuals, none with double teeth, were dropped from analysis. Of the 2557 dentitions, 2066 retained the requisite maxillary incisors and/or alveoli for a transregional rate of 0.0484%, with a 95% CI of 0.001–0.270%. When compared only with other ancient Egyptians (18 samples, 1018 inds), 4650 BC–AD 600, it is 0.098% (CI 0.002%–0.547%).

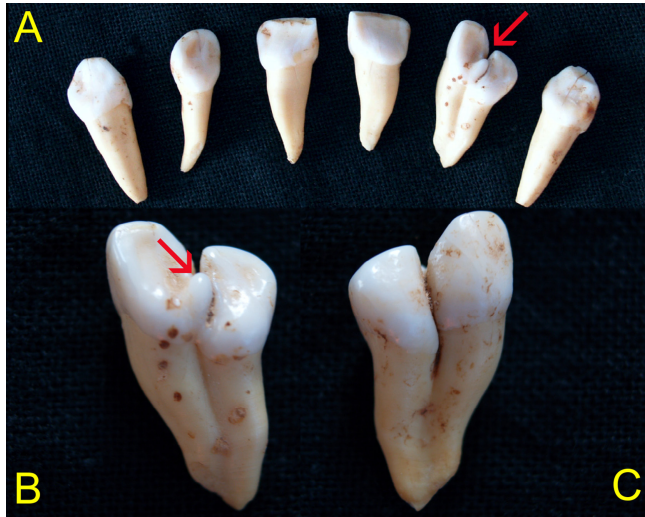

FIGURE 2 | Anterior primary maxillary teeth of premodern Nubian child. (A) Incisors and canines; double left lateral maxillary incisor identified with arrow. (B) Lingual detail of double incisor; talon cusp identified with arrow. (C) Labial detail of double incisor. See text for details.

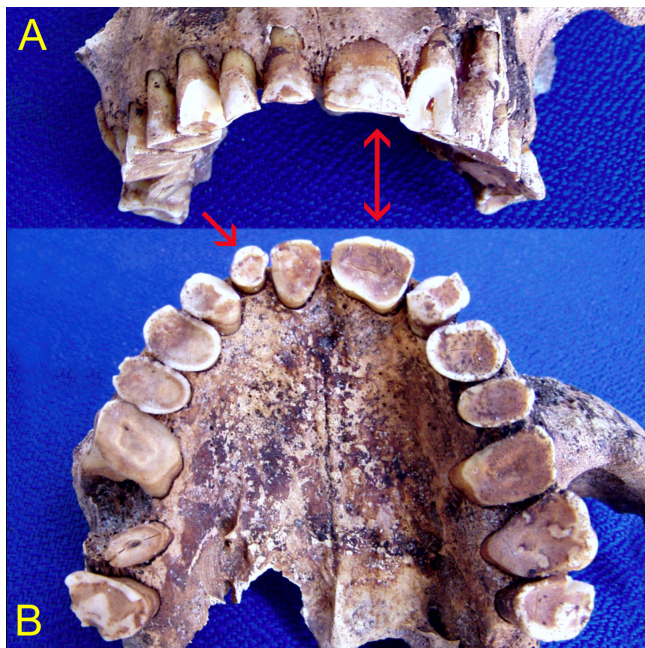


FIGURE 3 | Permanent dentition of premodern Egyptian adult male, with double arrow identifying double left central maxillary incisor. (A) Labial view. (B) Occlusal view with arrow pointing to peg/reduced right lateral incisor. See text for details.

In this case the accompanying anomaly is a peg/reduced right lateral incisor. Lateral maxillary incisors exhibit a range of unusual forms in global populations (Kondo, Townsend, and Matsuno 2014; Scott and Irish 2017) so all variants are recorded in the ASUDAS. This tooth is counted as “Grade 1: UI2 normal in form but diminutive in size (less than ½ mesiodistal diameter of UI1)” (Scott and Irish 2017: 137). The left lateral incisor is of normal proportion relative to the other teeth.

3.3 | The Modern Adult From Guinea

The third individual dates to the 19th century according to curation records (National Museum of Natural History, #00244057). But beyond the country of origin (Figure 1) little else is known. Diagnostic cranial features, basilar suture fusion (e.g., Buikstra and Ubelaker 1994), and third molar eruption imply that he was a male >18-years-old. Minimal tooth wear and incomplete cranial vault suture fusion suggest further that he did not reach middle age.

The right maxillary central incisor is striking in appearance, not just as a double tooth but because it was intentionally modified like the other incisors, which was a known practice in West Africa into the early 20th century (Irish 2017). Crown union is incomplete with labial and lingual furrows (Figure 4). Radiographs were not made, but two separate pulp cavities are indicated—in part due to secondary dentine formation seen as darker brown patches in the center of each incisal margin. The tooth was not extracted, so the extent to which the roots are fused is unknown. That said, both furrows run at least part way down the root, though the shape of overlying bone may suggest a single apex. The mandible (not shown) retains a

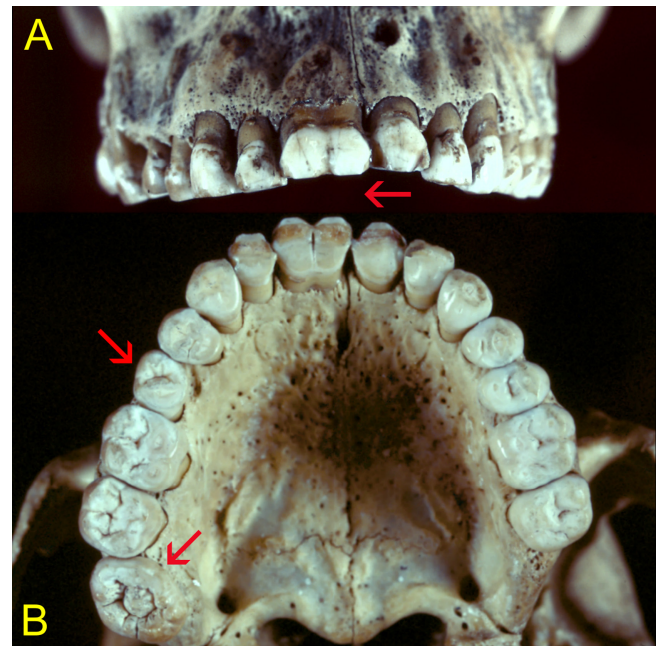


FIGURE 4 | Permanent dentition of modern adult male from Guinea, with arrow identifying double right central maxillary incisor. (A) Labial view. (B) Occlusal view with arrows pointing to rotated right second premolar with atypical crown morphology, and right third molar expressing dens evaginatus. See text for details.

normal complement of permanent teeth, including both third molars.

In this instance, data from 2236 sub-Saharan African dentitions in 37 19th–20th century samples (of total 2942 in 52 samples) were screened to calculate modern prevalence. Sample details are available in Irish (1997, 2016, 2022, 2024). Again, temporally distinct data, here 15 premodern samples (706 inds; c. 10800 BC–AD 1500) without double teeth, were excluded from comparison. Of the 2236 modern dentitions, 2080 had maxillary incisors and/or alveoli for the same rate as above, 0.048% (CI 0.001–0.268), for the subcontinent. When compared on regional basis to eight other modern West African samples (325 inds; Irish 2022, 2024) the prevalence is 0.308% (CI 0.008%–1.714%).

A second, less obvious anomaly in this individual is a right second premolar with a buccolingually “compressed” crown, that is, relative to its antimere and first premolars, which is rotated (Adeyemi et al. 2023; McMullan and Kvam 1990; Nayak and Singh 2013; Stefan 2006; Suresh, Zhong, and Yadav 2020). The atypical crown makes cusp identification and, thus, the degree of rotation uncertain. If the premolar’s actual buccal cusp is top-most in Figure 4, then the tooth is rotated mesially ~50°; conversely, if it is instead the lingual cusp then the tooth is rotated distally ~130° (McMullan and Kvam 1990).

A third anomaly is equally striking to that of the double incisor, a right third molar with a large central cusp, or dens evaginatus (Kocsis et al. 2002; Levitan and Himel 2006; Nagaveni and Umashankara 2013). Several DE types exist depending on the tooth involved. According to Schulze (1987) the present molar is a Type 5, manifesting as a tubercle on the occlusal surface that obliterates the central groove. Kocsis et al. (2002:77) would classify it as their “Type 3: A supernumerary cusp on the occlusal surface arising from or near the groove between the original buccal and the lingual cusps of premolars and molars. The central cusp type is the dens evaginatus.” The present central cusp looks to be a ridged form, one of four defined by Lau (1955). The missing left third molar might be agenetic, as the left second molar in that field has neither distal interproximal staining nor a wear facet, and visual inspection failed to identify impaction.

4 | Discussion

Similarities exist among the three individuals; all double teeth are maxillary incisors, and at least one additional anomaly is expressed. However, there are differences in the (1) affected teeth—primary versus permanent, lateral versus central incisor, degree of union, and (2) type and location of the other anomalies. The process responsible for each double tooth also likely differs. Unfortunately, radiography, the preferred method to differentiate gemination from fusion (Beltrán et al. 2013; Collina et al. 2021; Knežević et al. 2002) was not available during data collection. So visual inspection of each double incisor and tooth count, namely, a normal versus reduced complement (Hernandez-Guisado et al. 2002; Knežević et al. 2002; Koszowski et al. 2014; Milazzo and Alexander 1982) must suffice to imply cause. The context of occurrence and expression

for each double tooth, and the same again for all accompanying anomalies is also provided.

4.1 | The Premodern Child From Egypt

Two pulp cavities and two canals, as suggested in the child’s double primary lateral incisor, is common when two germs unite in the fusion process during morphodifferentiation (Beltrán et al. 2013; Knežević et al. 2002). However, this ordinarily yields a reduced number of teeth (hypodontia) (Beltrán et al. 2013; Knežević et al. 2002; Pindborg 1970). The standard complement of four incisor and two canine “entities” or “units” (Pindborg 1970; Tannenbaum and Alling 1963) is present, including the double incisor unit. So, on this basis (Milazzo and Alexander 1982; also, Knežević et al. 2002) gemination of the left incisor germ may instead be responsible. A third possibility again entails fusion, but with normal and supernumerary incisor germs. This would explain the presence of two cavities/canals and the normal tooth number. Rarity of supernumerary primary teeth (Bello et al. 2019; Giudice et al. 2008) would seemingly argue against such an occurrence, but is not without precedence (Knežević et al. 2002; Ramamurthy, Satish, and Priya 2014), including archeological examples (Benazzi et al. 2010; Halcrow and Tayles 2010; Padgett 2010). All told, the developmental process is not identified here with any certainty.

As stated, primary double teeth, especially incisors and canines, dominate relative to permanent (Beltrán et al. 2013; Castelino, Babu, and Shetty 2015; Guttal et al. 2010; Marra et al. 2020; Pindborg 1970; Ramamurthy, Satish, and Priya 2014; Scheid 2007; Wu et al. 2019). This dominance is also implied in archeological studies, with affected primary teeth from ~30 world locations dating 2500–1000 BC¹ in the USA to AD 1600–1700 in Japan (Collina et al. 2021; Sperduti et al. 2021). So, the Nubian child (1938–1756 BC) is one of the earliest cases. Primary mandibular incisors are most affected (e.g., Šarkić et al. 2022) but like here ~10 cases of rarer double maxillary teeth are reported (list in Sperduti et al. 2021), including: (1) a triple incisor with supernumerary tooth in a nine-month-old (c. 1540–1715 AD) from Alabama, USA (Padgett 2010); (2) a lateral incisor in a medieval British child (Mays 2005); (3) a left incisor in a medieval Portuguese three-year-old (Silva and Subtil 2009); (4) a combined right central/lateral incisor in a medieval Italian five-year-old (Benazzi et al. 2010); (5) from three Italian sites (7th century BC–7th century AD), a right central incisor in a three-year-old, a right central/lateral incisor in a nine-month-old, and a right central incisor in a two- to three-year-old (Sperduti et al. 2021); and (6) a left lateral incisor from a Thai six-month-old infant (c. 1850 BC–AD 450) (Halcrow and Tayles 2010).

The prevalence of talon cusp in primary incisors is low, more so than their permanent successors. However, exact figures are difficult to ascertain because many do not differentiate by dentition type (Decaup, Garot, and Rouas 2021). That said, 0.6% was reported in Japanese (Ooshima et al. 1996) and 0.01% in Turkish children, mostly in central maxillary incisors. In a literature review Lee et al. (2007) found only five examples of talon cusp in primary lateral incisors. So, the Nubian child’s double incisor is doubly exceptional. Regarding any potential association, because the talon cusp is attached to the affected tooth it must be

linked with its formation (also see Halcrow and Tayles 2010; Lee et al. 2007; Lomçali, Hazar, and Altinbulak 1994; Mays 2005) during odontogenesis (Hattab et al. 1995). As detailed in Halcrow and Tayles (2010) co-occurrence is known in permanent and, of interest, primary teeth, including their archeological study and two others (Mays 2005; Silva and Subtil 2009). Like double teeth (Hunasgi et al. 2017; Knežević et al. 2002; Marra et al. 2020; Ramamurthy, Satish, and Priya 2014), the etiology of talon cusp (Hattab et al. 1995) and how the two anomalies may be linked is unknown. However, as Halcrow and Tayles (2010): 245; also, Decaup, Garot, and Rouas (2021) propose, co-occurrence “may be consistent with the theory of Rantanen’s (1971) that talon cusp results from hyperactivity of the anterior part of the dental lamina,” citing supporting research (Lee et al. 2007; Mays 2005; Rushman and Meon 1991; also see below).

4.2 | The Premodern Egyptian Adult

Pulp cavity and canal numbers are not verified, but it appears the double tooth comprises one completely fused crown and root. This expression and the normal complement of 16 maxillary teeth/units implies gemination was the most probable developmental process (Beltrán et al. 2013; Knežević et al. 2002; Milazzo and Alexander 1982; Pindborg 1970). In support, contra fusion, gemination more often affects the anterior maxillary teeth (Koszowski et al. 2014).

Permanent double teeth are much rarer than primary, particularly in archeological studies, but three recent publications allow comparisons. First, Collina et al. (2021) reported the first documented case in an archeological context from Europe, though it is a mandibular tooth. It was said to have formed via fusion of the right central and lateral incisors in a 6th–7th century AD adult male from Italy. Second, Phillips, Irish, and Antoine (2021) identified an example in an adult female from near the 4th Cataract in Upper Nubia/Central Sudan, dating c. AD 500–1550. Like the Hierakonpolis Egyptian, she had a double left central maxillary incisor. It is little worn, so labial and lingual grooves remain visible on the crown. It was not concluded if the process was gemination or fusion. Notably, like the three present individuals a second anomaly is expressed, that is, a supernumerary right maxillary incisor. Thus, it is possible the double central incisor combined with the latter’s supernumerary antimere (Phillips, Irish, and Antoine 2021), unlike the present probable instance of gemination. Finally, an old article (Ruffer 1920) reported double teeth in ancient Egypt based on an even older volume (Murray 1910). But these teeth were recently detailed by Forshaw (2021), who suspects fusion yielded the double left maxillary central incisor and gemination the right, in a 12th Dynasty (c. 1900–1800 BC) adult male from Dier Rifeh. This author also identified it as the oldest example yet documented. But for now the Hierakonpolis double tooth (c. 3650–3500 BC) has that distinction, at ~2000 years older.

Archeological examples of double teeth are so exceptional—prompting descriptions on individual bases—that no previous attempts have been made to quantify spatiotemporal prevalence. Here, the large database permits a transregional, North African indication, though it is equivocal given the >12000-year range of

comparative data. The figure 0.048% (1/2066 inds.) is well below 0.1%–1.0% in modern populations (Beltrán et al. 2013; Castolino, Babu, and Shetty 2015; Guttal et al. 2010; Marra et al. 2020; Pindborg 1970; Ramamurthy, Satish, and Priya 2014; Scheid 2007; Wu et al. 2019), though the CI reaches 0.270%. On perhaps a more reliable level, the rate for ancient Egyptians only is ~0.100% (CI up to 0.547%). Either way, the figures imply that double teeth were quite rare in premodern North Africans, at least relative to other world regions—not including 0.000% in the 132 modern North African dentitions excluded from analysis.

Lastly, the second dental anomaly in the Egyptian individual, his peg/reduced right lateral incisor is infrequent but not, for example, to the extent of the talon cusp or dens evaginatus (below). Its prevalence in 15 Egyptian samples (786 inds; 4650 BC–AD 600) reaches 11.1%, including 3.6% at Hierakonpolis (Irish 2006). Not being part of the double central incisor, the prospect of a link between anomalies is more circumstantial. Both teeth are in the same field, tooth size is established during morphodifferentiation (Chanchala and Nandlal 2012; Kondo, Townsend, and Matsuno 2014) like gemination/fusion, and several proposed etiologies for tooth size reduction (Kondo, Townsend, and Matsuno 2014) overlap with those of double teeth. Yet odontogenesis of the central incisor initiates up to eight months before the lateral, and the two anomalous teeth are separated physically. So, while not identifiable here, a shared etiology would likely be more general than specific in nature, e.g., genetic as opposed to localized trauma, among others.

4.3 | The Modern Adult From Guinea

The two crowns comprising the right maxillary central incisor unit are partially fused, though separate pulp cavities are indicated. This implies two canals, which might seem unlikely in a single root, but is known to occur (see below), and perhaps they merge near the apex. This uncertainty makes identifying the developmental process particularly difficult. According to Knežević et al. (2002) two pulp cavities (partial union notwithstanding), one root, and a normal complement of anterior teeth may suggest gemination (Beltrán et al. 2013; Koszowski et al. 2014; Milazzo and Alexander 1982; Pindborg 1970). But fusion with a supernumerary tooth cannot be ruled out.

Modern examples of double permanent teeth are also rare, but at least relative to the archeological studies more evidence exists. In an extensive literature review Hunasgi et al. (2017) cite just 12 articles, though others exist including three cited here (Ramamurthy, Satish, and Priya 2014; Tannenbaum and Alling 1963; Temilola et al. 2014). Using all for comparison, of 14 non-African cases 12 involve maxillary incisors, of which nine are central incisors. The responsible process is in question for most, but two do seem akin to the Guinea tooth: (1) a right central incisor with two canals in a Turkish man (Türkaskan, Gökçe, and Dalkız 2007), and (2) both central incisors, each with one root, two canals, and one apical foramen in an Iranian boy (Shokri, Baharvand, and Mortazavi 2013). The only sub-Saharan clinical study on the permanent dentition, from Nigeria, lists a rate of 0.0% in 7135 teeth from an unspecified number of individuals (Temilola et al. 2014).

The calculated prevalence of 0.048% (CI 0.001%–0.268%) for sub-Saharan Africa (Guinea individual/2080) is half that of the low value in the global range, 0.1%–1.0% (Beltrán et al. 2013; Castelino, Babu, and Shetty 2015; Guttal et al. 2010; Marra et al. 2020; Pindborg 1970; Ramamurthy, Satish, and Priya 2014; Scheid 2007; Wu et al. 2019). And, as above, no double teeth are present in 706 premodern individuals (0.000%). Perhaps this parallels other high and low rates of anomalies, including hyperdontia (Irish 2022) and hypodontia (Irish 2024), respectively, to suggest some distinctiveness from other world populations. The West African-only rate of 0.308% (1/325; CI 0.008%–1.714%) is in the modern range but given the rarity of double teeth, smaller sample size should be considered. Indeed, the rate would be lower if the Nigerian data (Temilola et al. 2014) were compatible for inclusion.

Concerning modification of the individual's double tooth, this practice, as stated, was common in West Africa and elsewhere in the subcontinent at the time (Irish 2017). The dental operator skillfully accentuated the labial furrow to simulate two fully separated crowns. Each of these and the other incisors were modified further by removing the mesial and distal incisal edges for an archetypal West African 'fang' variant (Irish 2017). It is also evident that the left central incisor's pulp cavity was perforated to yield an alveolar abscess at the root tip.

The second anomaly involves atypical crown morphology and rotation of the maxillary right second premolar. Variation of premolar crowns is known (Scott and Irish 2017), but unless it is a well-documented form (e.g., peg, odontome, accessory cusps, agenetic) prevalence figures are lacking in the literature. Overall tooth rotation is not particularly rare, occurring between 10.2% and 20.2% in the permanent dentition (Adeyemi et al. 2023; McMullan and Kvam 1990; Nayak and Singh 2013; Stefan 2006; Suresh, Zhong, and Yadav 2020). But based on individual case studies, second maxillary premolars are seemingly much less affected, particularly if rotation is extreme, that is, if the present individual's tooth is indeed rotated $\sim 130^\circ$ rather than $\sim 50^\circ$ (Adeyemi et al. 2023; Nayak and Singh 2013; Suresh, Zhong, and Yadav 2020). The variation in crown morphology would occur during morphodifferentiation—though up to 2 years later than with the double central incisor. The etiology of rotation is less certain, with suspected causes ranging from space limitations to hereditary factors in odontogenesis (Adeyemi et al. 2023; McMullan and Kvam 1990; Nayak and Singh 2013; Stefan 2006; Suresh, Zhong, and Yadav 2020).

Finally, the third rare anomaly, dens evaginatus (DE), occurs on the occlusal surface of the maxillary right third molar. However, DE has been reported in all tooth classes (Levitan and Himel 2006). Of interest, in anterior teeth it arises on the lingual surface, though is better known by its common name, talon cusp—a subclass of DE (Kocsis et al. 2002; Levitan and Himel 2006). In posterior teeth it forms as a tubercle on the crown (Levitan and Himel 2006), often as a central cusp (Kocsis et al. 2002). Of all teeth the premolars are most affected, with expression usually denoted by its more customary name of odontome (Danish et al. 2014; Kocsis et al. 2002; Levitan and Himel 2006). The latter is part of the

ASUDAS and is of highest frequencies in Asians and Native Americans (Danish et al. 2014; Kocsis et al. 2002; Levitan and Himel 2006; Scott and Irish 2017) at 0.0%–6.3% (Escobar, Michael Conneally, and Lopez 1977). DE is rarer in molars, though with larger tubercles on the first and second molars (Kocsis et al. 2002). Nagaveni and Umashankara (2013) were the first to record DE involving a maxillary third molar, in an Indian man. The Guinea maxillary third molar matches closely the latter tooth in appearance and is now just the second documented example.

Like all preceding anomalies DE forms in morphodifferentiation (Danish et al. 2014; Levitan and Himel 2006). But here, any link with the double incisor is even more tenuous than, for example, the individual's anomalous premolar. The incisor and molar are not only present in separate dental fields but are located at opposite ends of the maxilla. Further, third molar odontogenesis begins up to 9 years after that of the central incisor. The etiology of DE is again tentative, but a genetic component is assumed based on familial research; moreover, DE was linked with other anomalies and syndromes (Danish et al. 2014; Kocsis et al. 2002; Levitan and Himel 2006; Nagaveni and Umashankara 2013). Therefore again, any shared etiology of anomalies in the Guinea individual would likely be general in nature, and based on the assumed cause of DE, the same factor might be implicated in the premolar and double tooth expression.

5 | Conclusions

This study provides new information on primary and permanent double teeth in North and sub-Saharan Africans past and present. Until now, this anomaly was largely unstudied there, with the notable exceptions of Nigerian clinical research and two archeological case studies. Here, double incisors in a premodern Nubian child (1938–1756 BC), a premodern Egyptian adult (c. 3650–3500 BC), and a modern (19th century) adult from Guinea were detailed relative to other world data. Overall similarities in expression and, likely, formation were revealed. The child's lateral incisor, if not the earliest, is among the earliest examples of primary double teeth. The Egyptian's central incisor is the oldest permanent double tooth, pushing the first evidence for this anomaly back ~ 5600 years. Also, for the first time, premodern prevalence could be calculated, here in North Africans overall and Egyptians specifically; both are below modern global rates. Prevalence for modern sub-Saharan Africans overall is also lower, based on the Guinea double central incisor. On a West African regional level, it is within the global range, but with caveats noted. In reality, the cross-continent prevalence is considerably lower when considering the modern North African and premodern sub-Saharan dentitions in the database that do not express double teeth. Finally, the accompanying rare dental anomalies recorded in each individual might suggest a shared etiology, though links are circumstantial. As such, continuing research on double teeth overall, and in Africa specifically—preferably using radiography, is needed to promote a better understanding of this singular anomaly, of interest to clinicians, dental anthropologists, and a host of other researchers.

Acknowledgments

For their help during data collection the author thanks everybody affiliated with the American Museum of Natural History, Arizona State University, British Museum, Combined Prehistoric Expedition, Florisbad Quaternary Research Station, Hierakonpolis Expedition, Institut de Paléontologie Humaine, Institut royal des Sciences naturelles de Belgique, Musée de l'Homme, National Museums of Kenya, Natural History Museum, National Museum of Natural History, Panum Institut, Purdue University, Southern Methodist University, Université Libre de Bruxelles, University of Cambridge, University of Cape Town, University of Minnesota, University of Pittsburgh, and University of the Witwatersrand. Funding for data collection was awarded to the author by the ASU Research Development Program, American Museum of Natural History, Friends of Nekhen (R Friedman), Institute of Archaeology and Ethnology—Polish Academy of Sciences, Institute for Bioarchaeology, National Science Foundation (BNS-9013942, BNS-0104731, BCS-0840674). Additional funding was from an NSF grant to J Rose (BCS-0119754) and J Kabaciński from the National Science Centre (2017/25/B/HS3/03928).

Ethics Statement

These data were collected while the author was affiliated with universities in the USA prior to 2012 which, at that time, did not require ethics approval for non-destructive collecting of dental data in human skeletal material or existing hardstone casts from living individuals.

Conflicts of Interest

The authors declare no conflicts of interest.

Data Availability Statement

The data that support the findings of this study are available from the corresponding author upon reasonable request.

Endnotes

¹A potential earlier date of 8000–1000 BC is listed for Law's Site in the USA by Sperduti et al. (2021), but the author of the original study states the age of burials there is much younger, likely 1540–1715 AD (Padgett 2010).

References

- Adeyemi, T. E., G. O. Ewansiha, M. N. Adekoya, and M. M. Iya. 2023. "Bilateral 90° Rotation of Maxillary Second Premolar: A Rare Case Report in Nigeria and Review of Literature." *Journal of Paediatric Dental Research and Practice* 4, no. 2: 65–69.
- Aguiló, L., J. L. Gandia, R. Cibrán, and M. Catala. 1999. "Primary Double Teeth. A Retrospective Clinical Study of Their Morphological Characteristics and Associated Anomalies." *International Journal of Paediatric Dentistry* 9, no. 3: 175–183.
- AlQahtani, S. J. 2009. *Atlas of Human Tooth Development and Eruption*. London: Queen Mary and Westfield College.
- Bello, S., W. Olatunbosun, J. Adeoye, A. Adebayo, and N. Ikimi. 2019. "Prevalence and Presentation of Hyperdontia in a Non-syndromic, Mixed Nigerian Population." *Journal of Clinical and Experimental Dentistry* 11, no. 10: e930.
- Beltrán, V., C. Leiva, I. Valdivia, M. Cantín, and R. Fuentes. 2013. "Geminación Dental en un Incisivo Central Mandibular Permanente: una Anomalia Dental Infrecuente." *International journal of odontostomatology* 7, no. 1: 69–72.
- Benazzi, S., L. Buti, L. Franzo, O. Kullmer, O. Winzen, and G. Gruppioni. 2010. "Report of Three Fused Primary Human Teeth in an

Archaeological Material." *International Journal of Osteoarchaeology* 20, no. 4: 481–485.

Brook, A. H. 1970. "Double Teeth, A Retrospective Study of 'geminated' and 'fused' Teeth in Children." *British Dental Journal* 129: 123–130.

Buikstra, J. E., and D. H. Ubelaker. 1994. *Standards for Data Collection From Human Skeletal Remains*. Arkansas Archaeological Survey Research Series No. 44. Fayetteville: Arkansas Archaeological Survey.

Castelino, R. L., S. G. Babu, and S. R. Shetty. 2015. "Synodontia of Permanent Mandibular Central and Lateral Incisor—A Rare Entity." *Balkan Military Medical Review* 18: 1–3.

Chanchala, H. P., and B. Nandlal. 2012. "Coexistent peg Shaped Mandibular Central Incisors Along With Maxillary Lateral Incisors—A Rare Case." *International Journal of Oral and Maxillofacial Pathology* 3, no. 1: 65–68.

Collina, F., S. Conti, M. Menetti, L. Scheda, R. Sorrentino, and S. Benazzi. 2021. "The First Archaeological Case of Permanent Teeth Fusion in Europe." *International Journal of Osteoarchaeology* 31, no. 3: 469–474.

Danish, G., U. Hegde, P. Mull, and S. Nabeel. 2014. "Dental Cusps: Normal, Supernumerary and Cusp-Like Structures—An Overview." *Journal of Orofacial Research* 4, no. 3: 161–168.

Decaup, P. H., E. Garot, and P. Rouas. 2021. "Prevalence of Talon Cusp: Systematic Literature Review, Meta-Analysis and New Scoring System." *Archives of Oral Biology* 125: 105112.

Escobar, V., P. Michael Conneally, and C. Lopez. 1977. "The Dentition of the Quekchi Indians. Anthropological Aspects." *American Journal of Physical Anthropology* 47, no. 3: 443–451.

Folayan, M. O., M. Alade, A. Adeniyi, M. El Tantawi, and T. L. Finlayson. 2019. "Association Between Developmental Dental Anomalies, Early Childhood Caries and Oral Hygiene Status of 3–5-Year-Old Children in Ile-Ife, Nigeria." *BMC Oral Health* 20, no. 1: 1–7.

Forshaw, R. 2021. "The 'Two Brothers': Dental and Cranial Evidence Relating to Two Ancient Egyptian Mummies." *Canarias Arqueológica* 22: 455–467.

Friedman, R. 2007. "The C-Group Cemetery at Locality HK27C." *Sudan & Nubia* 11: 57–62.

Friedman, R. F. 2008. "The Cemeteries of Hierakonpolis." *Archéo-Nil* 18, no. 1: 8–29.

Friedman, R. F., A. Maish, A. G. Fahmy, J. C. Darnell, and E. D. Johnson. 1999. "Preliminary Report on Field Work at Hierakonpolis: 1996–1998." *Journal of the American Research Center in Egypt* 36: 1–35.

Giudice, G. L., V. Nigrone, A. Longo, and M. Cicciù. 2008. "Supernumerary and Supplemental Teeth: Case Report." *European Journal of Paediatric Dentistry* 9, no. 2: 97–101.

Guttal, K. S., V. G. Naikmasur, P. Bhargava, and R. J. Bathi. 2010. "Frequency of Developmental Dental Anomalies in the Indian Population." *European Journal of Dentistry* 4, no. 3: 263–269.

Halcrow, S. E., and N. Tayles. 2010. "Talon Cusp in a Deciduous Lateral Incisor From Prehistoric Southeast Asia." *International Journal of Osteoarchaeology* 20, no. 2: 240–247.

Hattab, F. N., O. M. Yassin, and K. S. Al-Nimri. 1995. "Talon Cusp—Clinical Significance and Management." *Quintessence International* 26: 115–120.

Hernandez-Guisado, J. M., D. Torres-Lagares, P. Infante-Cossio, and J. L. Gutierrez-Perez. 2002. "Dental Geminatio: Report of Case." *Medicina Oral* 7, no. 3: 231–236.

Hierakonpolis-online. 2012–2024. "The Workers' cemetery – HK43." Accessed April 26, 2024. <http://www.hierakonpolis-online.org/index.php/explore-the-predynastic-cemeteries/hk43-workers-cemetery>.

Hillson, S. 2023. *Dental Anthropology*. Second ed. Cambridge: Cambridge University Press.

- Hunasgi, S., A. Koneru, V. Manvikar, M. Vanishree, and R. Amrutha. 2017. "A Rare Case of Twinning Involving Primary Maxillary Lateral Incisor With Review of Literature." *Journal of Clinical and Diagnostic Research: JCDR* 11, no. 2: ZD09–ZD11.
- Irish, J. D. 1997. "Characteristic High-and Low-Frequency Dental Traits in sub-Saharan African Populations." *American Journal of Physical Anthropology* 102, no. 4: 455–467.
- Irish, J. D. 1998. "Dental Morphological Affinities of Late Pleistocene Through Recent Sub-Saharan and North African Peoples." *Bulletins et Memoires de la Societe d'Anthropologie de Paris. Nouvelle Serie* 10: 237–272.
- Irish, J. D. 2000. "The Iberomaurusian Enigma: North African Progenitor or Dead end?" *Journal of Human Evolution* 39, no. 4: 393–410.
- Irish, J. D. 2006. "Who Were the Ancient Egyptians? Dental Affinities Among Neolithic Through Postdynastic Peoples." *American Journal of Physical Anthropology* 129, no. 4: 529–543.
- Irish, J. D. 2013. "Afridonty: The "sub-Saharan African Dental Complex" Revisited." In *Anthropological Perspectives on Tooth Morphology: Genetics, Evolution, Variation*, edited by G. R. Scott and J. D. Irish, 278–295. Cambridge: Cambridge University Press.
- Irish, J. D. 2016. "Who Were They Really? Model-Free and Model-Bound Dental Nonmetric Analyses to Affirm Documented Population Affiliations of Seven South African "Bantu" Samples." *American Journal of Physical Anthropology* 159, no. 4: 655–670.
- Irish, J. D. 2017. "Knocking, Filing, and Chipping: Dental Modification in Sub-Saharan Africans." In *A World View of Bioculturally Modified Teeth*, edited by S. E. Burnett and J. D. Irish, 33–47. Gainesville: University Press of Florida.
- Irish, J. D. 2020. "Tooth Transposition Prevalence and Type Among Sub-Saharan Africans." *American Journal of Human Biology* 32, no. 2: e23329.
- Irish, J. D. 2022. "Hyperdontia Across Sub-Saharan Africa: Prevalence, Patterning, and Implications." *Archives of Oral Biology* 140: 105463.
- Irish, J. D. 2024. "Agenesis of the Permanent Teeth in Sub-Saharan Africans: Prevalence, Patterns, Interpretations." *Archives of Oral Biology* 162: 105961.
- Knežević, A., S. Travan, Z. Tarle, J. Šutalo, B. Janković, and I. Ciglar. 2002. "Double Tooth." *Collegium Antropologicum* 26, no. 2: 667–672.
- Kocsis, G., A. Marcsik, E. Kokai, and K. Kocsis. 2002. "Supernumerary Occlusal Cusps on Permanent Human Teeth." *Acta Biologica Szegediensis* 46, no. 1–2: 71–82.
- Kondo, S., G. Townsend, and M. Matsuno. 2014. "Morphological Variation of the Maxillary Lateral Incisor." *Japanese Dental Science Review* 50, no. 4: 100–107.
- Koszowski, R., J. Waśkowska, G. Kucharski, and J. Śmieszek-Wilczewska. 2014. "Double Teeth: Evaluation of 10-Years of Clinical Material." *Open Medicine* 9, no. 2: 254–263.
- Lau, T. 1955. "Odontomes of the Axial Core Type." *British Dental Journal* 99: 219–225.
- Lee, C. K., N. M. King, E. C. M. Lo, and S. Y. Cho. 2007. "The Relationship Between a Primary Maxillary Incisor With a Talon Cusp and the Permanent Successor: A Study of 57 Cases." *International Journal of Paediatric Dentistry* 17, no. 3: 178–185.
- Levitan, M. E., and V. T. Himel. 2006. "Dens Evaginatus: Literature Review, Pathophysiology, and Comprehensive Treatment Regimen." *Journal of Endodontics* 32, no. 1: 1–9.
- Lomçali, G., S. Hazar, and H. Altinbulak. 1994. "Talon Cusp: Report of Five Cases." *Quintessence International* 25, no. 6: 431–448.
- Marra, P. M., L. Nucci, L. Femiano, V. Grassia, L. Nastri, and L. Perillo. 2020. "Orthodontic Management of a Mandibular Double-Tooth Incisor: A Case Report." *Open Dentistry Journal* 14, no. 1: 219–225.
- Mays, S. 2005. "Talon Cusp in a Primary Lateral Incisor From a Medieval Child." *International Journal of Paediatric Dentistry* 15, no. 1: 67–72.
- McMullan, R. E., and E. Kvam. 1990. "Investigation of Premolar Rotation in a Group of 15-Year-Old Norwegian Children." *European Journal of Orthodontics* 12, no. 3: 311–315.
- Milazzo, A., and S. A. Alexander. 1982. "Fusion, Geminatio, Oligodontia, and Taurodontism." *Journal of Pedodontics* 6, no. 2: 194–199.
- Murray, M. A. 1910. *The Tomb of Two Brothers*. Vol. 68. Manchester: Sherratt & Hughes.
- Nagaveni, N. B., and K. V. Umashankara. 2013. "Maxillary Molar With Dens Evaginatus and Multiple Cusps: Report of a Rare Case and Literature Review." *International Journal of Oral Health Sciences* 3, no. 2: 92–97.
- Nayak, G., and I. Singh. 2013. "A Variation in Tooth Position-180 Rotated Maxillary Second Premolar." *Journal of Clinical and Diagnostic Research: JCDR* 7, no. 8: 1806–1807.
- Onyeaso, C. O., and A. O. Onyeaso. 2006. "Occlusal/Dental Anomalies Found in a Random Sample of Nigerian Schoolchildren." *Oral Health & Preventive Dentistry* 4, no. 3: 181–186.
- Ooshima, T., R. Ishida, K. Mishima, and S. Sobue. 1996. "The Prevalence of Developmental Anomalies of Teeth and Their Association With Tooth Size in the Primary and Permanent Dentitions of 1650 Japanese Children." *International Journal of Paediatric Dentistry* 6: 87–94.
- Padgett, B. D. 2010. "Triple Fusion in the Primary Dentition From Law's Site, Alabama (1MS100): A Case Report." *Dental Anthropology Journal* 23, no. 1: 25–27.
- Phillips, E. L., J. D. Irish, and D. Antoine. 2021. "Ancient Anomalies: Twinned and Supernumerary Incisors in a Medieval Nubian." *International Journal of Osteoarchaeology* 31, no. 3: 456–461.
- Pindborg, J. J. 1970. *Pathology of the Dental Hard Tissues*. Copenhagen: Munksgaard.
- Rajashekhara, B. S., B. Dave, B. S. Manjunatha, K. S. Poonacha, and S. Sujan. 2010. "Bilateral Fusion of Primary Mandibular Lateral Incisors and Canines: A Report of a Rare Case." *Revista Odonto Ciencia* 25, no. 4: 427–429.
- Ramamurthy, S., R. Satish, and K. Priya. 2014. "Surgical and Orthodontic Management of Fused Maxillary Central and Lateral Incisors in Early Mixed Dentition Stage." *Case Reports in Dentistry* 2014: 1–4.
- Rantanen, A. V. 1971. "Talon Cusp." *Oral Surgery, Oral Medicine, and Oral Pathology* 32: 398–400.
- Rothman, K. J., S. Greenland, and T. L. Lash. 2008. *Modern Epidemiology*. Vol. 3. Philadelphia: Wolters Kluwer Health/Lippincott Williams & Wilkins.
- Ruffer, S. A. 1920. "Study of Abnormalities and Pathology of Ancient Egyptian Teeth." *American Journal of Physical Anthropology* 3, no. 3: 335–382.
- Rushman, H., and R. Meon. 1991. "Talon Cusp in Malaysia." *Australian Dental Journal* 36: 11–14.
- Santos, L. M., F. D. S. Forte, and M. J. C. Rocha. 2003. "Pulp Therapy in a Maxillary Fused Primary Central Incisor—Report of a Case." *International Journal of Paediatric Dentistry* 13, no. 4: 274–278.
- Šarkić, N., S. Moreno, I. Erjavec, J. Herrerin, and L. González-Garrido. 2022. "A Micro-Computed Tomography Examination of Primary Double Teeth From the Muslim Necropolis of Macael Viejo (13th–16th Centuries; Almeria, Spain)." *Journal of Bioanthropology* 2, no. 2: 6–13.
- Scheid, R. C. 2007. *Woelfel's Dental Anatomy: Its Relevance to Dentistry*. 10th ed. Philadelphia, PA: Lippincott Williams & Wilkins.
- Schulze, C. 1987. *Anomalien und Missbildungen der menschlichen Zähne*. Berlin: Die Quintessenz.

- Scott, G. R., and J. D. Irish. 2017. *Human Tooth Crown and Root Morphology: The Arizona State University Dental Anthropology System*. Cambridge: Cambridge University Press.
- Shokri, A., M. Baharvand, and H. Mortazavi. 2013. "The Largest Bilateral Gemination of Permanent Maxillary Central Incisors: Report of a Case." *Journal of Clinical and Experimental Dentistry* 5, no. 5: e295.
- Silva, A. M., and A. C. Subtil. 2009. "Talon Cusp in a Deciduous Upper Incisor From a Medieval Portuguese Child." *Anthropological Science* 117: 45–49.
- Sperduti, A., L. Fattore, M. Botto, et al. 2021. "Dental Twinning in the Primary Dentition: New Archaeological Cases From Italy." *Bulletin Of The International Association For Paleodontology* 15, no. 1: 6–20.
- Stefan, V. H. 2006. "Brief Communication: Rotation of the Maxillary Premolars: Evidence in Support of Premolar Morphogenetic Field." *Dental Anthropology Journal* 19, no. 3: 70–73.
- Suresh, K. V., C. Y. Zhong, and S. Yadav. 2020. "Bilateral 180 Rotated Maxillary Second Premolars: A Rare Case Report." *Journal of Datta Meghe Institute of Medical Sciences University* 15, no. 4: 662–664.
- Tannenbaum, K. A., and E. E. Alling. 1963. "Anomalous Tooth Development: Case Reports of Geminatio and Twinning." *Oral Surgery* 18: 883–887.
- Temilola, D. O., M. O. Folayan, O. Fatusi, et al. 2014. "The Prevalence, Pattern and Clinical Presentation of Developmental Dental Hard-Tissue Anomalies in Children With Primary and mix Dentition From Ile-Ife, Nigeria." *BMC Oral Health* 14: 1–8.
- Türkaskan, S., H. S. Gökçe, and M. Dalkız. 2007. "Esthetic Rehabilitation of Bilateral Geminated Teeth: A Case Report." *European Journal of Dentistry* 1, no. 3: 188–191.
- Wu, L., B. Shi, R. Zhang, and J. Liu. 2019. "Case Report Root Canal Therapy of a Supernumerary Tooth Fused With Maxillary Second Molar: A Case Report." *International Journal of Clinical and Experimental Medicine* 12, no. 4: 4422–4427.