



LJMU Research Online

Islam, MN, Hosen, MMA, Sharmin, S, Salekin, MS, Naznin, A, Hossain, J, Rahman, HA, Nahar, L, Hossain, S and Uddin, MI

A Case Report on Avascular Necrosis of Right Femoral Head in a 20-years Old Male

<http://researchonline.ljmu.ac.uk/id/eprint/25076/>

Article

Citation (please note it is advisable to refer to the publisher's version if you intend to cite from this work)

Islam, MN, Hosen, MMA, Sharmin, S, Salekin, MS, Naznin, A, Hossain, J, Rahman, HA, Nahar, L, Hossain, S and Uddin, MI (2024) A Case Report on Avascular Necrosis of Right Femoral Head in a 20-years Old Male. SAS Journal of Surgerv. 10 (01). pp. 127-130.

LJMU has developed [LJMU Research Online](#) for users to access the research output of the University more effectively. Copyright © and Moral Rights for the papers on this site are retained by the individual authors and/or other copyright owners. Users may download and/or print one copy of any article(s) in LJMU Research Online to facilitate their private study or for non-commercial research. You may not engage in further distribution of the material or use it for any profit-making activities or any commercial gain.

The version presented here may differ from the published version or from the version of the record. Please see the repository URL above for details on accessing the published version and note that access may require a subscription.

For more information please contact researchonline@ljmu.ac.uk

<http://researchonline.ljmu.ac.uk/>

A Case Report on Avascular Necrosis of Right Femoral Head in a 20-years Old Male

Dr. Md. Nazmul Islam^{1*}, Dr. M M Arif Hosen², Dr. Samira Sharmin³, Dr. M Simoon Salekin⁴, Dr. Afroza Naznin⁵, Dr. Jamiul Hossain⁶, Dr. Hosne Ara Rahman⁷, Dr. Lutfun Nahar⁸, Safayet Hossain⁹, Mohammad Ikram Uddin¹⁰

¹Assistant Professor, Institute of Nuclear Medicine and Allied Sciences (INMAS), Cumilla, Bangladesh

²Associate Professor & Director, Institute of Nuclear Medicine and Allied Sciences (INMAS), Cumilla, Bangladesh

³Associate Professor, Institute of Nuclear Medicine and Allied Sciences (INMAS), Mitford, Bangladesh

⁴Assistant Professor & Director, Institute of Nuclear Medicine and Allied Sciences (INMAS), Satkhira, Bangladesh

⁵Assistant Professor, Institute of Nuclear Medicine and Allied Sciences (INMAS), Mitford, Bangladesh

⁶Associate Professor & Director, Institute of Nuclear Medicine and Allied Sciences (INMAS), Jashore, Bangladesh

⁷Professor & Director, Institute of Nuclear Medicine and Allied Sciences (INMAS), Mitford, Bangladesh

⁸Medical Officer, 300 Bed Hospital Khanpur, Narayanganj, Dhaka, Bangladesh

⁹B.Pharm, M.Pharm, North South University, Dhaka, Bangladesh

¹⁰Masters of Pharmacy, State University of Bangladesh

DOI: [10.36347/sasjs.2024.v10i01.022](https://doi.org/10.36347/sasjs.2024.v10i01.022)

Received: 13.12.2023 | Accepted: 22.01.2024 | Published: 29.01.2024

*Corresponding author: Dr. Md. Nazmul Islam

Assistant Professor, Institute of Nuclear Medicine and Allied Sciences (INMAS), Cumilla, Bangladesh

Abstract

Case Report

Avascular necrosis of the femoral head is a condition which causes cellular destruction of bone material due to interruption of blood supply. Necrosis is caused by inadequate blood supply, resulting in bone tissue destruction with collapsing of that segment. The disease usually occurs in young adults, and femoral head is one of the commonest sites. Avascular necrosis may be traumatic or non-traumatic and causes major musculoskeletal disability. Initially patients remain asymptomatic. In untreated cases the disease progresses and causes joint destruction, requiring surgical intervention and in later stages need total hip replacement. Plain X-ray, isotope bone scan and magnetic resonance imaging (MRI) play important role in making the diagnosis. MRI is highly accurate method for the diagnosis of avascular necrosis of the femoral head.

Keywords: Avascular necrosis, MRI, Tc99mMDP bone scan.

Copyright © 2024 The Author(s): This is an open-access article distributed under the terms of the Creative Commons Attribution 4.0 International License (CC BY-NC 4.0) which permits unrestricted use, distribution, and reproduction in any medium for non-commercial use provided the original author and source are credited.

INTRODUCTION

Avascular necrosis of the femoral head is also called osteonecrosis resulting from disruption of blood supply of the femoral head, leads to death (necrosis) of bone cells [2, 4]. Avascular necrosis may occur traumatically or non-traumatically. Non-traumatic avascular necrosis usually associated with alcohol abuse, autoimmune disease, corticosteroid abuse, hemoglobinopathies, and exposure to radiation or cytotoxic drugs. Treatment depends on stage of the disease. In advanced stage needs total hip replacement [4]. It is commonly seen in children and young adults. Males are more affected than females and bilateral avascular necrosis of the femoral head is found in upto 75% cases [1, 2]. Osteonecrosis of femoral head is characterized by severe pain, restricted motion in the hip and walking disability. Pain is aggravated by activity and relieved by rest. In about 80% of untreated cases the disease may progress to collapse of femoral head and

need surgical treatment. Prognosis of avascular necrosis depends on disease condition, complications and many other factors [1, 6]. Here we report a case of avascular necrosis of the right femoral head in a 20-years old male due to accidental injury of right hip joint.

CASE PRESENTATION

A 20 years old male presented with pain in right hip joint for last two years following accidental injury to right hip joint. Pain aggravated by walking and relieved by rest. Patient suddenly got trauma to his right hip joint during dancing in a program. Then he felt dull aching pain over his right groin which was initially moderate, constant, localized and non-radiating. He used to take analgesics to relieve the pain. The intensity of pain was gradually increasing and he could not perform full movement of his right lower limb at hip joint. With these complaints he consulted with physicians and took treatment in the form of analgesics. But his condition did

not improve and his daily activities were hampered. There was no history of numbness or paresthesia in his lower extremities and no evidence of bowel and bladder dysfunction. Range of movement of right hip was limited and painful in all ranges with most pain felt during adduction and internal rotation. There was evidence of muscle wasting. Plain X-ray of right hip joint shows sclerosis with articular marginal irregularity (Fig. 1). Tc99mMDP Bone Scintigraphy shows focal increased

radiotracer uptake in the head of the right femur, rest of the bone scan appears normal (Fig. 2). MRI shows avascular necrosis (stage IV) at right femoral head with surrounding marrow oedema and features of synovitis with mild effusion at right hip joint. No remarkable abnormality detected at MRI findings of left hip joint (Fig. 3). So finally patient was diagnosed as a case of avascular necrosis of right femoral head (stage IV).

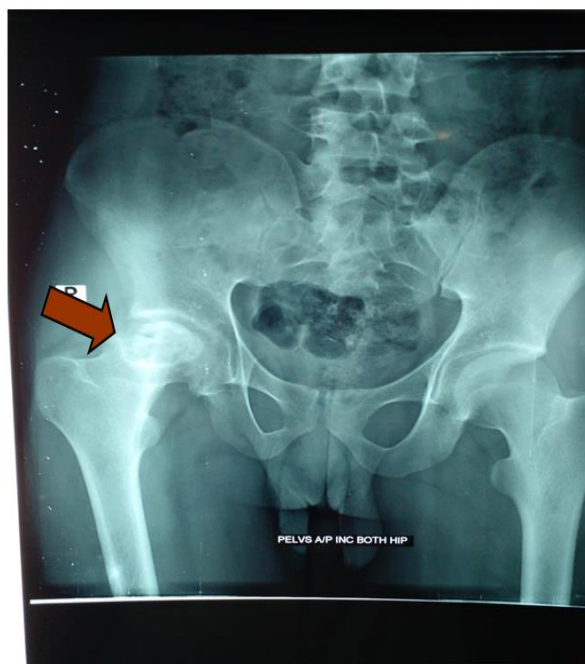


Fig. 1: Plain radiograph of hip joint showing sclerosis with articular marginal irregularity in right femoral head

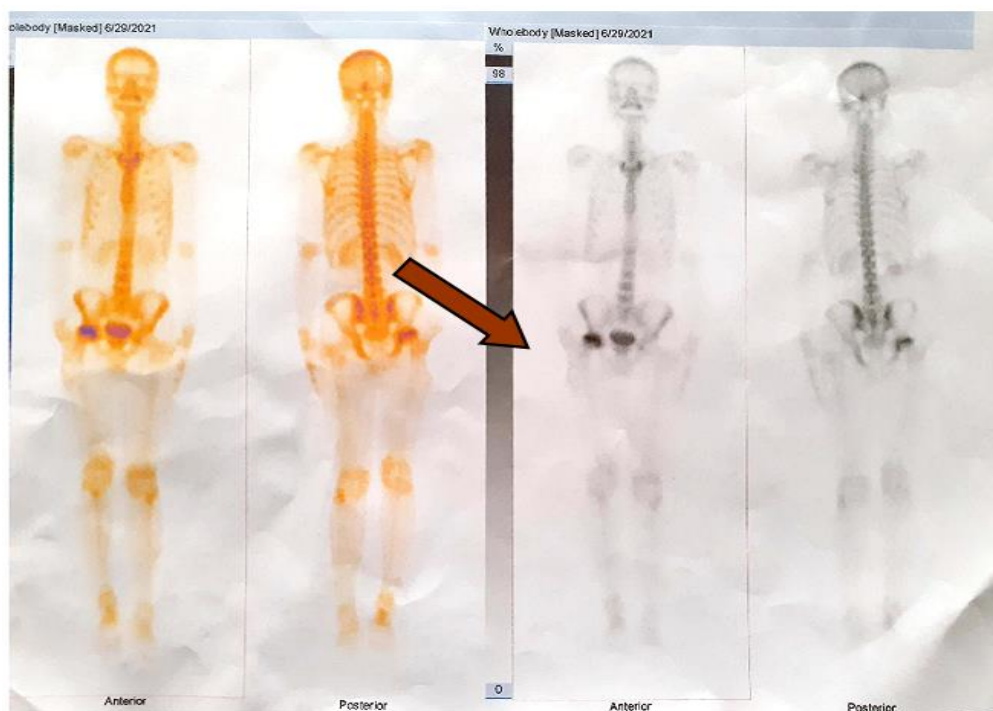


Fig. 2: Tc99m MDP Bone Scintigraphy shows focal increased radiotracer uptake at the head of right femur

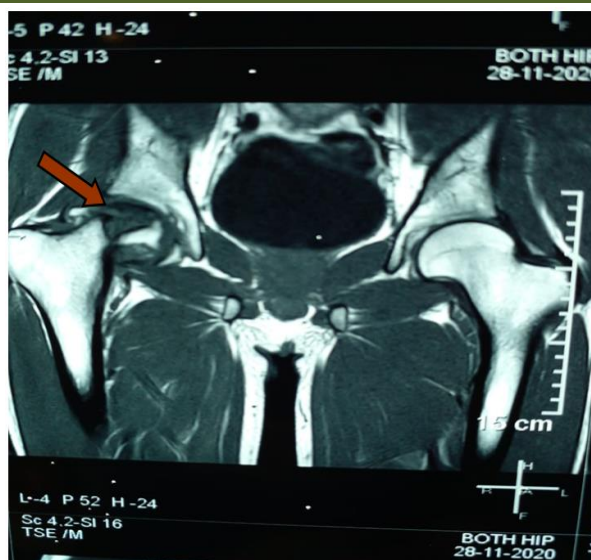


Fig. 3: MRI of hip joint showing avascular necrosis (stage iv) at right femoral head with surrounding marrow oedema and features of synovitis with mild effusion

DISCUSSION

Avascular necrosis is rare in extreme of age and 50% cases are bilateral. It is characterized by osseous cell death due to disruption of blood supply [3, 7]. Many changes take place following vascular compromise and

several causative factors may influence its development [3, 5]. The causative factors are considered to be multifactorial and associated in certain risk factors (table -1). In corticosteroid associated avascular necrosis of femoral head, hypercoagulability of vessels may decrease perfusion [5].

Table 1: Classification of risk factors for developing avascular necrosis of the femoral head

Traumatic factors:

Fracture of femoral neck and head, dislocation of the hip joint

Atraumatic factors:

Glucocorticoid use

Excessive alcohol intake

Coagulopathy (Antiphospholipid syndrome, Hyperlipidemia, Systemic lupus erythematosus)

Others (Caisson disease, Sickle cell disease, Gaucher disease, Smoking, Radiation)

Initial stages of non-traumatic type of avascular necrosis are difficult to diagnose because of no specific history. Causes of avascular necrosis can not be identified in about 25% of cases. Usually patient presents with hip, groin and knee pain with restricted joint movements. Symptoms are aggravated by weight bearing and relieved by rest. Patients may also have non-specific pain with gradual increase in its intensity [3, 7]. In avascular necrosis imaging is done to confirm a clinically suspected avascular necrosis in high-risk patients, for staging, for treatment purpose and to monitor treatment response. MRI is a highly accurate method for early diagnosis and for staging of the disease [2]. Usually, radiological features of avascular necrosis of femoral head involve collapse of articular cortex, fragmentation, mottled trabecular pattern, sclerosis, subchondral cyst and/or subchondral fracture [7]. Diagnosis may be delayed due to absence of positive findings on plain radiography for the first few months [3].

Arlet and Fi-cat have developed a staging system for avascular necrosis on radiograph:

Stage I: Shows normal radiographic findings.

Stage II: Shows femoral head osteoporosis with areas of cystic lucency and sclerosis

Stage III: Shows subchondral collapse (crescent sign)

Stage IV: Shows segmental progressive femoral head collapse with normal hip joint space and acetabulum

Stage V: Shows osteoarthritic changes with joint space narrowing (2).

Avascular necrosis of femoral head has got diagnostic and therapeutic challenge due to its effect on the afterwards disability. Physical disability that occurs in avascular necrosis needs immediate attention for management. The symptomatic treatment can make life comfortable but ultimately surgical treatment is needed. In delayed and chronic cases is ultimately hip replacement which is required [3, 7].

CONCLUSION

Avascular necrosis of femoral head involves a lot of morbidity with the passage of time. When a patient presents with hip pain due to trauma and/or corticosteroid use, the physician must consider avascular necrosis as a differential diagnosis. The diagnosis should be confirmed at the earliest possible time and both femoral heads should be examined. The diagnosis of avascular necrosis is confirmed by imaging methods. Though X-ray and MRI are the usual standard diagnostic tools, Tc99mMDP bone scintigraphy might also play a supporting role.

REFERENCES

- Gaurav, S., & Punam, S. (2016). Case Study of Avascular Necrosis of Femoral Head. *Joinsysmed*, 4(1), 46-50.
- Ansari, S., Dhungel, K., Ahmad, K., Gupta, M. K., Amanullah, M. F., & Rauniyar, R. K. (2012). Avascular Necrosis of the Femoral Head: A Case Report with Emphasis on Imaging Findings. *Nepalese Journal of Radiology*, 2(2), 92-95, <https://doi.org/10.3126/njr.v2i2.7694>
- Sharma, B. B., Sharma, S., Sandeep, S., Ramchandran, P., & Shweta, S. (2016). Spontaneous Avascular Necrosis of Bilateral Femoral Heads- Case Report. *J Med Diagn Meth*, 5, 226. doi: 10.4172/2168-9784.1000226
- Okan, O., Kerim, S., Mustafa, S., Ferhat, I., & Fatih, D. (2015). Bilateral avascular necrosis of the femoral head due to use of heroin: A case report. *International Journal of Surgery Case Reports*, 17, 100-102.
- Yutaka, K., Toshiyuki, K., Koji, G., & Shuichi, M. (2018). Bilateral osteonecrosis of the femoral head associated with corticosteroid therapy for alopecia areata: a case report and review of the literature. *Therapeutics and Clinical Risk Management*, 14, 1399-1405.
- Dharmshaktu, P., Aggarwal, A., Dutta, D., & Kulshreshtha, B. (2016). Bilateral femoral head avascular necrosis with a very low dose of oral corticosteroid used for panhypopituitarism. *Case Reports*, 2016, bcr2015212803. doi:10.1136/bcr-2015-212803
- Rahim, K., & Kambiz, D. G. (2004). Avascular necrosis of the hip in a 41 year old male: a case study. *JACC*, 48(2), 137-141.
- Mamuda, A. A., Iya, A. M., & Bello, B. (2017). Avascular Necrosis of Femoral Head in a 45 year Old Man: A Case Study of an Unnoticed Sickle Cell Disease Patient. *J Clin Med Case Report*, 4(1), 2.
- Vaidyanathan, S., Murugan, Y., & Paulraj, K. (2013). An unusual complication in osteonecrosis of femoral head: a case report. *Case Reports in Orthopedics*, 2013. <http://dx.doi.org/10.1155/2013/313289>
- Abdulkareem, I. H. (2013). Radiation induced femoral head necrosis. *Niger J Clin Pract*, 16, 123-6.