



Lipoic acid abates testis lead accumulation, sperm-endocrine deficits, testicular oxidative inflammation and apoptosis and modulates gene expression of Bax and Bcl-2 in rats

Ademola C. Famurewa^{a,b,*}, Hamida Hamdi^c, Azza Sedky^{d,e,**}

^a Department of Medical Biochemistry, Faculty of Basic Medical Sciences, College of Medical Sciences, Alex Ekwueme Federal University, Ndufu-Alike, Ikwo, Ebonyi State, Nigeria

^b Department of Pharmacology, Manipal College of Pharmaceutical Sciences, Manipal Academy of Higher Education, Manipal, Karnataka State, India

^c Department of Biology, College of Science, Taif University, Taif, 21944, Saudi Arabia

^d Department of Biological Sciences, College of Science, King Faisal University, Al-Ahsa, 31982, Saudi Arabia

^e Department of Zoology, Faculty of Science, Alexandria University, Alexandria, Egypt

ARTICLE INFO

Editor: DR B Gyampoh

Keywords:

Testis
Alpha-lipoic acid
Bioaccumulation
Toxicity
Inflammation
Apoptosis

ABSTRACT

The current study explored whether ALA could prevent testis Pb accumulation and Pb-induced oxidative testicular toxicity in rats. Adult male rats were randomly divided and administered ALA (25 mg/kg/day) and/or Pb (Pb acetate, 20 mg/kg/day) in Control group, ALA group, Pb group, and ALA + Pb group for 4 weeks consecutively. Pb exposure significantly increased Pb accumulation in the testes and blood of Pb-exposed rats compared to the control. Pb caused marked deficits in sperm count, motility along with elevated abnormal sperm cells, while serum testosterone, follicle stimulating hormone (FSH) and leutenizing hormone (LH) levels reduced prominently in comparison to the control. It remarkably depressed the testicular activities of catalase (CAT), glutathione peroxidase (GPx), superoxide dismutase (SOD), as well as levels of interleukin-4 (IL-4) and interleukin-10 (IL-10), whereas malondialdehyde (MDA), tumor necrosis factor-alpha (TNF- α), and interleukin-6 (IL-6) increased significantly compared to the control. The levels of caspase-3, capsase-9, and the PCR gene expression of Bax and Bcl2 were adversely altered with alterations in testis histology. Interestingly, the co-treatment with ALA blocks Pb accumulation in the testis and blood. It inhibited the Pb-induced alterations in reproductive indices and reversed the oxidative stress-mediated inflammatory stress, apoptotic signaling and histopathological abrasions. The findings reveal that ALA could abrogate Pb-induced testicular toxicity through blocking testicular oxidative inflammation and apoptosis in rats.

Introduction

Lead (Pb) is a non-biodegradable non-essential environmental toxicant that elicits a wide spectrum of biological defects [1]. The

* Corresponding author at: Department of Medical Biochemistry, Faculty of Basic Medical, Sciences, College of Medical Sciences, Alex-Ekwueme Federal University, Ndufu-Alike, Ikwo, Ebonyi State, Nigeria.

** Corresponding author at: Department of Biological Sciences, College of Science, King Faisal University, Al-Ahsa, 31982, Saudi Arabia.

E-mail addresses: ademola.famurewa@funai.edu.ng (A.C. Famurewa), asadek@kfu.edu.sa (A. Sedky).

<https://doi.org/10.1016/j.sciaf.2023.e01842>

Received 2 June 2023; Received in revised form 29 July 2023; Accepted 2 August 2023

Available online 5 August 2023

2468-2276/© 2023 The Authors. Published by Elsevier B.V. This is an open access article under the CC BY-NC-ND license (<http://creativecommons.org/licenses/by-nc-nd/4.0/>).

ubiquity and exposure to Pb are a serious public health concern of global dimension [2]. Recently, the WHO and the Agency for Toxic Substances and Disease Registry (ATSDR) have classified Pb as one of the top 10 most dangerous substances for public health [3]. Despite the ban of Pb use in many products, Pb is still a persistent component of children toys, polluted waters, gasoline, batteries, paints, food cans, water pipes, conventional folk medications, cigarette smoke, and ceramics [1,4,5]. However, contaminated food, water, and air pollution are the major sources of Pb exposure and toxicity [6]. Renal excretion of Pb is very difficult; hence, it accumulates in bones and delicate soft tissues for a long time causing various organ toxicity and pathologies by multiple mechanisms, including epigenetic alterations [6,7]. The adverse health effects of Pb, including death, insanity, nervous system damage and infertility have been reported since the second century BC. Even low Pb exposure affects children's intellectual development and lifetime achievement [8]. Importantly, the male reproductive system is particularly sensitive to Pb accumulation which results in testicular-endocrine toxicity. Testicular Pb triggers impaired endocrine spermatogenesis and steroidogenesis, and causes degenerated germ cells leading to low sperm quality and infertility [2,9].

Literature reveals the mechanisms underlying Pb-induced testicular toxicity [4,9]. However, the hallmark mechanism is oxidative stress ensuing from Pb-mediated generation of reactive oxygen species (ROS) and deactivation of sulfhydryl group in glutathione homeostasis, antioxidant enzymes and proteins [2,7,10]. This oxidative behavior of Pb results in suppression of antioxidant mechanism and redox imbalance leading to oxidative stress. In addition, Pb-induced oxidative stress has been associated with pro-inflammatory cascades and apoptosis signaling in considerable number of published papers. Studies indicate that Pb causes oxidative inflammation, apoptosis and sperm mitochondrial impairment in various animal models [1,5,7,9]. It thus appears from the earlier findings that antioxidant modulators may play a critical role in Pb toxicity possibly via upregulation of antioxidant milieu.

Alpha-lipoic acid (ALA) is a potent natural antioxidant compound found in cell membranes, cytoplasm, mitochondria and extra-cellular spaces of plants and animals [11]. It is a fatty acid also known as thioctic acid readily synthesized within the cells of the liver, heart, and testis to supplement the insufficient amount in the human diet [4,12]. It is naturally found in plant such as spinach, broccoli, and tomato [13]. ALA is a cellular coenzyme for the mitochondrial dehydrogenases involved in several metabolic activities. ALA or its reduced form, dihydrolipoic acid, is amphipathic in nature and thus exerts antioxidant effect both in hydrophilic and lipophilic environments [14,15]. In cells, ALA reduces the oxidized disulphide group to sulfhydryl groups with NADPH-dependent reductase; it chelates metals thus inhibiting hydroxyl radical production and acts as a scavenger of ROS and nitrogen species [12]. ALA is an antioxidant and anti-inflammatory dietary supplement [16]. The pharmacological effects of ALA indicate its potential to alleviate diabetic retinopathy [14], arsenic neurotoxicity [15], arsenic hepatotoxicity [11] and inhibition of oxidative stress-mediated organ toxicity induced by anticancer drug methotrexate [16,17]. In clinical studies, the anti-inflammatory effect of ALA decreases tumor necrosis factor- α , C-reactive protein, and interleukin-6. [13]. ALA modulates its anti-inflammatory effect via intracellular inhibition of nuclear factor κ B (NF- κ B) signaling and blockage of various gene expressions that orchestrate cell apoptosis and inflammatory responses [13]. ALA enhances sperm characteristics in infertile men and animal models [18,19]. The therapeutic effects of ALA are associated with its antioxidant and anti-inflammatory properties. However, there is a paucity of findings on the role of ALA in heavy metal toxicity. Therefore, our study was designed to evaluate the possible protective effect of ALA on Pb-induced testicular and endocrine toxicity via assessing sperm quality, endocrine disruption, oxidative stress, pro-inflammation and apoptosis in rats.

Materials and methods

Chemicals

Lead acetate and α -lipoic acid were purchased from Sigma Aldrich Chemicals, St Louis, MO, USA. Commercial kits were purchased from Biodiagnostics, Cairo, Egypt and Jiancheng Co. (Nanjing, China).

Animals

Twenty-four adult male rats weighing 180–200 g (9–10 weeks old) were purchased from the Animal House of the Faculty of Science, King Faisal University, Saudi Arabia. The experimental protocol of this investigation was approved by the Institutional Animal Care and Use Committee (IACUC) at King Faisal University with reference number: KFUC-REC-2023-FEB-ETHICS540. The rats were housed in Building 9 of the Faculty of Science, King Faisal University, Saudi Arabia. They were housed in plastic cages (6 per cage), floored with soft wood shavings that was changed three times per week. The animals were acclimatized for 2 weeks prior the study and were maintained under a 12 h light/dark cycle at (25 °C \pm 2 °C), with free access to water ad libitum.

Experimental design

Animals were randomly divided into four groups, six animals each, as follows:

Group 1 (Control): Rats received daily injection (i.p) of normal saline (0.9% Na Cl) as vehicle for 4 weeks

Group 2 (ALA): Rats received daily oral administration of ALA (25 mg/kg b.w/day) for 4 weeks. The dose of ALA was dissolved in 2 ml/kg (body weight) corn oil.

Group 3 (Pb): Rats received daily injection (i.p) of lead acetate dissolved in normal saline at a dose of 20 mg/kg b.w/day for 4 weeks

Group 4 (ALA + Pb): Rats received daily oral administration of ALA (25 mg/kg b.w/day) for 4 weeks + injection (i.p) of lead acetate dissolved in normal saline at a dose of 20 mg/kg b.w/day for 4 weeks.

Table 1
Primer sequence for housekeeping and target genes.

Target gene	Forward primer 5'–3'	Reverse primer 5'–3'
Bax	AAGCTGAGCGAGTGTCTCCGGCG	GCCACAAAGATGGTCACTGTCTGCC
Bcl2	CTCGTCCGTACCGTCGTACTTCG	CAGATCCGGTTCAGGTACTCAGTC
β -actin	TCCATCGTCCACCCAAATG	CAGGAGACCAAAAGCCTTCATAC

The Pb acetate dose and ALA dose used in the current study were adopted from the previous studies [20,21]. At the end of the 4-week experimental period, the rats were euthanized, sacrificed, and samples of blood and testis tissues were collected. The animals were euthanized by anesthetic exsanguination using the combination of 10 mg/kg xylazine and 100 mg/kg ketamine HCl. Whole blood samples were collected in clean dry centrifuge tubes, containing no anticoagulation factors and allowed to clot for a minimum of 30 min at 37 °C before centrifuged to obtain serum (769 × g for 15 min) and stored at –20 °C until the analysis. The testes were homogenized (1: 5 w/v) with a Potter-Elvehjem homogenizer attached to a Teflon plunger in ice. Testis supernatant samples were collected and stored at –20 °C until the time of biochemical analyses. Tissue samples were also used for histological studies.

Biochemical analyses

Pb estimation in serum and testis

Pb levels were estimated by spectrometric method [22]. Briefly, the supernatant and serum sample (1.0 mL) were placed in glass tube for acid digestion. To each, 2.0 mL of concentrated nitric acid was added and left for 20 hrs for sample digestion at room temperature. Perchloric acid (72%) was added (0.5 mL) and heated to 100 °C for 3 hrs. Digestion was allowed to continue for further 4 hrs before the addition of deionized water to the residue to a marked volume of 3.0 mL. A portion was heated to dryness in a crucible and the residue was dissolved in deionized water. Pb analysis was carried out using Atomic Absorption Spectrometry (AAS) using an EA3 furnace attachment.

Determination of serum reproductive hormones

Serum levels of reproductive hormones, testosterone (T), luteinizing hormone (LH), and follicle stimulating hormone (FSH) were determined. T was determined as previously reported using a T ELISA kit (Cat No: KT-29533) [23]. The level of LH was determined according to the method in Shibayagi's rat LH ELISA kit (Cat No: KT-29572), while FSH levels were estimated following the method described in rat FSH ELISA kit (Cat No: KT-29542). These kits were purchased from Biodiagnostics, Cairo, Egypt.

Assessment of sperm count, motility, and abnormality

Percentage of motility, sperm abnormality and sperm count were evaluated microscopically using the standard methods in our previous study [23] with the use of sperm suspension from testis epididymis.

Determination of oxidative stress markers

Testicular activities of antioxidant enzymes, catalase (CAT, Cat No: CA2516), superoxide dismutase (SOD, Cat No: SD2520), and glutathione peroxidase (GPx, Cat No: GP2524) and malondialdehyde level (MDA, Cat No: MD2528) were analysed in homogenate supernatant using commercial rat ELISA kits. The protein content of the testis was determined by a standard method [24].

Determination of testicular pro-inflammation and antiinflammation

The levels of pro-inflammatory cytokines, tumor necrosis factor- α (TNF- α , Cat No R019) and interleukin-6 (IL-6, Cat No R016) and anti-inflammatory cytokines, interleukin-4 (IL-4, Cat No R013) and interleukin-10 (IL-10, Cat No R017) were assessed in the supernatant of testis using rat standard ELISA kits.

Determination of apoptotic caspase activity

Testicular caspase 3 (Cat No: A064) and caspase 9 (Cat No: A069) were determined with rat ELISA kits following the manufacturer's directions.

RNA isolation and real-time PCR

Real-time PCR was conducted for mRNA transcript levels of proapoptotic Bax and antiapoptotic Bcl2 genes. Total RNA of the testis was extracted with the use of TRizol reagent (Invitrogen, Life Technologies) as previously described [25]. Total RNA was reverse transcribed at 37 °C for 1 hour with the use of oligo(dT) primer and reverse transcriptase (Superscript Life Technologies). cDNA was amplified with Taq DNA polymerase (AmpliTaq, Perkin-Elmer) by RT PCR for 35 cycles (94 °C for 1 min, 64 °C for 1 min, 72 °C for 1 min) (Bio-Rad CFX384). Δ Ct method was used to normalize the changes in the expression of the target gene relative to the mean cycle threshold (C_T) values of the housekeeping gene, β -actin. Primers used for the RT PCR are listed in Table 1.

Table 2
Effect of ALA on Pb levels in serum and testis in Pb-exposed rats.

Group	Serum Pb ($\mu\text{g/ml}$)	Testis Pb ($\mu\text{g/g}$ tissue)
Control	0.11 \pm 0.02	0.11 \pm 0.01
ALA	0.12 \pm 0.01	0.10 \pm 0.01
Pb	5.43 \pm 0.03*	3.41 \pm 0.06*
ALA + Pb	3.10 \pm 0.01 [#]	1.76 \pm 0.02 [#]

Data were displayed as mean \pm SEM ($n = 6$ rats/group). ALA: alpha-lipoic acid; Pb: Lead metal; * $p < 0.05$: significant when compared to control group in the same column. [#] $p < 0.05$: significant when compared to Pb group in the same column.

Table 3
Effect of ALA on testicular activities of SOD, CAT, GPx (U/mg protein) and MDA (nmol/g tissue) in Pb-exposed rats.

Group	SOD	CAT	GPx	MDA
Control	72.74 \pm 2.20	65.74 \pm 2.35	56.70 \pm 3.30	12.72 \pm 0.29
ALA	76.05 \pm 3.32	64.80 \pm 1.27	55.60 \pm 1.29	13.02 \pm 1.16
Pb	47.20 \pm 2.37*	41.01 \pm 2.45*	34.80 \pm 2.24*	34.70 \pm 1.10*
ALA + Pb	56.20 \pm 3.37 [#]	56.02 \pm 3.17 [#]	44.86 \pm 0.21 [#]	27.58 \pm 0.38 [#]

Data were displayed as mean \pm SEM ($n = 6$ rats/group). ALA: alpha-lipoic acid; Pb: Lead metal; * $p < 0.05$: significant when compared to control group in the same column. [#] $p < 0.05$: significant when compared to Pb group in the same column.

Table 4
Effect of ALA on sperm parameters in Pb-exposed rats.

Group	Sperm parameters		
	Sperm count (10^6 cells/ml)	Sperm motility (%)	Sperm abnormality (%)
Control	85.41 \pm 3.18	83.48 \pm 4.81	8.15 \pm 1.38
ALA	85.25 \pm 2.95	85.21 \pm 3.58	8.29 \pm 1.44
Pb	60.42 \pm 1.99*	56.20 \pm 1.98*	25.11 \pm 1.11*
ALA + Pb	75.03 \pm 2.09 [#]	72.61 \pm 3.78 [#]	15.88 \pm 2.17 [#]

Data were displayed as mean \pm SEM ($n = 6$ rats/group). ALA: alpha-lipoic acid; Pb: Lead metal; * $p < 0.05$: significant when compared to control group in the same column. [#] $p < 0.05$: significant when compared to Pb group in the same column.

Testicular histopathological analysis

Testis tissue samples were removed and immediately fixed in 10% buffered formalin. Dehydration was carried out with graded ethanol and embedded in paraffin. Testis sections were stained with haematoxylin and eosin (H and E) for microscopic histopathological lesions. The prepared slides were examined under light microscope. Testicular lesions were semi-quantitatively graded as follows: 0: intact histoarchitecture (normal), 1: mild lesions, 2: moderate lesions, and 3: severe damage [23].

Statistical analyses

The GraphPad prism statistical software package (version 8; GraphPad Software Inc., San Diego, CA, USA) was used for analyses. Data were compared using one-way ANOVA followed by LSD multiple range test. Significant differences were obtained at $P < 0.05$. The data were represented as mean \pm SEM ($n = 6$).

Results

Effect of ALA on Pb levels in serum and testis

Table 2 shows the effect of ALA on levels of Pb in the serum and testis of rats in this study. Pb significantly accumulated and levels elevated in the serum and testis tissue of rats in Pb group compared to the Pb levels in control rats. We observed that the Pb accumulation in the blood was higher than that of testis. However, the co-treatment with ALA in ALA + Pb group caused a marked decrease in Pb levels in the serum and testis of rats compared to the Pb group ($p < 0.05$).

Effect of ALA on testicular oxidative stress

Table 3 depicts the effect of ALA and Pb exposure on testicular activities of SOD, CAT, GPx and levels of MDA in Pb-exposed rats. We found that Pb profoundly depressed the activities of SOD, CAT, GPx, while MDA level markedly increased in Pb group compared to the

Table 5
Effect of ALA and Pb on serum levels of T, LH and FSH in Pb-exposed rats.

Group	T (pg/ml)	LH (pg/ml)	FSH (pg/ml)
Control	7.52 ± 0.12	2.50 ± 0.05	0.97 ± 0.01
ALA	7.32 ± 0.09	2.51 ± 0.01	0.99 ± 0.01
Pb	3.71 ± 0.01*	0.99 ± 0.02*	0.36 ± 0.01*
ALA + Pb	5.28 ± 0.06 [#]	1.40 ± 0.02 [#]	0.57 ± 0.01 [#]

Data were displayed as mean ± SEM ($n = 6$ rats/group). ALA: alpha-lipoic acid; Pb: Lead metal; * $p < 0.05$: significant when compared to control group in the same column. [#] $p < 0.05$: significant when compared to Pb group in the same column.

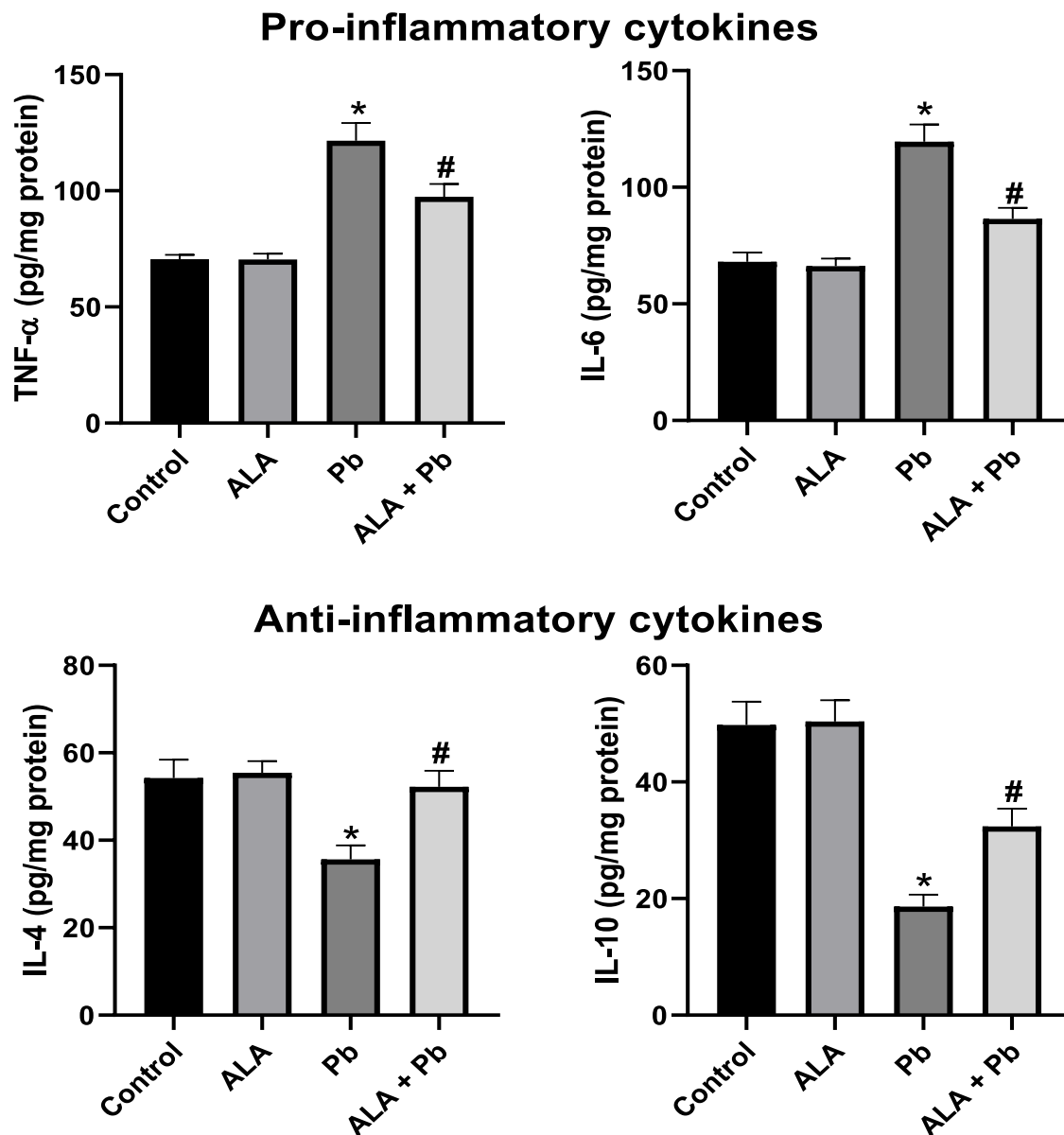


Fig. 1. Effect of ALA and Pb exposure on testicular levels of pro-inflammatory cytokines (TNF- α and IL-6) and anti-inflammatory cytokines (IL-4 and IL-10) in Pb-exposed rats. Data were displayed as mean ± SEM ($n = 6$ rats/group). ALA: alpha-lipoic acid; Pb: Lead metal; * $p < 0.05$: significant when compared to control group. [#] $p < 0.05$: significant when compared to Pb group.

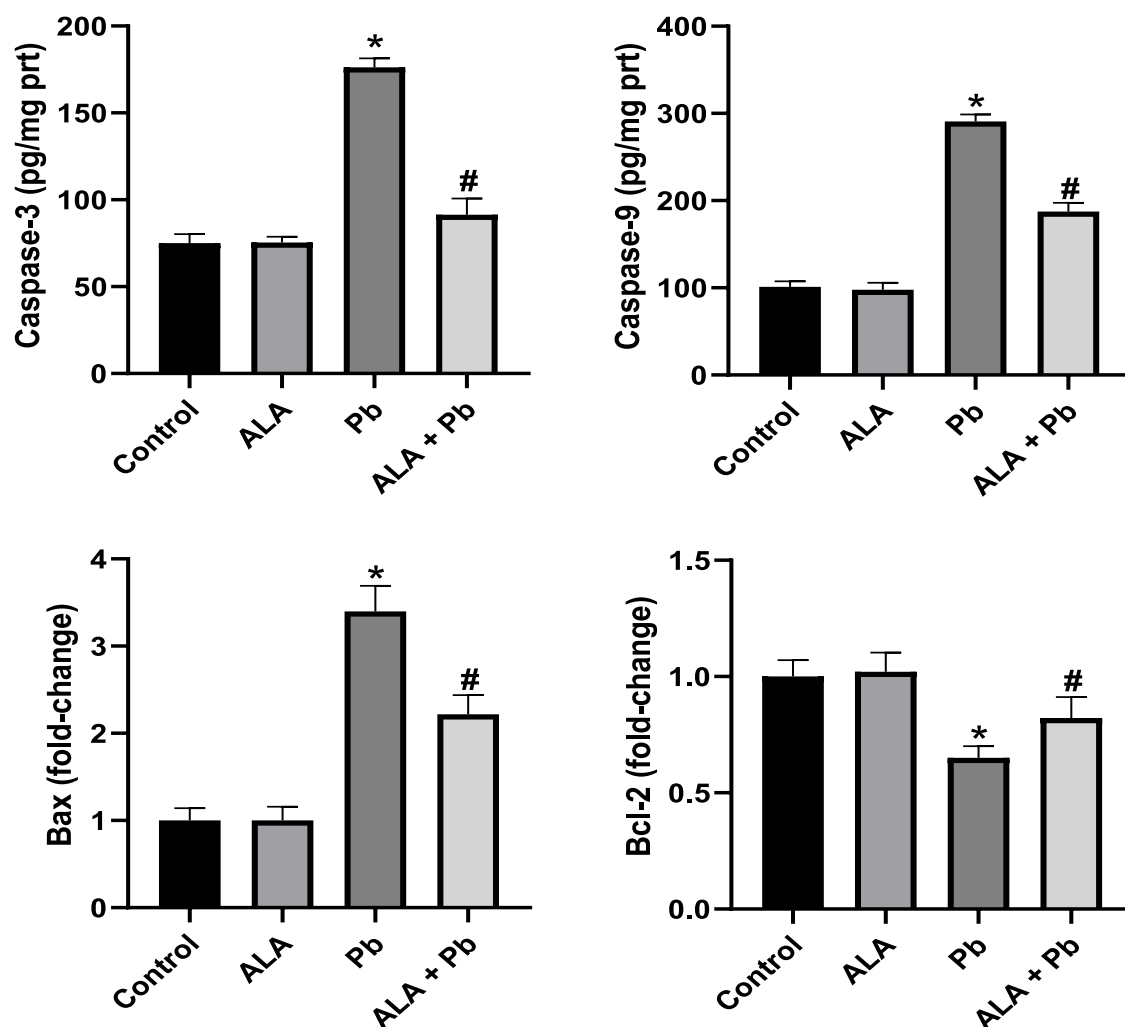


Fig. 2. Effect of ALA and Pb exposure on testicular levels of caspase 3/–9 and gene expression of Bax and Bcl-2 mRNA relative expression to β -actin assessed by RT-PCR in Pb-exposed rats. Data were displayed as mean \pm SEM ($n = 6$ rats/group). ALA: alpha-lipoic acid; Pb: Lead metal; * $p < 0.05$: significant when compared to control group. # $p < 0.05$: significant when compared to Pb group.

control group ($p < 0.05$). Conversely, ALA significantly enhanced the enzyme activities and reduced the MDA levels in ALA + Pb group compared to the Pb group ($p < 0.05$).

Effect of ALA on sperm parameters

Table 4 presents the effect of ALA and Pb on sperm count, motility and abnormality in Pb-exposed rats. Pb exposure exerted considerable reduction in the number of sperm count and motile sperm cells compared to the control. In addition, the number of abnormal sperm cells were markedly elevated compared to the control ($p < 0.05$). However, the administration of ALA to the Pb-exposed rats significantly enhanced the count, mobility and abnormality of sperm cells in comparison to the Pb group in this study ($p < 0.05$).

Effect of ALA on serum T, LH and FSH

Table 5 shows the effect of ALA and Pb on serum levels of reproductive hormones (T, LH and FSH) in rats exposed to Pb. Pb exposure in Pb group induced considerable decreases in serum levels of T, LH and FSH in comparison to the control ($p < 0.05$) in this study. Interestingly, ALA effect significantly increased the levels of these hormones in ALA + Pb group compared to the Pb group ($p < 0.05$).

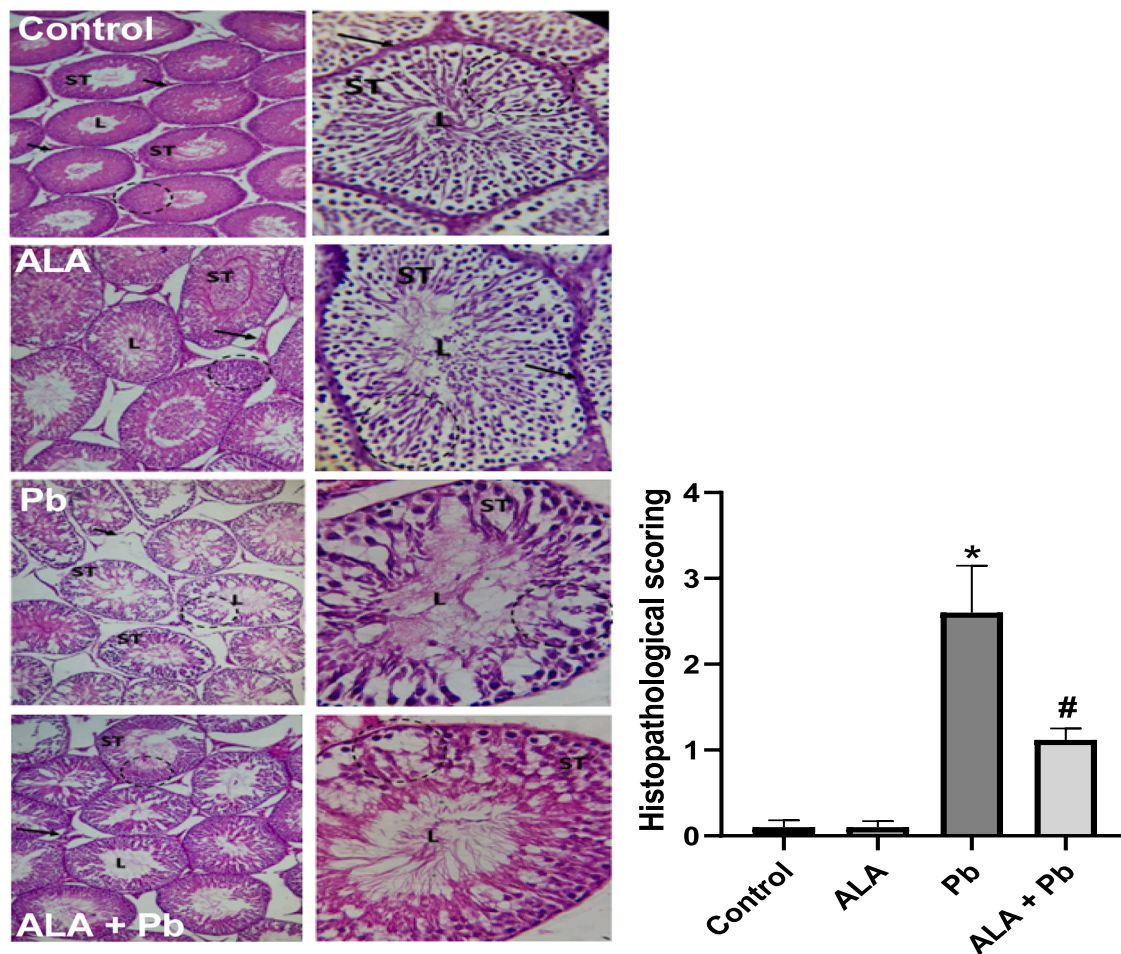


Fig. 3. Photomicrographs of rat testis administered ALA and Pb (H&E stain). Control or ALA group show normal seminiferous tubules (ST), interstitial tissue (arrow) and lumen (L). The Pb group revealed distorted tubules (ST), lumen with reduced number of spermatozoa (L), degenerated germinal epithelium (dash circle). ALA + Pb group showed mildly damaged seminiferous tubules (ST) and restoration of spermatogenesis with more spermatozoa in the lumen (L). Values are expressed as mean \pm SEM ($n = 4$). *Significant when compared to the control ($P < 0.05$); #significant compared to the Pb group.

Effect of ALA on testicular proinflammation and antiinflammation

Fig. 1 presents the effect of ALA and Pb exposure on testicular levels of pro-inflammatory cytokines (TNF- α and IL-6) and anti-inflammatory cytokines (IL-4 and IL-10) in Pb-exposed rats. We found that Pb profoundly increased the testicular levels of TNF- α and IL-6, while IL-4 and IL-10 levels decreased in comparison to the control ($p < 0.05$). In contrast, ALA significantly prevented the cytokine alterations in ALA + Pb group compared to the Pb group ($p < 0.05$).

Effect of ALA on testicular apoptosis

Fig. 2 depicts the effect of ALA and Pb on testicular caspase-3/-9, and gene expression for Bax and Bcl-2 in Pb-exposed rats. Pb significantly increased the levels of caspase-3, -9 and Bax gene expression, whereas the Bcl-2 gene expression was markedly diminished compared to the control ($p < 0.05$). On the contrary, ALA significantly inhibited the testicular apoptosis demonstrated by considerable reduction in the levels of caspase-3, -9 and Bax followed by increased expression of Bcl-2 compared to the Pb group.

Effect of ALA on testicular histopathology

Fig. 3 represents the microscopic observations of the effect of ALA and Pb on testis histology. In the **control** and **ALA** groups, there were well-preserved seminiferous tubules (ST) separated by interstitial tissue (arrow). Each seminiferous tubule was lined with multiple layers of spermatogenic epithelium. The lumina of seminiferous tubules were occupied by the spermatozoa. In the **Pb** group, Pb caused abnormalities in the testicular architecture presented by widespread degenerative changes appeared as deformities of

seminiferous tubules. There were larger spaces, degenerated germinal epithelium (dash circle) with reduced number of spermatozoa in the tubular lumen (L). ALA + Pb group showed some noticeable recovery with respect to seminiferous tubules which are closer to one another with enhanced spermatogenesis and spermatozoa in the tubular lumen (L).

Discussion

Pb is a toxic non-essential heavy metal mainly absorbed through the skin, digestive and respiratory systems [26]. Robust body of evidence has shown that Pb is a multi-organ toxicant, including the testis, and even partakes in the pathophysiology of chronic diseases [8]. The ubiquitous dispersion and human application of Pb suggest that its human exposure may be unavoidable. It triggers redox imbalance implicated to culminate into inflammatory and apoptotic cascades. Therefore, bioactive compounds, such as ALA, may inhibit redox imbalance and thus offer beneficial health effects against Pb toxicity. Our study herein reveals the reproductive effect of ALA against Pb-induced testicular toxicity and endocrine deficits in a rat model.

In the current study, it was observed that Pb bio-accumulated in the testis and blood of the rats. In Pb group, the testicular and blood Pb levels were evidently higher compared to the control group (Table 2). However, the accumulation of Pb was higher in the blood compared to the testis. This observation was due to the Pb exposure for 28 days in the current study. Previous studies show that Pb stores in the kidney, liver, testis, brain and other delicate organs [4,6,27]. Pb enters the human body via contaminated food, water or inhalation of polluted dust and fumes and penetrates the GIT to accumulate in the blood circulation and tissues [5]. Pb affinity for proteins and capacity to mimic Ca^{2+} and Fe^{2+} channels could enhance the deposition of Pb in the blood and testis as observed in this study [28]. The deposition via mimicry would undoubtedly incite intracellular behavior that could be responsible for the hallmarks of testicular toxicity and endocrine deficits found herein. Our findings are consistent with the earlier reports indicating the Pb accumulation in the blood and testis [4,29]. On the contrary, ALA co-administration with Pb to rats inhibited Pb testicular and blood accumulation. The Pb levels in the blood and testis were considerably reduced in the co-administration group in this study. The mechanism by which ALA could inhibit Pb is yet to be delineated. However, earlier studies indicate metal-chelating property of ALA [4, 12]. Till date, chelation therapy is the most effective strategy available to manage the toxicity of metals; however, some issues of toxicity and patient's quality of life persist. In fact, it has been reported that chelators of Pb not only exert undesirable side effects but also demonstrate low effectiveness [6]. Conceivably, ALA could have reduced the Pb levels via chelation processes which may result in amelioration of Pb toxicity in the testis.

Literature suggests that Pb is a classic inducer of organ toxicity via oxidative stress-mediated mechanisms [7,30]. It causes impairment in redox homeostasis via disruption of oxidant/antioxidant equilibrium and elevated generation of ROS. The consequent result of Pb oxidative behavior is depressed tissue antioxidant apparatus and oxidative stress status according to the published papers [2,5,10]. In consistent with the literature reports, we found that Pb significantly depressed the testicular activities of SOD, CAT, and GPx along with marked increases in MDA levels which suggest Pb-mediated oxidative stress (Table 3). In corollary, oxidative distortion of the testis histology in seminiferous tubules was also found. Testis is unusually sensitive to Pb and its oxidative stress mediations due to its high polyunsaturated fatty acid content making it more vulnerable to oxidative damage [10,31]. Although Pb is not a Fenton reaction heavy metal; however, it can induce oxidative stress via indirect elevation of free Fe which is a Fenton reaction metal for generation of various free radicals. Pb could displace calcium (Ca^{2+}), copper (Cu^{2+}) and zinc (Zn^{2+}) which are membrane signal transducers or cofactors for antioxidant enzymes, from their physiological roles, thus, enhancing ROS production *de novo* [10]. The Pb-induced oxidative distress in the testis could trigger lipid peroxidation and degeneration of the germinal epithelium leading to testicular dysfunction and DNA damage. Consequently, the effect of the oxidative abrasions in the testicular germinal epithelium was also observed in our histology findings. Interestingly, a number of studies report similar oxidative behavior of Pb in the testis of animal models in consistent with our findings [2,32,33]. According to the literature, antioxidant effect of ALA is essentially reported against pathologies and toxicity. ALA and its reduced form, dihydrolipoic acid, are potent inhibitors of hydroxyl radical production and rapid scavengers of ROS and RNS [12]. Intracellularly, ALA is converted to its reduced form and thus reduce superoxide anion radical, regenerate endogenous antioxidants, like glutathione, ascorbic acid, and alpha-tocopherol and ameliorates oxidative injuries [13,14]. Herein also, the ALA antioxidant potency was demonstrated via notable elevation of testicular SOD, CAT and GPx activities and the resultant diminution of MDA level in rats' group of ALA + Pb. Studies have reported antioxidant activity of ALA against diabetic retinopathy, inflammation-related human diseases, renal sepsis, acute kidney injury, [13,14,34]. Antioxidant ALA has been shown to mitigate oxidative stress against toxicity in the testis, liver, and brain in agreement with our findings [16,17,20]. However, the prevailing mechanism of ALA antioxidant action is its ability to interact with oxidized disulphide linkage (GSSG) and reduces it to sulfhydryl groups through NADPH-dependent reductase, and also by inducing the expression of antioxidant genes [12,35]. Therefore, it could be sufficiently suggested that, the antioxidant effect of ALA is associated with the scavenging of ROS and upregulation of antioxidant machinery against the Pb-mediated redox deficit in the testis of rats.

Pb is a reproductive toxicant that provokes oxidative testicular degeneration, spermatogenesis arrest and dysregulation of steroidogenesis [21]. Studies show that Pb can cause testicular damage, hormonal imbalance, and elevated sperm alterations manifested via reduction in sperm count and motility, and elevated sperm abnormality that may culminate in infertility [31,36]. In our study herein, we found that Pb exposure triggered endocrine deficit with lowered T, FSH and LH in the serum of rats compared to the control (Table 5). These endocrine diminutions concomitantly produced significantly reduced sperm count, motility, followed by increased sperm abnormality in this study (Table 4) [29]. The histopathological assessment indicated damaged seminiferous tubules and reduced number of sperm cells in the tubular lumen, as earlier reported [37]. The reduction in sperm count could be associated with reduced spermatogenesis which could be ascribed to reduction in serum T level as observed in this study [23]. The oxidative mutilation of the cell membrane via lipid peroxidation could have instigated the lowered motility and aggravated abnormalities [23,31]. Large base of

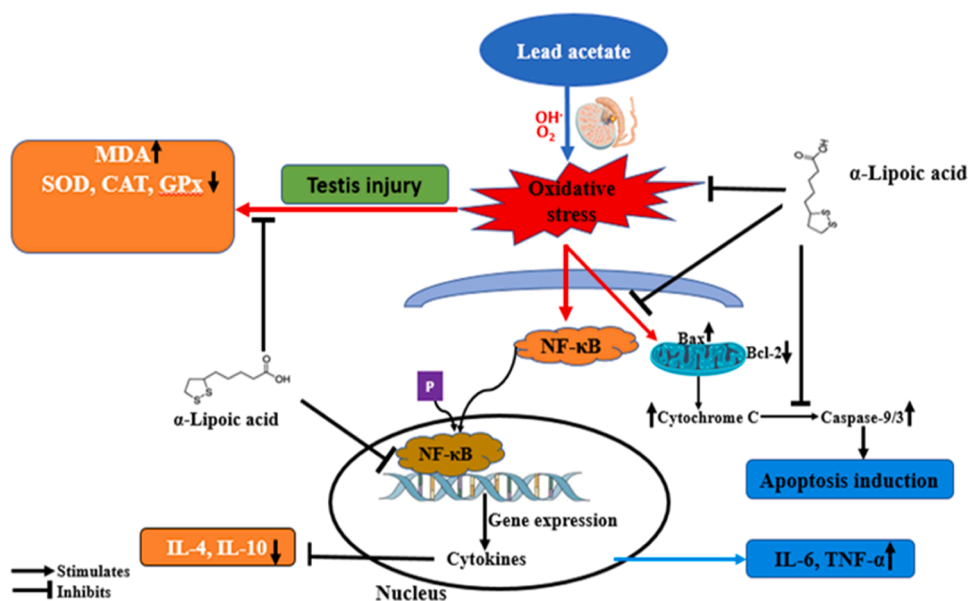


Fig. 4. Schematic presentation of the possible mechanisms underlying the protective effect of α -lipoic acid (ALA) against Pb-induced testicular injury.

studies indicate that testicular toxicity impairs reproductive apparatus and increases the risk of infertility [36]. For example, busulfan, an antineoplastic drug, exerts testicular toxicity which leads to alterations in testicular ultrastructure, reduced number of Sertoli and Leydig cells coupled with depressed levels of T, LH and FSH [38]. Pb induces damage in sperm indices and reduces Leydig cell function in male mice [2]. Chiefly, oxidative deterioration leading to deranged steroidogenesis and spermatogenesis has been well documented in the existing literature [32,38]. There is evidence that Pb declines the number of Sertoli cells that support spermatogenesis [32] and diminishes the steroidogenic capacity of the testes, lowering circulating testosterone levels [36]. Therefore, our findings and that of earlier researchers point to the deleterious effects of Pb on steroidogenesis and spermatogenesis in the testis of rats. However, the ALA co-administration reversed the Pb-mediated derangements and restored the reproductive indices comparable to the control. Our findings follow previous reports that ALA has a protective role against testicular toxicity and endocrine dysfunction [39,40].

Oxidative Pb toxicity in the testis is consistent with proinflammation and apoptotic signaling in various organs [1,6,7,27]. Increased level of ROS is strongly implicated in inflammatory cytokine gene expression and activation of caspases leading to apoptosis [41]. The pathologic crosstalk of oxidative inflammation and apoptosis has been reported in preclinical Pb-induced testicular toxicity. We therefore considered and assayed for pro-inflammatory and anti-inflammatory cytokines in this study. In the testis, Pb prominently increased the levels of TNF- α and IL-6, whereas the levels of IL-4 and IL-10, which are well-known anti-inflammatory cytokines, were markedly decreased (Fig. 1). The results show that Pb provokes testicular pro-inflammatory cascades corroborating earlier findings [29,27]. The oxidative milieu created by Pb herein could activate redox-sensitive transcription factors, including nuclear factor-kappa B (NF- κ B), which translocate to the nucleus initiating cytokine gene expression such as TNF- α and IL-6 found in this study [1,6]. Concomitantly, the double-edged action of ROS and/or oxidative stress may promote testicular mitochondrial stress leading to cytochrome C leakage into the cytosol. The leakage of cytochrome C is known to activate apoptotic caspase cascades which might have contributed to the elevated expression of caspase-3, caspase-9, and Bax, and decreased expression of Bcl2 in our study (Fig. 2), in consonance with earlier findings [6,7]. In contrast, the administration of ALA prevented the significant alterations in TNF- α , IL-6, Bax, caspase-3, caspase-9 in the testis. In response to this mitigation by ALA, the level of anti-inflammatory markers, IL-4 and IL-10 increased significantly. These results suggest anti-inflammatory and antiapoptotic effects of ALA [14,39]. Therefore, ALA has potential to inhibit inflammation and apoptosis in Pb-induced testicular toxicity. The mitigation of the apoptosis and pro-inflammation by the ALA supplementation in ALA + Pb group may be associated with its free radical scavenging and anti-inflammatory effects [13].

In conclusion, this study shows that ALA could block the accumulation of Pb in the testis. Our findings demonstrate that Pb is toxic to the testis via oxidative inflammation and apoptosis. However, we have shown that ALA could prevent Pb-induced testicular toxicity and endocrine aberrations via upregulation of antioxidant mechanism and downregulation of oxidative inflammation and apoptosis in rats' testis. The integrated network of the pathways initiated by Pb and the possible inhibition by ALA are succinctly represented in Fig. 4. Hence, ALA could be a potent natural agent to mitigate Pb testiculotoxicity.

Credit authorship contribution statement

AZ and AC: Conceptualization, Data curation, Formal analysis

HH and AC: Funding acquisition; Methodological/experimental design

AZ and HH: Project administration, Resources, Software, Supervision

AZ and AC: Writing of first/original draft

AC, HH, AZ: Reviewing the final manuscript & editing. All the authors read and approved the final manuscript.

Ethical approval

All experimental procedures were done according to the research ethics at King Faisal University with reference number: KFU-REC-2023-FEB-ETHICS540

Declaration of generative AI and AI-assisted technologies in the writing process

The authors declare no AI technologies in the preparation of this manuscript.

Funding

The Deanship of Scientific Research, Taif University, Saudi Arabia

Declaration of Competing Interest

The authors declare that they have no known competing financial interests or personal relationships that could have appeared to influence the work reported in this paper.

Acknowledgement

The researchers would like to acknowledge the Deanship of Scientific Research, Taif University for funding this work

References

- [1] G. Zhang, Y. Zhang, L. Jing, H. Zhao, Lead exposure induced developmental nephrotoxicity in Japanese quail (*Coturnix japonica*) via oxidative stress-based PI3K/AKT pathway inhibition and NF- κ B pathway activation, *Comp. Biochem. Physiol. C Toxicol. Pharmacol.* 268 (620) (2023), 109599, <https://doi.org/10.1016/j.cbpc.2023.109599>.
- [2] M.M. Ommati, H.N. Ahmadi, S. Sabouri, S. Retana-Marquez, N. Abdoli, S. Rashno, H. Niknahad, A. Jamshidzadeh, K. Mousavi, M. Rezaei, A. Akhlagh, N. Azarpira, F. Khodaei, R. Heidari, Glycine protects the male reproductive system against lead toxicity via alleviating oxidative stress, preventing sperm mitochondrial impairment, improving kinematics of sperm, and blunting the downregulation of enzymes involved in the steroidogenesis, *Environ. Toxicol.* 37 (12) (2022) 2990–3006, <https://doi.org/10.1002/tox.23654>.
- [3] L. Ouyang, Q. Li, S. Rao, R. Su, Y. Zhu, G. Du, J. Xie, F. Zhou, C. Feng, G. Fan, Cognitive outcomes caused by low-level lead, cadmium, and mercury mixture exposure at distinct phases of brain development, *Food Chem. Toxicol.* 175 (February) (2023), 113707, <https://doi.org/10.1016/j.fct.2023.113707>.
- [4] M.S. Deore, S. Keerthana, S. Naqvi, A. Kumar, S.J.S. Flora, Alpha-Lipoic Acid Protects Co-Exposure to Lead and Zinc Oxide Nanoparticles Induced Neuro, Immuno and Male Reproductive Toxicity in Rats, *Front. Pharmacol.* 12 (July) (2021) 1–20, <https://doi.org/10.3389/fphar.2021.626238>.
- [5] T.M. Saber, A.M.A. Abo-Elmaaty, E.N. Said, R.R. Beheiry, A.A.A. Moselhy, F.E. Abdelgawad, M.H. Arisha, T. Saber, A.H. Arisha, E.M. Fahmy, Alhagi maurorum Ethanolic Extract Rescues Hepato-Neurotoxicity and Neurobehavioral Alterations Induced by Lead in Rats via Abrogating Oxidative Stress and the Caspase-3-Dependent Apoptotic Pathway, *Antioxidants* 11 (10) (2022) 1–23, <https://doi.org/10.3390/antiox11101992>.
- [6] S. Kucukler, F. Benzer, S. Yildirim, C. Gur, F.M. Kandemir, A.S. Bengu, A. Ayna, C. Caglayan, M.B. Dortbudak, Protective Effects of Chrysin Against Oxidative Stress and Inflammation Induced by Lead Acetate in Rat Kidneys: a Biochemical and Histopathological Approach, *Biol. Trace Elem. Res.* 199 (4) (2021) 1501–1514, <https://doi.org/10.1007/s12011-020-02268-8>.
- [7] Mansour, L.A.H., Elshopekey, G.E., Abdelhamid, F.M., & Albukhari, T.A. (2023). *Hepatoprotective and Neuroprotective Effects of Naringenin against Lead-Induced Oxidative Stress, Inflammation, and Apoptosis in Rats*.
- [8] R. Levin, M.J. Brown, M.E. Kashtock, D.E. Jacobs, E.A. Whelan, J. Rodman, M.R. Schock, A. Padilla, T. Sinks, Lead exposures in U.S. children, 2008: implications for prevention, *Environ. Health Perspect.* 116 (10) (2008) 1285–1293, <https://doi.org/10.1289/ehp.11241>.
- [9] M.F. Alotaibi, F. Al-Joufi, H.S.A. Seif, M.A. Alzoghbi, L. Djouhri, A.F. Ahmeda, A.M. Mahmoud, Umbelliferone inhibits spermatogenic defects and testicular injury in lead-intoxicated rats by suppressing oxidative stress and inflammation, and improving Nrf2/HO-1 signaling, *Drug Design, Development and Therapy* 14 (2020) 4003–4019, <https://doi.org/10.2147/DDDT.S265636>.
- [10] D. Vukelić, A.B. Djordjević, M. Anđelković, E. Antonijević Miljković, K. Baralić, K. Živančević, P. Bulat, J. Radovanović, D. Đukić-Čosić, B. Antonijević, Z. Bulat, Subacute Exposure to Low Pb Doses Promotes Oxidative Stress in the Kidneys and Copper Disturbances in the Liver of Male Rats, *Toxics* 11 (3) (2023) 256, <https://doi.org/10.3390/toxics11030256>.
- [11] F. Mozaffarian, M.A. Delghani, A.R. Vanani, M. Mahdavinia, Protective Effects of Alpha Lipoic Acid Against Arsenic Induced Oxidative Stress in Isolated Rat Liver Mitochondria, *Biol. Trace Elem. Res.* 200 (3) (2022) 1190–1200, <https://doi.org/10.1007/S12011-021-02712-3>.
- [12] E. Bozhokina, S. Khatilina, I. Gamaley, Dihydrolyipoic but not alpha-lipoic acid affects susceptibility of eukaryotic cells to bacterial invasion, *Biochem. Biophys. Res. Commun.* 460 (3) (2015) 697–702, <https://doi.org/10.1016/j.bbrc.2015.03.092>.
- [13] F. Haghighatdoost, M. Hariri, The effect of alpha-lipoic acid on inflammatory mediators: a systematic review and meta-analysis on randomized clinical trials, *Eur. J. Pharmacol.* 849 (January) (2019) 115–123, <https://doi.org/10.1016/j.ejphar.2019.01.065>.
- [14] Y.S. Kim, M. Kim, M.Y. Choi, D.H. Lee, G.S. Roh, H.J. Kim, S.S. Kang, G.J. Cho, E.K. Hong, W.S. Choi, Alpha-lipoic acid reduces retinal cell death in diabetic mice, *Biochem. Biophys. Res. Commun.* 503 (3) (2018) 1307–1314, <https://doi.org/10.1016/j.bbrc.2018.07.041>.
- [15] S. Shila, V. Kokilavani, M. Subathra, C. Panneerselvam, Brain regional responses in antioxidant system to α -lipoic acid in arsenic intoxicated rat, *Toxicology* 210 (1) (2005) 25–36, <https://doi.org/10.1016/j.tox.2005.01.003>.
- [16] R.R.A. Hasan, A.I Al-Gareeb, The protective effect of alpha lipoic acid against methotrexate induced acute liver injury in mice, *Biochemical and Cellular Archives* 22 (2) (2022) 3885–3892, <https://doi.org/10.51470/bca.2022.22.2.3885>.
- [17] M.O. Balhaj, A.E. Ibrahim, A.E. Alsemeh, H.O. Mohammed, The Neurotoxic Effects of Methotrxate (MTX) on Rat Hippocampus and to Explore the Neuroprotective Role of Alpha Lipoic Acid (ALA): review Article, *Egypt. J. Hosp. Med.* 86 (1) (2022) 762–769, <https://doi.org/10.21608/EJHM.2022.216041>.
- [18] B. Abbasi, N. Molavi, M. Tavalae, H. Abbasi, M.H. Nasr-Esfahani, Alpha-lipoic acid improves sperm motility in infertile men after varicocele: a triple-blind randomized controlled trial, *Reprod. Biomed. Online* 41 (6) (2020) 1084–1091, <https://doi.org/10.1016/j.rbmo.2020.08.013>.

- [19] N. Naderi, Z.D. Nejad, M. Tavalae, M.H. Nasr-Esfahani, The effect of alpha-lipoic acid on sperm functions in rodent models for male infertility: a systematic review, *Life Sci.* 323 (November 2022) (2023), 121383, <https://doi.org/10.1016/j.lfs.2023.121383>.
- [20] R.H. Elbakary, S. Tawfik, R.M. Amer, Evaluation of the possible protective effect of alpha lipoic acid on testicular toxicity induced by polychlorinated biphenyl in adult albino rats: a histological study, *Journal of Microscopy and Ultrastructure* 8 (2) (2020) 42–50, https://doi.org/10.4103/JMAU.JMAU_34_19.
- [21] M. Shaban El-Neweshy, Y. Said El-Sayed, Influence of vitamin C supplementation on lead-induced histopathological alterations in male rats, *Exp. Toxicol. Pathol.* 63 (3) (2011) 221–227, <https://doi.org/10.1016/j.etp.2009.12.003>.
- [22] T. Wlostowski, E. Bonda, A. Krasowska, Photoperiod affects hepatic and renal cadmium accumulation, metallothionein induction, and cadmium toxicity in the wild bank vole (*Clethrionomys glareolus*), *Ecotoxicol. Environ. Saf.* 58 (1) (2004) 29–36, [https://doi.org/10.1016/S0147-6513\(03\)00109-X](https://doi.org/10.1016/S0147-6513(03)00109-X).
- [23] Elsayy, H., Famurewa, A.C., & Sedky, A. (2023). *Resveratrol Mitigates Diabetic Testicular Dysfunction, Endocrine Deficits, and Insulin Resistance via Suppression of Sperm- Endocrine Aberrations and Oxidative Inflammation in Rats.* 2023.
- [24] O.H. LOWRY, N.J. ROSEBROUGH, A.L. FARR, R.J. RANDALL, Protein measurement with the Folin phenol reagent, *J. Biol. Chem.* 193 (1) (1951) 265–275, [https://doi.org/10.1016/S0021-9258\(19\)52451-6](https://doi.org/10.1016/S0021-9258(19)52451-6).
- [25] J. Shao, B. Han, P. Cao, B. Zhang, M. Liu, D. Li, N. Zhou, Q. Hao, X. Duan, Y. Chang, A. Nakai, Y. Fan, K. Tan, HSF1 phosphorylation by cyclosporin A confers hyperthermia sensitivity through suppression of HSP expression, *Biochimica et Biophysica Acta. Gene Regulatory Mechanisms* 1862 (8) (2019) 846–857, <https://doi.org/10.1016/j.bbagr.2019.04.009>.
- [26] V. Toro-Román, M.C. Robles-Gil, D. Muñoz, I. Bartolomé, F.J. Grijo, M. Maynar-Mariño, Sex differences in cadmium and lead concentrations in different biological matrices in athletes. Relationship with iron status, *Environ. Toxicol. Pharmacol.* 99 (October 2022) (2023), <https://doi.org/10.1016/j.etap.2023.104107>.
- [27] M.S. Othman, S.T. Obaidat, G.M. Aleid, M.M. Abdel-Daim, O.A. Habotta, L. Schwartz, A.H. Al-Bagawi, M.M. Hussein, A. Bakkar, *Pergularia tomentosa* coupled with selenium nanoparticles salvaged lead acetate-induced redox imbalance, inflammation, apoptosis, and disruption of neurotransmission in rats' brain, *Open Chemistry* 20 (1) (2022) 1313–1326, <https://doi.org/10.1515/chem-2022-0246>.
- [28] C.R. Nwokocho, C.S. Ufearo, D.U. Owu, N.C. Idemudo, L.C. Ojukwu, In vivo distribution of lead in male and female rats after intraperitoneal and oral administration, *Toxicol. Ind. Health* 28 (2) (2012) 131–135, <https://doi.org/10.1177/0748233711407955>.
- [29] M.A. Basalamah, A.H. Abdelghany, M. El-Boshy, J. Ahmad, S. Idris, B. Refaat, Vitamin D alleviates lead induced renal and testicular injuries by immunomodulatory and antioxidant mechanisms in rats, *Sci. Rep.* 8 (1) (2018) 1–13, <https://doi.org/10.1038/s41598-018-23258-w>.
- [30] M. Shafiekhani, M.M. Ommati, N. Azarpira, R. Heidari, A.A. Salarian, Glycine supplementation mitigates lead-induced renal injury in mice, *J Exp Pharmacol* 11 (2019) 15–22, <https://doi.org/10.2147/JEP.S190846>.
- [31] S. Mehanna, M.Y. Issa, N.H. Hassan, A.M. Hussien, M.A. Ibrahim, E.I. Hassanen, *Origanum majorana* essential oil improves the rat's sexual behavior and testicular oxidative damage induced by imidacloprid via modulating the steroidogenesis pathways, *Saudi Pharmaceutical Journal* 30 (9) (2022) 1315–1326, <https://doi.org/10.1016/j.sjps.2022.06.016>.
- [32] X. Liu, J. Ye, L. Wang, Z. Li, Y. Zhang, J. Sun, C. Du, C. Wang, S. Xu, Protective Effects of PGC-1 α Against Lead-Induced Oxidative Stress and Energy Metabolism Dysfunction in Testis Sertoli Cells, *Biol. Trace Elem. Res.* 175 (2) (2017) 440–448, <https://doi.org/10.1007/s12011-016-0799-8>.
- [33] R. Santhosh Kumar, S. Asha Devi, Lead toxicity on male reproductive system and its mechanism: a review, *Research Journal of Pharmacy and Technology* 11 (3) (2018) 1228–1232, <https://doi.org/10.5958/0974-360X.2018.00228.7>.
- [34] Kamt, S.F., Liu, J., & Yan, L. (2023). *Renal-Protective Roles of Lipoic Acid in Kidney Disease.*
- [35] N.M. Al-Rasheed, N.M. Al-Rasheed, H.A. Attia, I.H. Hasan, M. Al-Amin, H. Al-Ajmi, R.A. Mohamad, Adverse cardiac responses to alpha-lipoic acid in a rat-diabetic model: possible mechanisms? *J. Physiol. Biochem.* 69 (4) (2013) 761–778, <https://doi.org/10.1007/s13105-013-0252-9>.
- [36] R.J. Aitken, S.D. Roman, Antioxidant systems and oxidative stress in the testes, *Oxid Med Cell Longev* 1 (1) (2008) 15–24, <https://doi.org/10.4161/oxim.1.1.6843>.
- [37] B.N. Al-Okaily, H.F. Murad, Role of alpha lipoic acid in protecting testes of adult rats from lead toxicity, *Iraqi Journal of Veterinary Sciences* 35 (2) (2021) 305–312, <https://doi.org/10.33899/ijvs.2020.126814.1386>.
- [38] A. Rostami, S. Vakili, F. Koohpeyma, B.N. Jahromi, Z.A. Aghajari, Ellagic acid effects on testis, sex hormones, oxidative stress, and apoptosis in the relative sterility rat model following busulfan administration, *BMC Complementary Medicine and Therapies* (2022) 1–14, <https://doi.org/10.1186/s12906-022-03650-w>.
- [39] E. Erdem Guzel, N. Kaya Tektemur, A. Tektemur, Alpha-lipoic acid may ameliorate testicular damage by targeting dox-induced altered antioxidant parameters, mitofusin-2 and apoptotic gene expression, *Andrologia* 53 (3) (2021) 1–11, <https://doi.org/10.1111/and.13990>.
- [40] C. Prahalathan, E. Selvakumar, P. Varalakshmi, Modulatory role of lipoic acid on adriamycin-induced testicular injury, *Chem. Biol. Interact.* 160 (2) (2006) 108–114, <https://doi.org/10.1016/j.cbi.2005.12.007>.
- [41] A. Arafah, M.U. Rehman, A. Ahmad, K.M. Alkharfy, S. Alqahtani, B.L. Jan, N.M. Almatroudi, Myricetin (3,3',4',5,5',7-Hexahydroxyflavone) Prevents 5-Fluorouracil-Induced Cardiotoxicity, *ACS Omega* 7 (5) (2022) 4514–4524, <https://doi.org/10.1021/acsomega.1c06475>.